This is a digital copy of a book that was preserved for generations on library shelves before it was carefully scanned by Google as part of a project to make the world's books discoverable online.

It has survived long enough for the copyright to expire and the book to enter the public domain. A public domain book is one that was never subject to copyright or whose legal copyright term has expired. Whether a book is in the public domain may vary country to country. Public domain books are our gateways to the past, representing a wealth of history, culture and knowledge that's often difficult to discover.

Marks, notations and other marginalia present in the original volume will appear in this file - a reminder of this book's long journey from the publisher to a library and finally to you.

Usage guidelines

Google is proud to partner with libraries to digitize public domain materials and make them widely accessible. Public domain books belong to the public and we are merely their custodians. Nevertheless, this work is expensive, so in order to keep providing this resource, we have taken steps to prevent abuse by commercial parties, including placing technical restrictions on automated querying.

We also ask that you:

+ *Make non-commercial use of the files* We designed Google Book Search for use by individuals, and we request that you use these files for personal, non-commercial purposes.
+ *Refrain from automated querying* Do not send automated queries of any sort to Google's system: If you are conducting research on machine translation, optical character recognition or other areas where access to a large amount of text is helpful, please contact us. We encourage the use of public domain materials for these purposes and may be able to help.
+ *Maintain attribution* The Google "watermark" you see on each file is essential for informing people about this project and helping them find additional materials through Google Book Search. Please do not remove it.
+ *Keep it legal* Whatever your use, remember that you are responsible for ensuring that what you are doing is legal. Do not assume that just because we believe a book is in the public domain for users in the United States, that the work is also in the public domain for users in other countries. Whether a book is still in copyright varies from country to country, and we can't offer guidance on whether any specific use of any specific book is allowed. Please do not assume that a book's appearance in Google Book Search means it can be used in any manner anywhere in the world. Copyright infringement liability can be quite severe.

About Google Book Search

Google's mission is to organize the world's information and to make it universally accessible and useful. Google Book Search helps readers discover the world's books while helping authors and publishers reach new audiences. You can search through the full text of this book on the web at `http://books.google.com/`

BOSTON
MEDICAL LIBRARY
8 THE FENWAY

TRANSACTIONS

OF THE

PATHOLOGICAL SOCIETY OF LONDON.

VOLUME TENTH.

INCLUDING THE REPORT OF THE PROCEEDINGS FOR THE SESSION 1858-9.

LONDON:
PRINTED FOR THE SOCIETY BY J. W. ROCHE, 5, KIRBY STREET.
1859.

THE present publication being the Tenth Volume of Transactions, constitutes the Thirteenth published Annual Report of the Pathological Society's proceedings.

The COUNCIL think it right to repeat, that the exhibitors are alone responsible for the descriptions given of the Specimens exhibited by them, the only change made in the Reports furnished by the authors being such verbal alterations as were absolutely necessary.

53, BERNERS STREET, OXFORD STREET,
September, 1859.

TABLE OF CONTENTS

OF VOLUME X.

List of Presidents and of Officers and Members during the Session 1858-9 I

List of Specimens Exhibited during the Session 1858-9. XVIII

Index to Plates XLIV

Index to Woodcuts XLV

Diseases, etc. of the Nervous System 1

Diseases, etc. of the Organs of Respiration . . 60

Diseases, etc. of the Organs of Circulation . . 71

Diseases, etc. of the Organs of Digestion . . . 128

Diseases, etc. of the Genito-Urinary Organs . . 187

Diseases, etc. of the Osseous System 211

Diseases, etc. of the Organs of Special Sense . . 236

Tumours, Cysts, Hydatids, etc. 237

Diseases, etc. of the Ductless Glands 259

Miscellaneous Specimens, including Malformation, Diphtheria, Teeth, Skin, etc. 279

Specimens from the Lower Animals 334

Index 349

Former Presidents.

ELECTED	
1846	CHARLES J. B. WILLIAMS, M.D., F.R.S.
1848	CHARLES ASTON KEY, Esq.
1850	PETER MERE LATHAM, M.D.
1852	CÆSAR H. HAWKINS, Esq., F.R.S.
1853	BENJAMIN GUY BABINGTON, M.D., F.R.S.
1855	JAMES MONCRIEFF ARNOTT, Esq., F.R.S.
1857	THOMAS WATSON, M.D.

OFFICERS AND COUNCIL

OF THE

Pathological Society of London,

ELECTED AT

THE GENERAL MEETING, JANUARY 4, 1859.

President.

WILLIAM FERGUSSON, Esq., F.R.S.

Vice-Presidents.

THOMAS WATSON, M.D., F.R.S.
WILLIAM JOHN LITTLE, M.D.
JAMES RISDON BENNETT, M.D.
C. J. B. WILLIAMS, M.D., F.R.S.
JAMES MONCRIEFF ARNOTT, Esq., F.R.S.
JOHN SIMON, Esq., F.R.S.
GEORGE BUSK, Esq., F.R.S.
ALEXANDER SHAW, Esq.

Treasurer.

RICHARD QUAIN, M.D.

Council.

WILLIAM CAMPS, M.D.
THEOPHILUS THOMPSON, M.D., F.R.S.
SAMUEL WILKS, M.D.
THOMAS BEVILL PEACOCK, M.D.
A. WHYTE BARCLAY, M.D.
LIONEL S. BEALE, M.D., F.R.S.
WILLIAM O. MARKHAM, M.D.
CHARLES MURCHISON, M.D.
R. HUNTER SEMPLE, M.D.
JOSEPH HULLETT BROWNE, M.D.
EDWARD C. SEATON, M.D.
JONATHAN HUTCHINSON, Esq.
JOHN WOOD, Esq.
THOMAS BLIZARD CURLING, Esq., F.R.S.
GEORGE CRITCHETT, Esq.
JOHN JAMES PURNELL, Esq.
J. CHARLES LANGMORE, Esq.
THOMAS TATUM, Esq.
THOMAS BALLARD, Esq.
MITCHELL HENRY, Esq.

Honorary Secretaries.

JOHN W. OGLE, M.D.
HENRY THOMPSON, Esq.

**** *Members are requested to indicate to the Secretaries corrections when necessary.*

LIST OF MEMBERS OF THE SOCIETY.

Honorary Members.

ALISON, WILLIAM PULTENEY, D.C.L., M.D., F.R.S. Professor of Medicine in the University of Edinburgh.

ANDRAL, G., M.D., Professor in the Faculty of Medicine, Paris.

*BENTLEY, EDWARD, M.D., (formerly Honorary Secretary), Physician to the City of London Hospital for Diseases of the Chest, Hackney.

CRUVEILHIER, J. C., M.D., Professor in the Faculty of Medicine, Paris.

HENLE, J., Professor of Anatomy and Physiology in the University of Zurich.

ROKITANSKY, CARL, M.D., Professor of Pathological Anatomy in the University of Vienna.

STOKES, WILLIAM, M.D., M.R.I.A., Regius Professor of Physic in the University of Dublin.

VOGEL, JULIUS, M.D., Professor of Clinical Medicine in the University of Giessen.

Resident and Non-Resident Members.

(C.) Present Members of Council.
† Have paid Life Subscriptions.
* Former Members of Council.
‡ Have paid Composition Fee for Transactions.

GENERAL LIST OF MEMBERS.

Elected Session

1858-59 Acland, Henry Wentworth, M.D., F.R.S., Physician to the Radcliffe Infirmary, Oxford.

**Orig. Memb.* Adams, William, Esq., Surgeon to the Royal Orthopædic Hospital, 5, Henrietta-street, Cavendish-square.

1858-59 Adams, William, Esq., 37, Harrington-square.

1847-58 Aikin, Charles A., Esq., 8, Southwick-street, Hyde-park.

1857-58 Alison, S. Scott, M.D., Assistant Physician to the Hospital for Consumption, Brompton, 80, Park-street, Grosvenor-square.

1857-58 Anstie, Francis E., M.B., Curator of the Museum at the Westminster Hospital, 15, Onslow-square, S.W.

1854-55 Armitage, Thomas Rhodes, M.D., Physician to St. Marylebone General Dispensary, 21, Edwards-street, Portman-square.

Elected Session

Orig. Memb. Arnott, James Moncrieff, Esq., F.R.S., (late President V.P.), 2, New Burlington-street.

1851-52 Ashton, T. J., Esq., Surgeon to the Blenheim-street Dispensary, 31, Cavendish-square.

1857-58 Avent, Nicholas, Esq., House Surgeon to the St. George's and St. James's Dispensary, 15, Lambeth-terrace.

Orig. Memb. Babington, Benjamin Guy, M.D., F.R.S. (late President) (V.P.), 31, George-street, Hanover-square.

1854-55 Babington, C. Metcalfe Stuart, F.R.C.P., Physician-Accoucheur to Queen Charlotte's Lying-in-Hospital, 29, Hertford-street, Mayfair.

1856-57 Balding, Daniel Barley, Esq., Resident Medical Officer and Registrar, Middlesex Hospital.

1849-50 Ballard, Thomas, Esq. (C.), 10, Southwick-place, Hyde-park.

*1850-51 Baly, William, M.D., F.R.S., Assistant Physician to St. Bartholomew's Hospital, 45, Queen Anne-street, Cavendish-square.

1851-52 Barclay, A. Whyte, M.D. (C.), Assistant Physician to St. George's Hospital, 23A, Bruton-street, Berkeley-square.

1855-56 Barker, T.A., M.D., Senior Physician to St. Thomas's Hospital, 71, Lower Grosvenor-street.

Orig. Memb. Barker, Thomas Herbert, M.D., Harpur-place, Bedford.

**Orig. Memb.* Barlow, George Hilaro, M.D., Physician to Guy's Hospital, 5, Union-street, Southwark.

1852-53 Bartlett, William, Esq., Surgeon to the Kensington Dispensary, Ladbroke Lodge, Ladbroke-square, Notting Hill.

1852-53 Barwell, Richard, Esq., Assistant Surgeon to the Charing Cross Hospital, 22, Old Burlington-street.

1857-58 Basham, William R., M.D., Senior Physician to the Westminster Hospital, 17, Chester-street, Grosvenor-place.

1851-52 Beale, Lionel S., M.D., F.R.S. (C.), Physician to King's College Hospital, 61, Grosvenor-street.

1855-56 Bealey, Adam, M.D., M.A., 27, Tavistock-square.

1852-53 Beck, Thomas Snow, M.D., F.R.S., 9A, Langham-place.

*1849-50 Beith, Robert, M.D., Surgeon, Royal Naval Hospital, Deal.

1846-47 Bennet, James Henry, M.D., Physician-Accoucheur to the Royal Free Hospital, 60, Grosvenor-street.

**Orig. Memb.* Bennett, James Risdon, M.D. (V.P.), Physician to St. Thomas's Hospital, and to the City of London Hospital for Diseases of the Chest, 15, Finsbury-square.

‡1856-57 Bickersteth, Edward R., Esq., Surgeon to the Liverpool Royal Infirmary, 2, Rodney-street, Liverpool.

*1848-49 Bird, James, M.D., Lecturer on Military Surgery at St. Mary's Hospital, 27, Hyde-park-square.

Elected Session

1855-56 Bird, W., Esq., Surgeon to the West of London Hospital and the St. George's and St James's Dispensary, 11, George Street, Hanover-square.

*1849-50 Birkett, Edmund Lloyd, M.D., Physician to the City of London Hospital for Diseases of the Chest, 48, Russell-square.

**Orig. Memb.* Birkett, John, Esq., Surgeon to Guy's Hospital, 59, Green-street, Grosvenor-square.

1853-54 Black, Cornelius, M.D., Physician to the Chesterfield Dispensary, St. Mary's-gate, Chesterfield.

1849-50 Blagden, Robert, Esq., Stroud, Gloucestershire.

1855-56 Borham, W. H., Esq., 19, Cambridge-terrace, Hyde-park.

*1850-51 Bowman, William, Esq., F.R.S., Surgeon to King's College and to the Royal Ophthalmic Hospital, 5, Clifford-street.

*1846-47 Brinton, William, M.D., Senior Physician to the Royal Free Hospital, 20, Brook-street, Grosvenor-square.

1856-57 Briscoe, John, Esq., House Surgeon and Apothecary, Radcliffe Infirmary, Oxford.

*†1850-51 Bristowe, John S., M.D., Assistant Physician to St. Thomas's Hospital, 3, St. Thomas's-street, Borough.

1851-52 Brodhurst, Bernard E., Esq., Assistant Surgeon to the Royal Orthopædic Hospital, 20, Grosvenor-street.

*1846-47 Brooke, Charles, M.B., F.R.S., Surgeon to the Westminster Hospital, 29, Keppel-street, Russell-square.

Orig. Memb. Browne, Joseph Hullett, M.D. (C.), Physician to the St. Pancras Royal General Dispensary, 37, Euston-square.

1854-55 Browne, Robert Cave, M.D., Courtney-lodge, Barnet, Herts.

1855-56 Bryant, T., Esq., Assistant Surgeon to Guy's Hospital, 40, Wellington-street, London-bridge.

1854-55 Buchanan, George, M.D., 75, Gower-street, Bedford-square.

1858-59 Buckland, Francis, Esq., Surgeon to the 2nd Regiment of Life Guards, Windsor.

1858-59 Budd, George, M.D., F.R.S., Physician to King's College Hospital, 20, Dover-street, Piccadilly.

1850-51 Bullock, Henry, Esq., 61, Cumberland-street, Bryanston-square.

1852-53 Burton, John M., Esq., Lee-park, Blackheath.

**Orig. Memb.* Busk, George, Esq., F.R.S. (V.P.), Surgeon to the Seamen's Hospital-ship "Dreadnought," 15, Harley-street, Cavendish-square.

*1856-57 Buzzard, Thomas, M.B., 41, Great Marlborough-street.

1856-57 Callender, G. W., Esq., Surgeon to the North London Eye Infirmary, 35, Queen Anne-street, Cavendish-square.

Orig. Memb. Camps, William, M.D. (C.), 40, Park-street, Grosvenor-square.

*1849-50 Canton, Edwin, Esq., Surgeon to the Charing Cross Hospital, 30, Montague-place, Russell-square.

Elected Session

1854-55 Carpenter, Alfred, Esq., M.B., High-street, Croydon.

1848-49 Carpenter, William Guest, Esq., Amersham, Bucks.

1855-56 Carter, H. V., M.D., Bombay; late of St. George's Hospital.

*1848-49 Chalk, William Oliver, Esq., 3, Nottingham-terrace, Regent's park.

**Orig. Memb.* Chevers, Norman, M.D., India.

1858-59 Child, Gilbert W., M.B., Physician to the Radcliffe Infirmary, Beaumont-street, Oxford.

1851-52 Childs, George Borlase, Esq., Surgeon to the Metropolitan Free Hospital, and to the City Police Force, 11, Finsbury-place South.

1854-55 Cholmeley, William, M.D., Physician to the West London Dispensary, 40, Russell-square.

1851-52 Chowne, William, D., M.D., Physician to the Charing Cross Hospital, 8, Connaught-place West, Hyde-park.

1853-54 Clark, Andrew, M.D., Assistant Physician to the London Hospital, 23, Montague-place, Russell-square.

1855-56 Clarke, James F., Esq., Senior Surgeon to the Dorcas Charity, 23, Gerrard-street, Soho.

1849-50 Clarke, John, Esq., L.R.C.P., Physician-Accoucheur to the British Lying-in-Hospital, 42, Hertford-street, May-fair.

1854-55 Clover, J. Thomas, Esq., 3, Cavendish-place.

**Orig. Memb.* Cock, Edward, Esq., Surgeon to Guy's Hospital, 13, St. Thomas's-street, Borough.

1857-58 Cockerton, Richard, Esq., Surgeon to the Kensington Dispensary, 15, Clarendon-road, Kensington.

1855-56 Cockle, J., M.D., M.A., Physician to the City Dispensary, 63, Brook-Street, Hanover-square.

Orig. Memb. Cohen, Daniel Whitaker, M.D., Headley-grove House, near Dorking.

1858-59 Cooke, Robert Thomas, Esq., Surgeon to the Scarborough Dispensary, 15, St. Nicholas Cliff, Scarborough, Yorkshire.

1849-50 Cooper, George F., M.D., Surgeon to the Brentford Dispensary, Brentford.

1850-51 Cooper, William White, Esq., Ophthalmic Surgeon to St. Mary's Hospital, and Surgeon to the North London Eye Infirmary, 19, Berkeley-square.

1858-59 Coote, Charles T., M.D., Assistant Physician and Lecturer on Medical Jurisprudence at the Middlesex Hospital, 1, Gloucester-place, Hyde-park.

**Orig. Memb.* Copland, James, M.D., F.R.S. (late V.P., and Treasurer), Consulting Physician at the Royal Infirmary for Children, 5, Old Burlington-street.

1853-54 Cornish, William Robert, Esq.

1858-59 Coulson, Walter J., Esq., Curator of the Museum at St. Mary's Hospital.

Elected Session

*Orig. Memb. Coulson, William, Esq., Senior Surgeon to St. Mary's Hospital, 1, Chester-terrace, Regent's-park.

1852-53 Cousins, Edward, Esq., 49, Camden-road-villas.

*Orig. Memb. Crisp, Edwards, M.D., 278, King's-road, Chelsea.

*1848-49 Critchett, George, Esq. (C.), (formerly Honorary Secretary), Senior Assistant Surgeon to the London Hospital, and Surgeon to the Royal London Ophthalmic Hospital, Moorfields, 46, Finsbury-square.

1855-56 Croft, John, Esq., Seamen's Hospital-ship, "Dreadnought."

1853-54 Cross, Robert, M.D., Physician to the Brewer's-court Dispensary, 20, New-street, Spring-gardens.

1857-58 Cumberbatch, Laurence T., Esq., 12, Cadogan-place, Belgrave-square.

1854-55 Curgenven, J. Brendon, Esq., 11, Craven-hill-gardens, Bayswater.

1854-55 Curling, T. Blizard, Esq., F.R.S. (C.), Surgeon to the London Hospital, 39, Grosvenor-street.

1854-55 Danbeny, Henry, M.D., 40, York-place, Portman-square.

*1846-47 Davis, John Hall, M.D., Physician to the Royal Maternity Charity, and to the St. George's and St. James's Dispensary, 11, Harley-street, Cavendish-square.

*Orig. Memb. Davies, Herbert, M.D., Physician to the Infirmary for Asthma, &c., and to the London Hospital, 23, Finsbury-square.

*Orig. Memb. Day, George E., M.D., Chandos Professor of Anatomy in the University of St. Andrews.

1857-58 Delima, Teofilo, M.D., Caracas, South America.

1851-52 Devenish, Samuel Weston, M.B., 7, Billiter-square.

1855-56 Dick, H., M.D., 59, Wimpole-street.

1858-59 Dickinson, W. H., L.R.C.P., Charles-street, Berkeley-square.

*Orig. Memb. Dixon, James, Esq., Surgeon to the Royal London Ophthalmic Hospital, Moorfields, 2, Portman-square.

1855-56 Druitt, R., L.R.C.P., Medical-Officer of Health for St. George's, Hanover-square, 37, Hertford-street, May-fair.

1851-52 Drury, James Samuel, M.D., 13, Radnor-place.

1846-47 Dudgeon, Robert E., M.D., 82, Gloucester-place, Portman-square.

1851-52 Duff, George, M.D., High-street, Elgin.

1858-59 Durham, Arthur Edward, Esq., Demonstrator of Anatomy at Guy's Hospital.

1848-49 Eden, Thomas E., Esq., Surgeon-Dentist to the Farringdon General Dispensary, 45, Threadneedle-street.

1854-55 Edwards, George N., M.D., Assistant Physician to the City of London Hospital for Diseases of the Chest, 1, Finsbury-square.

1846-47 Ellis, Joseph, Esq., Sudbrook-park, Richmond, Surrey.

Elected Session

*1846-47 Erichsen, John, Esq., Surgeon to University College Hospital, 48, Welbeck-street, Cavendish-square.

1853-54 Evans, Conway, M.D., Assistant Physician to King's College Hospital, and Physician to the Public Dispensary, Lincoln's-inn, 30, Brook-street, Grosvenor-square.

1858-59 Ewens, John, Esq., Milton-Abbas, Blandford, Dorset.

*1847-48 Fergusson, William, Esq., F.R.S. (President), Surgeon to King's College Hospital, 16, George-street, Hanover-square.

1851-52 Field, Octavius A., Esq., 20, Sussex-gardens, Hyde-park.

*1846-47 Fincham, George T., M.D., Physician to the Westminster Hospital, 2, Eccleston-terrace South, Eccleston-square, S. W.

1853-54 Fisher, W. Webster, M.D., Downing Professor of Medicine, Cambridge.

1855-56 Flower, William H., Esq., Surgeon to the Marylebone General Dispensary, and Assistant Surgeon to the Middlesex Hospital, 15, Queen Anne-street, Cavendish-square.

1851-52 Forbes, J. Gregory, Esq., Surgeon to the Metropolitan Convalescent Institution, 9, Devonport-street, Hyde-park.

1849-50 Foreman, Robert Clifton, M.D., Resident Physician to the Asylum for Imbecile Children, Colville-house, Lowestoft.

†*Orig. Memb.* Forster, John Cooper, Esq., Assistant Surgeon to Guy's Hospital, Surgeon to the Royal Infirmary for Children, 11, Wellington-street, Southwark.

1858-59 Francis, Charles Richard, M.B., Bengal Medical Establishment, Indian Army.

1853-54 Freeman, William Henry, Esq., 21, Spring-gardens.

Orig. Mem. Frere, J. C., Esq., Trinity College, Cambridge.

*1846-47 Fuller, Henry W., M.D., Physician to St. George's Hospital, 13, Manchester-square.

1858-59 Gairdner, William Tennant, M.D., Physician to the Royal Infirmary, 52, Northumberland-street, Edinburgh.

1855-56 Gamgee, Joseph Sampson, Esq., Queen's Hospital, Birmingham.

1855-56 Gamgee, J., Esq., New Veterinary College, Edinburgh.

1850-51 Garrett, Mark Brown, Esq., 3, New-Road, St. George's East.

*1846-47 Garrod, Alfred Baring, M.D., F.R.S., Physician to University College Hospital, 84, Harley-street, Cavendish-square.

1858-59 Gascoyen, George Green, Esq., 25, Oxford-terrace, Hyde-park.

1856-56 Gaskoin, George, Esq., 3, Westbourne-park, Paddington.

**Orig. Memb.* Gay, John, Esq., Senior Surgeon to the Great Northern Hospital, King's Cross, 10, Finsbury-place South.

1855-56 Gerber, Philip, M.D., 40, Mortimer-street, Cavendish-square.

Elected Session

1854-55 Gibb, George Duncan, M.D., F.G.S., Physician to the West London Dispensary, 22, Portman-street, Portman-square.

1853-54 Gibbon, Septimus, M.D., Assistant Physician to the London Hospital, 11, Finsbury-place.

1857-58 Godfrey, Benjamin, M.D., Carlton-house, Enfield.

1854-55 Goodfellow, Stephen Jennings, M.D., Physician to the Middlesex Hospital, 5, Savile-row, Burlington-gardens.

1856-57 Goolden, R. H., M.D., Physician to St. Thomas's Hospital, 41, Sussex-gardens, Hyde-park.

1857-58 Gowlland, Peter Y., Esq., Demonstrator of Anatomy at the London Hospital, 34, Finsbury-square.

*1848-1849 Gray, Henry, Esq., F.R.S., Surgeon to St. George's and St. James's Dispensary, 8, Wilton-street, Grosvenor-place.

1846-47 Gream, George T., M.D., 2, Upper-Brook-st., Grosvenor-square.

1856-57 Greenhalgh, Robert, M.D., Consulting Physician-Accoucheur to St. John's Wood Dispensary, 11, Upper Woburn-place.

‡1854-55 Greenhill, William Alexander, M.D., Physician to the Hastings Infirmary, Carlisle-parade, Hastings.

1858-59 Gunn, Theophilus Miller, Esq., 5, Langham-street, Portland-place.

*1849-50 Habershon, Samuel O., M.D., Assistant Physician to Guy's Hospital, 22, Wimpole-street, Cavendish-square.

1851-52 Hacon, E. Dennis, Esq., Mare-street, Hackney.

†1851-52 Halley, Alexander, M.D., 7, Harley-street, Cavendish-square.

1856-57 Hancock, Henry, Esq., Surgeon to the Charing-cross Hospital, 37, Harley-street, Cavendish-square.

1851-52 Hansard, Richard James, Esq., Surgeon to the Radcliffe Infirmary, 5, Broad-street, Oxford.

*1847-48 Hare, Charles John, M.D., Assistant Physician to University College Hospital, 41, Brook-street, Grosvenor-square.

†1855-56 Harley, George, M.D., Professor of Medical Jurisprudence in University College, London, 77, Harley-street.

1857-58 Hart, Ernest, Esq., Junior Surgeon to the North London Ophthalmic Infirmary, 69, Wimpole-street.

**Orig. Memb.* Hawkins, Cæsar H., Esq., F.R.S. (late President), Senior Surgeon to St. George's Hospital, 26, Grosvenor-street.

1851-52 Hawkins, Charles, Esq., Consulting Surgeon to Queen Charlotte's Hospital, and Inspector of Anatomy, 22, Savile-row.

1856-57 Hawksley, Thos., M.D., Physician to the Margaret-street Dispensary for Consumption, 26, George-street, Hanover-square.

1856-57 Heath, Christopher, Esq., Demonstrator of Anatomy at the Westminster Hospital, 31, Sackville-street, Piccadilly.

1857-58 Hedger, Alfred, M.D., Resident Medical Officer, Colney-hatch Asylum.

Elected Session

1858-59 Henderson, Andrew, Esq., 14, Upper Seymour-street.

*1848-49 Henry, Mitchell, Esq. (C., late Hon. Secretary), Surgeon to the Middlesex Hospital, and to the North London Eye Infirmary, 5, Harley-street, Cavendish-square.

**Orig. Memb.* Hewett, Prescott G., Esq., Assistant Surgeon to St. George's Hospital, 1, Chesterfield-street, May-fair.

1854-55 Hewitt, Graily, M.D., Physician to the British Lying-in-Hospital, and Lecturer on Comparative Anatomy and Zoology, at St. Mary's Hospital, 17, Radnor-place, Hyde-park.

1854-55 Hillier, Thomas, M.D., Medical Officer of Health for St. Pancras, 21, Upper Gower-street, Bedford-square.

Orig. Memb. Hillman, William Augustus, Esq., Senior Assistant Surgeon to the Westminster Hospital, 1, Argyll-street, Regent-street.

**Orig. Memb.* Hilton, John, Esq., F.R.S., Surgeon to Guy's Hospital, 10, New Broad-street, City.

1855-56 Hinton, J., Esq., 37, Charterhouse-square.

*1850-51 Hodgson, Joseph, Esq., F.R.S., 60, Westbourne-terrace.

1852-53 Hogg, Jabez, Esq., Assistant Surgeon to the Westminster Ophthalmic Hospital, 6, Gower-street.

1846-47 Holman, H. Martin, M.D., Hurstpierpoint, Sussex.

1854-55 Holmes, Timothy, Esq., Curator of the Pathological Museum of St. George's Hospital, and Surgeon to the North London Eye Infirmary, 22, Queen-street, May-fair.

*1849-50 Holt, Barnard Wight, Esq., Senior Surgeon to the Westminster Hospital, 5, Parliament-street.

1853-54 Hood, William Charles, M.D., Resident Physician, Bethlem Hospital.

1858-59 Hooper, W., Esq., Resident Assistant Obstetric Medical Officer at St. George's Hospital.

1850-51 Hore, Henry, A., Esq., Surgeon to the Bristol Royal Infirmary.

1857-58 Hornnidge, Thomas King, Esq., 15, Charles-street, Westbourne-terrace.

1855-56 Hudson, John, M.D., 11, Cork-street.

1854-55 Hulke, John Whitaker, Esq., Assistant Surgeon to King's College Hospital, 10, Old Burlington-street.

1854-55 Hulme, Edward Charles, Esq., Assistant Surgeon to the Central London Ophthalmic Hospital, and Surgeon to the Blenheim-street Dispensary, 19, Gower-street, Bedford-square.

1852-53 Humby, Edwin, Esq., 1, Windsor-terrace, Maida-hill.

1852-53 Hutchinson, Jonathan, Esq. (C.), Surgeon to the Metropolitan Free Hospital, 14, Finsbury Circus.

‡1856-57 Jackson, Henry, Esq., Senior Surgeon to the Sheffield Infirmary, St. James's-row, Sheffield.

‡1853-54 Jardine, J. L., Esq., Brixton-hill, Surrey.

1846-47 Jay, Edward, Esq., 51, Park-street, Grosvenor-square.

Elected Session

Orig. Memb. Jeaffreson, Henry, M.D., Physician to St. Bartholomew's Hospital, and Consulting Physician to the City of London Hospital for Diseases of the Chest, 2, Finsbury-square.

Orig. Memb. Jenner, William, M.D., Physician to the Hospital for Sick Children, and to University College Hospital, 8, Harley-street.

1854-55 Johnson, Athol A. W., Esq., Surgeon to the Hospital for Sick Children, 37, Albemarle-street.

1854-55 Johnson, Edward, M.D., 211A, Regent-street.

Orig. Memb. Johnson, George, M.D., Physician to King's College Hospital, 11, Savile-row.

*1846-47 Johnson, Henry Charles, Esq., Surgeon to St. George's Hospital, 6, Savile-row.

1856-57 Johnstone, Joseph S., M.D., 59, Inverness-terrace, Bayswater.

*†*Orig. Memb.* Jones, Henry Bence, M.D., F.R.S., Physician to St. George's Hospital, 31, Brook-street, Grosvenor-square.

1853-54 Jones, Sydney, M.B., Demonstrator of Morbid Anatomy at St. Thomas's Hospital, 4, St. Thomas's-street.

1858-59 Jones, William Price, M.D., Surbiton, Kingston.

1856-57 Jones, George Matthew, Esq., Surgeon to the General Hospital, Old-street, St. Heliers, Jersey.

1846-47 Kent, Thomas J., Esq., 16, Regent-street.

1852-53 Kershaw, W. Wayland, M.D., Kingston-on-Thames.

1851-52 Kingdon, J. Abernethy, Esq., Surgeon to the City Dispensary, and to the City Truss Society, 2, New Bank-buildings.

1856-57 Kingsley, Henry, M.D., Physician to the Stratford Infirmary, Stratford-on-Avon.

1854-55 Kirby, Edmund A., M.D., 1, Taviton-street, Gordon-square.

1854-55 Kirkes, William Senhouse, M.D., Assistant Physician to St. Bartholomew's Hospital, 2, Lower Seymour-street.

1850-51 Langmore, John C., M.B. (C.), 20, Oxford-terrace, Hyde-park.

1857-58 Lankester, Edwin, M.D., F.R.S., Medical Officer of Health for St. James's, Westminster, 8, Savile-row.

*1849-50 Latham, Peter Mere, M.D. (late President), late Physician to St. Bartholomew's Hospital, 36, Grosvenor-street.

1856-57 Laurence, John Z., Esq., Surgeon to the Northern Dispensary, 30, Devonshire-street, Portland-place.

1853-54 Lawrence, Henry John Hughes, Esq., Assistant Surgeon, Grenadier Guards.

1858-59 Lawson, George, Esq., Surgeon to the Great Northern Hospital, 63, Park-street, Grosvenor-square.

1857-58 Leared, Arthur, M.B., Physician to the Royal Infirmary for Diseases of the Chest, 48, Finsbury-square.

Elected Session

1851-52 Lee, Henry, Esq., Surgeon to King's College Hospital, and Senior Surgeon to the Lock Hospital, 9, Savile-row.

1852-53 Leggatt, Alfred, Esq., 13, William-street, Lowndes-square.

*1849-50 Liddell, Sir John, C.B., M.D., F.R.S., Director-General of the Medical Department of the Navy, Somerset House.

*1848-49 Little, William John, M.D. (V.P.), Physician to the London Hospital, 34, Brook-street, Grosvenor-square.

**Orig. Memb.* Lloyd, Edward, M.D., Physician to the Royal General Dispensary, 4, Suffolk-place, Pall-mall.

1852-53 Lloyd, Eusebius A., Esq., Surgeon to St. Bartholomew's and Christ's Hospitals, 14, Bedford-row.

1855-56 Macann, Arthur B., Esq., 22, King-street, Portman-square.

1858-59 Mackay, Allan Douglas, M.B., Hertford.

1857-58 Marcet, William, M.D., Assistant Physician to the Westminster Hospital, 36, Chapel-street, Belgrave-square.

1851-52 Markham, William O., M.D. (C.), Physician to St. Mary's Hospital, 33, Clarges-street, Piccadilly.

1846-47 Marshall, John, Esq., F.R.S., Assistant Surgeon to University College Hospital, 10, Savile-row.

1856-57 Martin, Robert, M.D., Assistant Physician to St. Bartholomew's Hospital, Warden's Residence, St. Bartholomew's Hospital.

1852-53 Martyn, S., M.D., Senior Physician to the Bristol General Hospital, 26, Park-street, Bristol.

1858-59 Martyn, William, Esq., 14, Brompton Row, Brompton.

1858-59 Masters, Maxwell T., Esq., 2, Rye-crescent, Peckham-rye.

1858-59 Maunder, C. F., Esq., Demonstrator of Anatomy at Guy's Hospital.

‡1851-52 May, George, M.B., Surgeon to the Royal Berkshire Hospital, Reading.

1858-59 Meadows, Alfred, M.D., Physician-Accoucheur to the St. George's and St. James's Dispensary, 41, Mortimer-street, Cavendish-square.

1857-58 Meller, Charles James, Esq., 31, Aberdeen-place, Maida-hill.

1854-55 Miles, Charles, Esq., 13, Conduit-street West, Hyde-park.

1858-59 Montefiore, Nathaniel, Esq., 36, Hyde-park-gardens.

1846-47 Morgan, John, Esq., 3, Sussex-place, Hyde-park-gardens.

1852-53 Moseley, George, Esq., 74, Gower-street, Bedford-square.

1854-55 Murchison, Charles, M.D. (C.), Assistant Physician to King's College and to the London Fever Hospitals, 79, Wimpole-street.

1856-57 Nunn, Thomas William, Esq., Assistant Surgeon to the Middlesex Hospital, 8, Stratford-place, Oxford-street.

1858-59 Nunneley, Thomas, Esq., Senior Surgeon to the Leeds Eye and Ear Infirmary, Leeds.

Elected Session

*1850-51 Obré, Henry, Esq., Surgeon to the St. Marylebone Eye and Ear Institution, 1, Melcombe-place, Dorset-square.

1852-53 O'Connor, William, M.D., Physician to the Royal Free Hospital, 30, Upper Montagu-street, Montagu-square.

*1850-51 Ogle, John W., M.D. (Hon. Secretary), Assistant Physician to St. George's Hospital, 13, Upper Brook-street, Grosvenor-square.

1853-54 Ogle, William, M.D., Physician to the Royal Pimlico Dispensary, 9, Lower Belgrave-street, Eaton-square.

‡1855-56 Oldfield, Edmund, Esq., Boscomb Lodge, Finchley-road.

1857-58 Ord, William Miller, M.B., Registrar and Demonstrator of Anatomy at St. Thomas's Hospital, Brixton-hill.

1854-55 Panton, P., M.D., 1, Pembridge-place, Bayswater.

1853-54 Parkinson, George, Esq., 16, Hereford-street, Park-lane.

1853-54 Part, James, Esq., 7, Camden-road-villas, Camden-town.

**Orig. Memb.* Partridge, Richard, Esq., F.R.S. (late V.P.), Surgeon to King's College Hospital, 17, New-street, Spring-gardens.

**Orig. Memb.* Peacock, Thomas Bevill, M.D. (C.), (late V.P. and Hon. Secretary), Assistant Physician to St. Thomas's Hospital, and Physician to the City of London Hospital for Diseases of the Chest, 20, Finsbury-circus.

**Orig. Memb.* Poland, Alfred, Esq., Assistant Surgeon to Guy's, and Surgeon to the Royal London Ophthalmic Hospitals, 10, Bolton-row, Curzon-street, May-fair.

*1846-47 Pollock, George D., Esq., (late Honorary Secretary), Assistant Surgeon to St. George's Hospital, 27, Grosvenor-street.

1850-51 Pollock, James Edward, M.D., Assistant Physician to the Hospital for Consumption and Diseases of the Chest, Brompton, 52, Upper Brook-street.

1858-59 Potter, Henry, Esq., 22, George-street, Hanover-square.

1854-55 Potts, William, Esq., 12, North Audley-street.

1856-57 Price, Peter Charles, Esq., Surgeon to the Great Northern Hospital, King's-cross, and to the Metropolitan Institution for Scrofulous Children, at Margate, 7, Green-street, Grosvenor-square.

1856-57 Priestley, William Overend, M.D., Physician-Accoucheur to the St. Marylebone Infirmary and the St. George's and St. James's Dispensary, Physician to the Samaritan Free Hospital, 31, Somerset-street, Portman-square.

†1848-49 Purnell, John James, Esq., Surgeon to the Royal General Dispensary, Woodlands, Streatham-hill.

1850-51 Pyle, John, Esq., 56, Oxford-terrace, Hyde-park.

**Orig. Memb.* Quain, Richard, M.D. (Treasurer, late Hon. Secretary), Physician to the Hospital for Consumption and Diseases of the Chest, Brompton, 23, Harley-street, Cavendish-square.

Elected Session

1855-56 Rae, J., Esq., Surgeon, R.N., Haslar Hospital.

**Orig. Memb.* Ramsbotham, Francis H., M.D. (late V.P.), Physician-Accoucheur to the London Hospital, 8, Portman-square.

1856-57 Ramskill, J. Spence, M.D., Senior Physician to the Metropolitan Free Hospital, 5, St. Helen's-place, Bishopsgate-street.

1847-48 Randall, John, M.D., Medical Officer, St. Marylebone Infirmary, 14, Portman-street, Portman-square.

1856-57 Ranke, Henry, M.D.

1846-47 Ray, Edward, Esq., Dulwich.

1858-59 Reed, Frederick George, M.D., 46, Hertford-street, May-fair.

1854-55 Reynolds, J. Russell, M.D., Assistant Physician to the Westminster Hospital, 38, Grosvenor-street.

1856-57 Richardson, Benjamin Ward, M.D., Physician to the Infirmary for Asthma, 12, Hinde-street, Manchester-square.

**Orig. Memb.* Ridge, Joseph, M.D., 39, Dorset-square.

**Orig. Memb.* Roe, George Hamilton, M.D., Senior Physician to the Hospital for Consumption and Diseases of the Chest, Brompton, 57, Park-street, Grosvenor-square.

1855-56 Roberts, John Henry, Esq., 10, Finchley-road, St. John's-wood.

1856-57 Robinson, Thomas, Esq., 50, Southampton-street, Pentonville.

1858-59 Rolleston, George, M.D., Physician to the Radcliffe Infirmary, 5, Broad-street, Oxford.

1851-52 Rooke, H. T., M.D., Wisbeach, Cambridgeshire.

1858-59 Rose, Henry Cooper, Esq., High-street, Hampstead.

1858-59 Rouse, James, Esq., House Surgeon to St. George's Hospital, 62, Coleshill-street, Belgrave-square.

1852-53 Salter, Henry Hyde, M.D., F.R.S., Assistant Physician to the Charing-cross Hospital, 6, Montague-street, Russell-square.

1853-54 Salter, Samuel James A., M.B., Surgeon-Dentist to Guy's Hospital, 17, New Broad-street.

1852-53 Sanderson, Hugh James, M.D., Physician to the Hospital for Women, 26, Upper Berkeley-street.

1854-55 Sanderson, John Burdon, M.D., Medical Officer of Health for Paddington, 9, Gloucester-place, Hyde-park.

*1846-47 Sankey, William H. O., M.D., Middlesex County Lunatic Asylum, Hanwell.

1857-58 Schulhof, Maurice, M.D., Physician to the Royal General Dispensary, Bartholomew-close, 14, Brook-street.

1853-54 Scott, John, Esq., Surgeon to the Hospital for Women, Soho-square, 65, Harley-street, Cavendish-square.

1858-59 Scratchley, George, M.D., B.L.S., Member of the University of France; New Orleans, Louisiana, U.S.

1846-47 Seaton, Edward C., M.D. (C.), Surgeon to the Chelsea, Brompton, and Belgrave Dispensary, 33, Sloane-street, Knightsbridge.

Elected Session

1856-57 Sedgwick, William, Esq., Surgeon to the St. Marylebone Provident Dispensary, 12, Park-place, Upper Baker-street.

1852-53 Semple, Robert Hunter, M.D. (C.), Physician to the Northern Dispensary, 8, Torrington-square.

**Orig. Memb.* Shaw, Alexander, Esq. (V.P.), (late Treasurer), Surgeon to the Middlesex Hospital, 22A, Cavendish-square.

1856-57 Shillitoe, Buxton, Esq., 34, Finsbury-circus.

1855-56 Sibley, Septimus W., Esq., Medical Registrar to the Middlesex Hospital, 12, New Burlington-street.

*1848-49 Sibson, Francis, M.D., F.R.S., Physician to St. Mary's Hospital, 40, Brook-street, Grosvenor-square.

*1847-48 Sieveking, Edward H., M.D., Physician to St. Mary's Hospital, 17, Manchester-square.

1850-51 Simonds, James B., Esq., Professor, Royal Veterinary College.

**Orig. Memb.* Simon, John, Esq., F.R.S., (V.P.), Surgeon to St. Thomas's Hospital, 44, Cumberland-street, Bryanston-square.

1857-58 Siordet, J. Lewis, M.D., Physician to the Blenheim Dispensary.

**Orig. Memb.* Smith, Ebenezer Pye, Esq., 7, Billiter-square.

1854-55 Smith, Edward, M.D., Assistant Physician to the Hospital for Consumption and Diseases of the Chest, Brompton, 6, Queen Anne-street, Cavendish-square.

1846-47 Smith, Protheroe, M.D., Physician to the Hospital for Women, 25, Park-street, Grosvenor-square.

1851-52 Smith, W. Tyler, M.D., Physician-Accoucheur to St. Mary's Hospital, 7, Upper Grosvenor-street.

1855-56 Smith, Spencer, Esq., Surgeon to St. Mary's Hospital, 48, Sussex-gardens, Hyde-park.

1856-57 Smith, Thomas, Esq., St. Bartholomew's Hospital.

1854-55 Squire, William, Esq., 6, Orchard-street, Portman-square.

*1847-48 Solly, Samuel, Esq., F.R.S., Surgeon to St. Thomas's Hospital, 18, St. Helen's-place, Bishopsgate-street.

1857-58 Stallard, Joshua Harrison, L.R.C.P., Physician to the Great Northern Hospital, 12, Welbeck-street, Cavendish-square.

*1850-51 Stanley, Edward, Esq., F.R.S., Surgeon to St. Bartholomew's Hospital, 23A, Brook-street, Grosvenor-square.

1856-57 Stevens, Nicholas Henry, Esq., Surgeon, Islington Dispensary, 14, Finsbury-circus.

1854-55 Stewart, William Edward, Esq., Surgeon to St. Marylebone Provident Dispensary, 8, Weymouth-street, Portland-place.

†1853-54 Streatfeild, J. F., Esq., Assistant Surgeon to the Royal London Ophthalmic Hospital, Moorfields, 15, Upper Brook-street.

†1850-51 Sutherland, Alexander John, M.D., F.R.S., Senior Physician to St. Luke's Hospital, 6, Richmond-terrace, Whitehall.

1858-59 Swete, Benjamin L., Esq., Surgeon to the British Orphan Asylum, Clapham Rise, 7, Park-road, Stockwell.

Elected Session

‡1856-57 Symonds, Frederick, Esq., Surgeon to the Radcliffe Infirmary, 32, Beaumont-street, Oxford.

Orig. Memb. Tamplin, R. W., Esq., Surgeon to the Royal Orthopædic Hospital, 33, Old Burlington-street.

‡1855-56 Tapp, W. Denning, Esq., Senior Surgeon to the Dorset County Hospital, Dorchester.

1850-51 Tatum, Thomas, Esq. (C.), Surgeon to St. George's Hospital, 3, George-street, Hanover-square.

1851-52 Taylor, Robert, Esq., Surgeon to the Central London Ophthalmic Hospital, 10, George-street, Hanover-square.

1848-49 Tebay, Thomas G., Esq., 6, Great Smith-street, Westminster.

1852-53 Thompson, Henry, Esq., (Honorary Secretary) Surgeon to the St. Marylebone Infirmary and Assistant Surgeon to the University College Hospital, 16, Wimpole-street, Cavendish-square.

1851-52 Thompson, Theophilus, M.D., F.R.S. (C.), Physician to the Hospital for Consumption and Diseases of the Chest, Brompton, 3, Bedford-square.

1851-52 Todd, Robert Bentley, M.D., F.R.S., Physician to King's College Hospital, 26, Brook-street, Grosvenor-square.

1856-57 Tomes, J., Esq., F.R.S., Surgeon-Dentist to the Middlesex Hospital, 37, Cavendish-square.

**Orig. Memb.* Toynbee, Joseph, Esq., F.R.S., Aural Surgeon to St. Mary's Hospital, 18, Savile-row.

1851-52 Trotter, John W. Esq., Assistant Surgeon, Coldstream Guards.

1857-58 Tudor, John, Esq., Surgeon to the Seamen's Hospital, Ship "Dreadnought."

1847-48 Tuke, T. Harrington, M.D., Manor-house, Chiswick.

1852-53 Tulloch, James S., M.D., 33, Pembridge-villas, Bayswater.

1857-58 Turtle, Frederick, Esq., Lamberhurst, Surrey.

1856-57 Tyrrell, Walter, Esq., Surgeon to the National Truss Society, 1, St. Helen's-place, Bishopsgate-street.

1853-54 Van der Byl, Philip, M.D.

1854-55 Vasey, Charles, Esq., Surgeon-Dentist to St. George's Hospital, 4, Cavendish-place, Cavendish-square.

1856-57 Valpy, William H., Esq., Bedford-square.

1856-57 Vernon, Henry Hannotte, M.D., Physician to the Great Northern Hospital, King's-cross.

1850-51 Wagstaff, W. R., M.D.

Orig. Memb. Waite, Charles D., M.D., Senior Physician to the Westminster General Dispensary, 3, Old Burlington-street.

1851-52 Walker, John Butterworth, Esq., 17, Clifton-gardens, Maida-hill.

Elected Session

Orig. Memb. Walton, Henry Haynes, Esq., Surgeon to the Central London Ophthalmic Hospital, and Surgeon to St. Mary's Hospital, 69, Brook-street, Hanover-square.

‡*Orig. Memb.* Ward, Joseph, Esq., Epsom, Surrey.

Orig. Memb. Ward, Nathaniel, Esq. (formerly Honorary Secretary), Assistant Surgeon to the London Hospital, 1, Broad-street-buildings.

*1846-47 Ward, T. Ogier, M.D., 9, Leonard-place, Kensington.

1857-58 Wardell, John Richard, M.D., 4, Belmont, Tunbridge Wells.

Orig. Memb. Ware, James T., Esq., Consulting Surgeon to the Finsbury Dispensary, 51, Russell-square.

1855-56 Watson, Thomas, M.D., F.R.S., (V.P.), Consulting Physician to King's College Hospital, 16, Henrietta-street, Cavendish-square.

1854-55 Webb, Francis Cornelius, M.D., 39, Great Coram-street.

1857-58 Weber, Hermann, M.D., Physician to the German Hospital, 49, Finsbury-square.

1851-52 Welch, Henry W. James, Esq., 1, Dalston-terrace.

1853-54 Wells, Thomas Spencer, Esq., Surgeon to the Samaritan Free Hospital for Women and Children, 3, Upper Grosvenor-street.

*1850-51 West, Charles, M.D., Physician-Accoucheur to St. Bartholomew's Hospital, and Physician to the Hospital for Sick Children, 61, Wimpole-street, Cavendish-square.

1858-59 White, Frederick, Esq., 21, York-place, Brompton.

1856-57 Wilkin, Herbert C., Esq.. 39, Connaught-terrace, Hyde-park.

1854-55 Wilks, Samuel, M.D. (C.), Assistant Physician and Demonstrator of Morbid Anatomy at Guy's Hospital, 11, St. Thomas's-street, Southwark.

Orig. Memb. Williams, C. J. B., M.D., F.R.S. (formerly President), (V.P.), Consulting Physician to the Hospital for Consumption and Diseases of the Chest, Brompton, 49, Upper Brook-street, Grosvenor-square.

1858-59 Williams, Charles, Esq., House Surgeon to the Norfolk and Norwich Hospital, Norwich.

1858-59 Wilson, Edward, M.B., Hean Castle, Tenby.

1850-51 Wood, John, Esq. (C.), Assistant Surgeon to King's College Hospital, 4, Montague-street, Russell-square.

1854-55 Wood, Barnes, M.D., 18, Gloucester-place, Hyde-park.

1854-55 Wood, William, M.D., 54, Upper Harley-street.

1853-54 Wordsworth, John C., Esq., Assistant Surgeon to the London and to the Royal London Ophthalmic Hospitals, 41, Finsbury-square.

1852-53 Wright, Edward John, Esq., 13, Montague-place, Clapham-road.

1858-59 Wynter, H., Esq., Resident Assistant Medical Officer at St. George's Hospital.

LIST OF SPECIMENS

EXHIBITED AT THE MEETINGS OF THE SOCIETY DURING THE SESSION 1858-9.

DISEASES, ETC., OF THE NERVOUS SYSTEM.

		Page
1. Case of Neuroma.	Dr. WILKS	1
2. Aneurysm of the Anterior Communicating Artery; Rupture.	Dr. BRISTOWE	3
3. Small Aneurysm in the substance of the Cerebellum; Gout; Renal Disease; Emphysema of the Lungs, &c.	Dr. BRISTOWE	4
4. Case of Hydatid in the Brain.	Dr. BARKER	6
5. Case of red softening of the central portions of the Brain, produced by Syphilitic Disease of the Bones of the Cranium.	Mr. HENRY LEE	8
6. Fibrous Tumour of the Dura Mater.	Mr. CHRISTOPHER HEATH	10
7. Fatal Epilepsy, resulting from Superficial Cerebral Hæmorrhagic Effusions.	Dr. BRISTOWE	11

		Page
8. Abscess in the Pons Varolii.	Mr. Gay	14
9. Brain of an Idiotic Boy nearly Eleven Years of age.	Dr. Peacock	15
10. Syphilitic (?) Disease of the Brain and Liver; with Obstruction by clots of Cerebral Arteries.	Dr. Bristowe	21
11. Two cases of Cholesteatomatous Tumour of the Brain.	Dr. Wilks	24
12. An Encephaloïd Tumour attached to the Cerebellum of a Child.	Dr. Hillier	26
13. Cases illustrating Disease of the Central and other parts of the Brain as a result of obstruction to the passage of Blood through the Veins and Sinuses of the Cranium.	Dr. John W. Ogle	28
14. Epilepsy; Idiotcy; Hemiplegia on the left side of the Body, with frequent spasmodic action, and chilliness of the paralyzed limbs. Atrophy of the Right Hemisphere of the Brain in connection with distention (from old inflammation?) of the lateral Ventricles; also Atrophy of the Left Cerebellar Hemisphere.	Dr. John W. Ogle	38

		Page
15. Analysis of seven cases of Obstruction of the Cerebral Arteries.	Dr. Bristowe . . .	44
Case 1. Obstruction of both Vertebral and Basilar Arteries. Circumscribed Softening of posterior part of Left Cerebral Hemisphere.	Dr. Bristowe . . .	49
Case 2. Obstruction of both Internal Carotids and their Branches. Congestion of the Brain without softening.	Dr. Bristowe . . .	50
Case 3. Obstruction of both Internal Carotids and their Branches. Softening of the Anterior Cerebral Lobes and Right Corpus Striatum.	Dr. Bristowe . . .	50
Case 4. Obstruction of the Right Middle Cerebral. Softening of the Right Corpus Striatum. Vegetations on the Mitral Valve.	Dr. Bristowe . . .	51
Case 5. Obstruction of the Right Middle Cerebral Artery. Congestion of the Right Corpus Striatum. Vegetations on the Aortic and Mitral Valves.	Dr. Bristowe . . .	53

		Page
CASE 6. Effusion of blood into the Left Corpus Striatum. Extensive Softening of the surrounding Brain Substance. Blocking up of the Left Internal Carotid and its Middle Cerebral Branch.	Dr. BRISTOWE	54
CASE 7. Syphilitic (?) Disease of the Brain. Obstruction of the Left Internal Carotid and Branches.	Dr. BRISTOWE	56
16. Softening of the Spinal Cord, from concussion, arising from Fracture of the Cranium and of the sixth Cervical Vertebra.	Dr. ANSTIE	59

DISEASES, ETC., OF THE ORGANS OF RESPIRATION.

1. Cicatrization and Contraction of the Trachea and Bronchi after Expectoration of Cartilaginous Rings.	Dr. SYDNEY JONES	60
2. Atelektasis Pulmonum.	Mr. HENRY OBRÉ	61
3. Specimen of Wound of the Lung extending to its Roots.	Dr. SYDNEY JONES	61
4. Cancerous Tumour in the groove between the Trachea and Œsophagus, on the left side, eating into the Trachea just below the Larynx and into the Œsophagus. Death from Dyspnœa, occasioned probably by destruction of the left recurrent nerve.	Dr. BUDD	62

		Page
5. Epithelioma of the Larynx	Mr. N. Ward	63
6. Note in reference to the Specimen of Casts of the Bronchial Tubes figured in Plate III., Figs. 3 and 4 of the IXth Vol. of the "Transactions."	Dr. Peacock	65
7. Hydrarthrosis of the Left Thyro-hyoïd Articulation, and Dislocation of the Os-hyoïdes.	Dr. Gibb	66
8. Complete Ossification of the Thyroïd and Cricoïd Cartilages.	Dr. Gibb	68
9. Case of Croup, in which the False Membrane extended from the Fauces to the Minute Bronchial Tubes.	Dr. Barker	69

DISEASES, ETC., OF THE ORGANS OF CIRCULATION.

1. Communication between the Aorta and Left Bronchus.	Mr. Spencer Wells	71
Report on the above Specimen	Francis Sibson, M.D. Charles Murchison, M.D. T. Spencer Wells	71
2. Aneurysm of the Arch of the Aorta.	Dr. Pollock	73
3. Aneurysm of the Arch of the Aorta.	Dr. Pollock	76

4.
Constriction of the Thoracic Aorta. } Dr. Wilks 77

5.
Malformation of the Pulmonary Valves. } Dr. Wilks 79

6.
Hydatid Tumour in the Apex of Right Ventricle of the Heart. } Dr. Budd 80

7.
Cured Aneurysm of the Arch of the Aorta. } Dr. Bristowe 83

8.
Case of Aneurysm of the Abdominal Aorta, in which death was produced by Accumulation of Effused Blood around the Lower Extremity of the Œsophagus, and consequent obstruction. } Dr. Bristowe 84

9.
Malformation of the Heart, with Cyanosis. } Dr. Sanderson 89

10.
Malformation of the Heart. The Pulmonary Artery impervious at its origin, &c. } Dr. Baly 90

11.
Rupture of the Aortic Valves by Violence. } Dr. Peacock 92

12.
An Injected Preparation of a Specimen of Obliteration of the Thoracic Aorta. } Mr. J. Wood 97

		Page
13. Ulceration of the Internal Jugular Vein.	Dr. Murchison for Dr. Sourrah . . .	99
14. Aneurysm of the Aorta with a peculiar Condition of the Liver.	Dr. G. Johnson . . .	99
15. Arterial Obstruction, producing Fatal Phagedæna of the Face.	Mr. John Simon . . .	101
16. Enormous Aneurysm of the Right Subclavian Artery—Peculiar Cyanosis and Club-shaped condition of the Fingers, with remarkable Hypertrophy of their nails—Death after two attacks of outward Hæmorrhage from Rupture of the Aneurysmal Sac.	Dr. John W. Ogle . .	103
17. Rupture of an Aneurysm of the Intra-Pericardial portion of the Aorta.	Mr. T. W. Coulson . .	105
18. Aneurysm of the Innominate Artery.	Mr. Christopher Heath .	106
19. Contraction of the Orifice of the Pulmonary Artery from Fusion of the Valves.	Dr. Peacock . . .	107
20. Re-opening of the Foramen Ovale.	Dr. Peacock . . .	108

		Page
21. Congenital Malformation of the Heart; Perforation of the Septum Ventriculorum, establishing a communication between the Left Ventricle and the Right Auricle.	Dr. Hillier	110
22. Ruptured Aneurysm of the Heart.	Dr. Wilks	111
23. Disease of the Pulmonary Valves in an Infant. Sudden Death.	Dr. Graily Hewitt	112
24. Disease of the Tricuspid Valve; detachment of Fibrinous Concretion, and impaction of the same in the Left division of the Pulmonary Artery.	Dr. Bristowe	114
25. Plugging of the Superior Longitudinal Sinus and Cerebral Veins, with Paralysis and Loss of Speech.	Dr. Crisp	117
26. Two specimens of Abnormal Origin of the Right Subclavian Artery.	Mr. John Wood	119

DISEASES, ETC., OF THE DIGESTIVE ORGANS.

I. PHARYNX, ŒSOPHAGUS, STOMACH, AND INTESTINES.

		Page
1. Right Inguinal Hernia developed in Childhood; Testis over the External Abdominal Ring; Reduction of the Hernia, Adhesion and Perforation by Ulceration of the Walls of the Intestine at the seat of Stricture. Death six months after from acute Peritonitis.	Mr. Birkett	128
2. Epithelial Cancer of the Œsophagus, opening into the Trachea.	Mr. Christopher Heath	130
3. Sac of a Strangulated Umbilical Hernia with adherent Omentum, successfully removed.	Mr. Christopher Heath	131
4. Communication between the Sigmoïd Flexure and the Bladder, the result of Ulceration of a false Diverticulum.	Sydney Jones, M.B.	131
5. Enormous Hydatid Tumour of the Omentum, accompanied by nine small Hydatid Tumours.	Dr. Budd	132
6. Two specimens of Perforating Ulcer of the Small Intestine in Typhoïd Fever.	Dr. Murchison	134

		Page
7. Colloïd Cancer of the Sigmoïd Flexure of the Colon, causing Stricture and Obstruction, complicated with incarcerated Hernia.	Mr. Oliver Chalk	136
8. Pharynx of a Child aged Two Years and a-half, affected with Scarlatinous Membranous Angina.	Dr. Sanderson	139
9. Extensive Dilatation of the Œsophagus.	Dr. Barker	140
10. Carcinomatous Stricture of the Œsophagus.	Dr. Peacock	142
11. Ulcers of the Stomach.	Dr. Peacock	143
12. Stricture of the Œsophagus.	Mr. Obré	144
Report upon the above specimen of Stricture of the Œsophagus.	Graily Hewitt, M.D. S. Sibley, and J. Wood	144
13. Cancer of the Œsophagus, causing a large opening into the Trachea, just above the Bifurcation. Food passed from the Œsophagus into the Trachea, and rejected by Coughing.	Dr. Budd	145
14. Malignant Fibroïd Disease of the Stomach.	Dr. Wilks	146

		Page
15. Case of Enteritis.	Dr. Bristowe	148
16. The Ulceration of the Appendix Vermiformis.	Dr. Crisp	151
17. Fatal Obstruction, from Twisting of the Meso-colon.	Mr. Gay	153
18. Stricture of the Ileum, with accumulation of Plum-stones above the seat of Stricture. Malarious Symptoms.	Dr. Peacock and Dr. Bristowe	154
19. Scirrhous and Colloïd Disease, causing complete obstruction of the Rectum, for which the Colon was Opened in the Left Loin.	Mr. Curling	157
20. Carcinoma of the Œsophagus.	Dr. Wilks	159
21. Portions of the Ileum, Cæcum, and Colon, discharged by Stool, in a case of Intus-susception. Recovery.	Dr. Quain	160
22. Simple Stricture of the Sigmoïd Flexure; Constipation, forty-one Days, relieved by opening the Left Colon behind the Peritoneum. Death from Ulceration and Perforation immediately above the Seat of Stricture.	Mr. H. Thompson	161

		Page
23. Stricture of the Pylorus, resulting from the destructive action of Burnet's Disinfecting Fluid.	Dr. MARKHAM	164
24. Ulceration of the Œsophagus near its lower extremity, completely preventing the passage of food.	Dr. W. BALY	165
Report on the above case.	J. S. BRISTOWE, M.D., and W. O. MARKHAM, M.D.	167
25. Wounds of the Stomach, Jejunum, and Abdominal Aorta, from a Pistol-shot.	Mr. SHAW	168
26. A Specimen of Inguinal Hernia of the right side; the Sac containing the Appendix Vermiformis.	Mr. JOHN WOOD	170
27. Case of Invagination of the Large Intestine in an Infant.	Dr. G. BUCHANAN for Mr. A. BUCHANAN	171
28. The Stomach of an Infant, the posterior wall of which was extensively destroyed by the Gastric Juice.	Mr. BALLARD	172

II. LIVER AND ITS APPENDAGES.

		Page
29. Primary Encephaloïd Disease of the Liver.	Mr. H. Thompson	173
30. Association of Cystic Disease of the Liver and Kidneys.	Dr. Bristowe	174
31. Case of total Atrophy of the Gall-bladder.	Mr. J. Wood	176
32. Gall-stone impacted in the Common Duct of the Liver; Rupture of the Gall-bladder, and death from Hæmorrhage.	Dr. Leared	177
33. Colloïd Disease of the Liver.	Dr. Wilks	178
34. Cancerous Tubercle of the Liver and Stomach; Gall-bladder filled with pus and a Calculus; Ascites; Enlarged Liver.	Dr. Gibb	179
35. Tubercles in the Liver, in connection with the question of so-called "Dilatation of the Gall-ducts," occurring in some cases of general Tuberculosis.	Dr. Hare	182
36. Case of Fatal Obstruction of the Small Intestines by a Gall-stone.	Dr. Baly	184

DISEASES, ETC., OF THE GENITO-URINARY ORGANS.

		Page
1. Ovarian Cyst removed successfully.	Mr. Spencer Wells	187
2. Specimen of Encephaloïd Cancer of the Kidney.	Mr. T. Ballard	188
3. Ovarian Cyst which had contained seventy-two pints of Fluid.	Mr. Spencer Wells	189
4. Cyst of the Broad Ligament.	Mr. Spencer Wells	189
5. Case of Single Unsymmetrical Kidney.	Dr. Murchison	190
6. Abscess in the Right Lumbar Region, attached to the Kidney; Ulceration of the Bladder.	Mr. Obré	190
7. Strumous Disease of the Right Testicle in a Child aged Two Years and a-Half.	Mr. T. Bryant	191
8. Mass of Substance, of uncertain character, passed by the Vagina.	Dr. John W. Ogle, for Dr. Kennion	192
Report on the above case.	W. O. Priestley, M.D., and John W. Ogle, M.D.	192
9. Large Fibrous Tumour of the Uterus.	Dr. Quain	194

		Page
10. Two Ovarian Cysts—Ruptured Spontaneously.	Mr. Spencer Wells	196
11. Pseudo-Colloïd Ovarian Tumour, successfully Removed.	Mr. Spencer Wells	197
12. A Kidney, containing very numerous and unusually large Calculi.	Mr. T. Holmes	197
13. Fibrous Tumour of the Ovary.	Mr. Spencer Wells	199
14. Fatty and Atrophied Kidney.	Mr. Christopher Heath	199
15. Uterus Unicornis.	Mr. T. W. Nunn	200
16. Pseudo-Colloïd Ovarian Tumour, removed during life by Ovariotomy.	Mr. Spencer Wells	200
17. Case of Double Urethra, taken from a full-grown well-developed man; also the subject of an Obliteration of the Aorta, see page 97.	Mr. J. Wood	201
18. Case of an Ovarian Cyst containing Hair, Epithelial Cells, and Fat in abundance.	Mr. J. Wood	201
19. Fibrous Tumours of the Uterus.	Mr. Henry Thompson	202

		Page
20. Vesico-vaginal Fistula.	Mr. Holmes	202
21. Liquid Fat from a Piliferous Ovarian Cyst.	Dr. Wilks	204
22. Encephaloïd Cancer of the Testicle.	Mr. Curling	205
23. Case of Follicular Tumour of the Uterus.	Mr. J. Wood	206
24. Two Specimens of Ovarian Disease.	Mr. T. W. Nunn	207
25. Communication between the Bladder and the Sigmoïd Flexure of the Colon.	Mr. Charles Hawkins	208
26. Obliteration of a Ureter. Abscess-like Dilatation of the Calices of the Kidney.	Dr. Quain for Mr. Alfred Haviland	209
27. Syphilitic Fibroïd Degeneration of the Testis.	Dr. Wilks	210
28. Case of Retention of Fœtal Bones in a Uterus affected with Cancer.	Dr. Coote	210

DISEASES, ETC., OF THE OSSEOUS SYSTEM.

		Page
1. Dislocation of the Head of the Right Femur into the Obturator Fossa, in a Man deformed from Rickets.	Mr. SHAW	211
2. Acute Periostitis of the Tibia, with Necrosis of the entire shaft of the Bone, following Strumous Disease of the Ankle-joint.	Mr. W. H. FLOWER	214
3. Necrosis of the Inter-maxillary Bones.	Mr. T. BRYANT	216
4. Disease of the Knee-joint supposed to be Strumous.	Mr. T. HOLMES	217
5. Dislocation of the Spine in the Dorsi-Lumbar Region.	Mr. T. HOLMES	219
6. Right Lower Limb removed by Amputation through the Thigh two Years and three Months after Excision of the Knee-joint.	Mr. PRICE	220
7. Portions of Bones, forming the Right Elbow-joint, removed by the Operation of Excision, on Account of extensive Disease of the Articulation.	Mr. PRICE	223
8. Dislocation of the Astragalus.	Mr. N. WARD	224

		Page
6. Disease of the upper surface of the Sphenoïd Bone. Ptosis and complete immobility of both Eyeballs. Dysphagia and difficulty in articulation, opening the mouth, or protruding the tongue. Loss of power in the Arms.	Dr. John W. Ogle . .	224
10. Old Disease of the Knee-joint repaired.	Mr. T. Bryant . . .	229
11. Disease of the Hip-joint of fifty years' duration.	Mr. T. Bryant . . .	230
12. Right Knee-joint removed by Excision on account of Deformity from old-standing disease.	Mr. Price	231
13. Portions of Bones forming the Left Knee-joint removed by the operation of Excision on account of accident; also the False joint which resulted.	Mr. Price for Mr. Canton	232
14. Large Cavity in the Head of the Tibia, not that of an Abscess. Query, Hydatid?	Mr. Henry Thompson for Mr. E. Hearne . .	233
15. Spontaneous Fracture of both Bones of the Leg, following extensive Ulceration from Epithelioma.	Mr. Henry Thompson .	234

16. Page

Secondary Cancer of the Femur, followed by spontaneous Fracture. } Dr. Coote . . . 235

DISEASES, ETC., OF THE ORGANS OF SPECIAL SENSE.

1.

Fracture of the Handle of the Malleus of the Ear. } Mr. Joseph Toynbee . . 236

TUMOURS, CYSTS, INCLUDING HYDATIDS, ETC.

1.

Tumour of the Upper End of the Tibia, containing numerous Myeloïd Bodies. } Mr. Henry Thompson . 237

2.

Cancerous Tumour of the Mediastinum involving and obstructing the Superior Vena Cava. } Dr. Murchison . . . 240

3.

Hydatid developed beneath the Fascia and short Head of the Biceps Femoris, removed entire. } Mr. Thomas Bryant . . 243

4.

Erectile Tumour of the Leg. Mr. Brooke . . . 243

5.

Myeloïd Tumour of the Fibula, with Secondary Growths in the Lungs. } Dr. Wilks 244

6.

Lobular Fibrous Tumour of the Scrotum. } Mr. Curling . . . 245

		Page
7. Fibro-Plastic and Myeloïd Tumour of the Femur.	SYDNEY JONES, M.B.	246
8. Sequel to a Case of Myeloïd Disease of the Humerus.	SYDNEY JONES, M.B.	247
9. Mass of Hypertrophied Lymphatic Glands, removed from the Axillary Space.	Mr. HILLMAN	248
10. Malignant Tumour of the Humerus.	Mr. T. HOLMES	249
11. Cartilaginous Tumour of the Skull and Face.	Mr. T. HOLMES	250
12. Epithelial Cancer occurring in the Cicatrix of a Burn on the Arm.	Mr. W. H. FLOWER	253
13. Melanotic Recurrent Fibroïd Tumour.	Dr. WILKS	255
14. Colloïd Cancer from the Calf of the Leg.	Mr. W. H. FLOWER	256
15. Sub-cutaneous Malignant Tumours containing Melanotic Matter.	Mr. HENRY THOMPSON	257
16. Recurrent Fibroïd Tumour at the Bend of the Elbow, for which the Arm was Removed.	Mr. SHILLITOE	258

DISEASES, ETC., OF THE DUCTLESS GLANDS.

I. THE SPLEEN.

		Page
1. Enlargement of the Spleen and Lymphatic Glands.	Dr. Wilks	259
2. Cystic Disease of the Spleen.	Dr. Wilks	263

II. SUPRA-RENAL CAPSULES.

3. Bronzed Skin; Supra-renal Capsules healthy.	Dr. Harley	264
4. Tubercular Disease of the Supra-renal Bodies. Bronzed Skin.	Mr. Sibley	266
5. Extensive deposit of Tubercle in the Supra-renal Bodies. No Discoloration of the Skin.	Dr. Murchison for Dr. Scurrah	268
6. Diseased Supra-renal Capsules. Pericarditis. No Discoloration of the Skin.	Dr. Markham	268
7. Diseased Supra-renal Capsules. Extensive Discoloration of the Skin.	Mr. Simon for Dr. E. H. Greenhow	269
8. Extensive Disease of the Supra-renal Capsules. No Discoloration of the Skin.	Dr. Charles Coote	271

Page

9.
Epithelial Cancer of one of the Supra-renal Capsules, with similar Disease of the Tongue. No Discoloration of the Skin. — Mr. S. W. Sibley . . 272

10.
Case of Bronzed Skin, with Disease of the Supra-renal Capsules. — Dr. Wilks for Mr. Welford 273

MISCELLANEOUS SPECIMENS.

MALFORMATIONS, DIPHTHERIA, MORBID STATES OF THE BLOOD, TEETH, ETC.

1.
A Dissected Specimen of Non-congenital Club-foot, of Paralytic Origin, and of Fifty Years' standing. — Mr. Brodhurst . . . 279

2.
Case of "Typhoid Fever," remarkable for the copious eruption of rose-coloured papules. — Dr. Murchison . . . 283

3.
Specimens showing the co-existence of Tubercle and Cancer. Cancer of the Uterus. Tubercle of the Lungs. — Dr. Bristowe . . . 284

4.
Suicidal Poisoning by Aconite. — Dr. Sanderson . . . 285

5.
A Report on Malformations of the Teeth, as indicative of Diathesis. — Mr. Hutchinson . . 287

		Page
6. Peculiar Condition of Human Skin.	Mr. Frank Buckland	299
7. An Inquiry into the existence of Amylaceous Compounds in the Human Body.	Dr. J. S. Bristowe, and Mr. W. M. Ord	299
8. Fœtus, presenting several remarkable Deformities and Malformations.	Mr. Christopher Heath	304
9. Malformation of the Left Lower Extremity, &c.	Mr. Thomas Bryant	305
10. A Wax Model and a Dissection of the Malformed Right Hand of a Woman.	Mr. John Wood	306
11. Dissection of a Specimen of Flat-foot (talipes valgus), in a Man of advanced years.	Mr. John Wood	307
12. Case of a Boy, aged Five Years and a-Half, born without legs, and with each arm only about two inches in length.	Dr. Hare	308
13. Case of Epithelial, or Warty Growth upon the Chordæ Vocales.	Mr. John Wood	311

II. DIPHTHERIA.

		Page
14. Microscopic Drawings of the Deposit in a case of Aphthous Exudation and in one of Diphtheria.	Dr. PEACOCK . . .	311
15. False Membrane, covering the Tonsils and the Epiglottis, and lining the Larynx and the Trachea, in a Case of Diphtheria.	Dr. SEMPLE . . .	313
16. Part of the Tongue, the Tonsils, Pharynx, Œsophagus, Epiglottis, Larynx, and Trachea of a Child who died of Diphtheria.	Dr. SEMPLE . . .	314
17. Fauces, Larynx, and Trachea of an animal that had been inoculated with Diphtheritic exudation. — Query: Can Diphtheria be communicated by Inoculation?	Dr. HARLEY . . .	315
18. Specimens illustrating the Morbid Anatomy of Diphtheria.	Mr. SIMON	319
Report on the Kidney from the above case	GEORGE JOHNSON, M.D., and S. WILKS, M.D. . .	319
19. Membranous Cast of Trachea and Bronchi expectorated by a patient labouring under Diphtheria.	Dr. MURCHISON . . .	320

Page

20.
On the Morbid Anatomy of Diphtheria. } Dr. J. S. BRISTOWE . . 321

CASE 1.
Diphtheria. Fatty Degeneration of the Heart. Renal Affection. Internal Hæmorrhage, &c. } Dr. J. S. BRISTOWE . . 326

CASE 2.
Diphtheria. Lobular Pneumonia, &c. } Dr. J. S. BRISTOWE . . 331

CASE 3.
Diphtheria. Extension of disease along the Œsophagus. } Dr. J. S. BRISTOWE . . 333

SPECIMENS FROM THE LOWER ANIMALS.

1.
Intestines of a Pig, which for six weeks before death had been fed with "Typhoïd Dejections." } Dr. MURCHISON . . . 334

2.
Mammary Cancer in a Bitch. Dr. OGIER WARD . . 337

3.
Specimens of Coagulation of the Blood in the Lower Animals. } Dr. CRISP 337

4.
Two Puppies with Hare-lip. Mr. CHRISTOPHER HEATH . 338

5.
Calcareous infiltration of the Kidneys of a Parrot, with softening (Post-mortem Digestion?) of the lower part of the Œsophagus. } Dr. OGIER WARD . 338

		Page
6. Drawing, showing Atrophy of the Muscles on one side of the Larynx of a "Roarer" (Horse). Observations on Modifications of the Human Voice, &c., in consequence of Paralysis of the Laryngeal Nerves by pressure.	Dr. JOHN W. OGLE . .	339

INDEX TO PLATES.

PLATE		PAGE
I.	Case of Red Softening of the Brain (Mr. HENRY LEE)	10
II.	Case of Idiotcy: the Upper Surface of the Brain (Dr. PEACOCK)	19
III.	Ditto: Section through the Lateral Ventricles of the Cerebrum	19
IV.	Case of Atrophy of the Right Hemisphere of the Brain (Dr. OGLE)	39
V.	Case of unusually large Sub-clavian Aneurysm: Views of the Tumour during Life, and of the Sub-clavian Aneurysm after Death (Dr. OGLE)	103
VI.	Case of Enchondromatous Tumour within the Skull (Mr. T. HOLMES)	252
VII.	Case of Colloid from the Calf of the Leg (Mr. FLOWER),	256
	Case of Bronzed Skin (Dr. HARLEY)	265
VIII.	Syphilitic Malformations of the Permanent Teeth (Mr. HUTCHINSON)	294
IX.	Syphilitic and Non-syphilitic Malformations of the Teeth (Mr. HUTCHINSON)	289
X.	Case of Aphthous Exudation (Dr. PEACOCK)	311
	Case of Diphtheritic Exudation (Dr. PEACOCK)	312
	Ditto Ditto (Dr. BRISTOWE)	322

INDEX TO WOODCUTS.

FIG.		PAGE
1.	Aneurysm in the Substance of the Cerebellum	5
2.	Red Softening of the Brain—the Brown Effused Patches on the Dura-mater	9
3.	Obstruction to Passage of Blood through the Cranial Veins—Laminated and partly Disintegrated Clot in the Lateral Sinus	29
4.	Rupture of the Aortic Valves—the Heart Laid Open to show the Torn and Retroverted Valve and the Thickened Muscular Walls	95
5.	Disease of the Pulmonary Valves in an Infant—Right Ventricle and Pulmonary Artery Laid Open, showing Vegetations on the Valves	113
6.	Abnormal Origin of the Right Sub-clavian Artery—Diagram of the Five Vascular Neck Arches in the Ovum of the Dog	124
7.	Ditto—Diagram of the Developmental Changes of the Vascular Neck Arches in the Human Subject	124
8.	Ditto—Diagram of the Two Forms of Abnormal Right Sub-clavian Artery	125
9.	Case of Right Inguinal Hernia—Portion of the Jejunum which formed the Hernia, cut open by a longitudinal incision	129
10.	Kidney containing numerous and large Calculi	198
11.	Necrosis of the Inter-maxillary Bones	217
12.	Disease of the Sphenoid Bone, its Porous Condition, Hard Nodules of New Bone	227
13.	Fracture of the Malleus of the Ear	237
14.	Dissected Parts of a Case of Non-Congenital Clubfoot	280
15.	Syphilitic Upper and Lower Teeth	296
16.	Back and Front Views of a Malformation of the Left Lower Extremity	306
17.	Boy, born without Legs, and with Arms Two Inches in Length	308
18.	Renal Tubules, containing Granular Matter, from a Case of Diphtheria	319
19.	Atrophy of the Muscles on one side of the Larynx of a "Roarer" (Horse)	340

REPORT.

B524

REPORT.

SESSION 1858-9.

I.—DISEASES, ETC., OF THE NERVOUS SYSTEM.

1. *Case of Neuroma.*

These tumours of the nerves were found, as is generally the case, accidentally. The subject was a woman, æt. 25, who died in Guy's Hospital from disease of the lungs, called phthisis. As she was a woman of dissolute habits, and had no friends, nothing could be learned of her antecedents, but while in the Hospital her only symptoms were referrible to the pulmonary disorder; she never made any complaints or appeared to suffer in any remarkable manner, and this fact agrees with other observations of neuroma being a painless affection. The body being required for anatomical purposes by Mr. Poland, these tumours were found affecting the nerves of nearly every part of it; none, however, were felt externally. The largest was the size of a pigeon's egg, on the sciatic nerve, and all the others were smaller. Every nerve in the legs and arms was affected; the cranial nerves could not be examined owing to the mutilation the head had undergone, but the pneumogastric nerves were both involved; they had a number of nodules upon them, giving them the appearance of ganglionic nerves,—the phrenics were unaffected. The peculiarity of the case was the universality of the disease, scarcely a nerve in the body having escaped; thus there were tumours in some parts, nodules in others, and the remaining nerves, which at first sight appeared unaffected, were found on more minute examination to be indurated and irregular in shape.

On *microscopical examination*, the swelling was found to be due to the presence of a simple fibrous tissue, infiltrated between the fasciculi or nerve fibres, and thus causing their separation without

injury to their structure, for in all parts examined their integrity remained. In those trunks where there was no very visible enlargement, an induration had taken place, owing to this exudation in smaller quantities, and even in parts where scarcely any perceptible difference to the eye existed, the fibres were found closely adherent, and with difficulty were separated from one another. Many of the enlargements might be seen due, not so much to an effusion of fibrin amongst the separate nerves, as to a few large nodules in the smaller fasciculi. If the term inflammation be used as is often the case, in rather a loose and general sense, as expressive of a fibrinous exudation and induration; the condition found in these structures might perhaps be better understood by saying, that a general chronic inflammation had affected all the nerves in the body, whereby a lymph had been thrown out, which had subsequently fibrillated and hardened, and united the nerve fibres together, producing a mere induration at some parts, enlargement in others, and actual tumours in the remainder.

It has been said that the patient died of phthisis and these tumours were found accidentally, but in all probability, the affection of the nerves, that is of the pneumogastric, was the cause of the pulmonary disease, and therefore so far from neuroma being a harmless affection it was the cause of the girl's death. This idea was suggested by the observation of several other cases of pneumonia, occurring in connection with disease of these nerves,—particularly as witnessed in aneurysm of the aorta and cancer of the œsophagus; in these diseases death is often brought about by pulmonary affection, and the pneumogastric nerves are found implicated in the disease or pressed on by the tumour. It was impossible to say in this case that the left nerve was more involved than the right, but the condition of the lung suggested this as a cause, for the disorganization resulted from chronic pneumonia rather than tuberculous deposit; the right lung, also, was quite healthy, and no tubercle existed in any other part of the body. In all probability, the disease of the pneumogastric nerve was the cause of death through the lung.

As regards the pathology little can be said, but as syphilis is considered by some to be the cause of local neuromata, so in this case it may be looked upon as a probable cause, although there

was no evidence for or against. The patient was a prostitute, but no inquiries were made with reference to this point. There can be no objections, however, against its being considered a probable cause, since it would be no pathological novelty to place the disease under the category of a peculiar affection of the tissues of the body, due to the presence of a low organized fibrinous deposit and originating in a syphilitic taint.

Dr. WILKS, *2nd of November*, 1858.

---

2. *Aneurysm of the Anterior Communicating Artery; Rupture.*

C. C., a woman, æt. 60, was brought to the Hospital insensible, and died in a few minutes, before she could be seen. A very short time before admission she had fallen down in a fit.

Post-mortem examination.—Of ordinary stature and in good condition.

Calvaria and dura mater healthy. A considerable quantity of partially coagulated blood was found in the cavity of the arachnoïd, but it was more abundant at the base than over the upper part of the brain. On removing the brain and washing it, it was further discovered that a large quantity of blood occupied the sub-arachnoïd tissue. This was chiefly collected about the circle of Willis, and the internal extremities of the Sylvian fissures. The origins of the nerves and all the arteries in this situation were concealed. The effusion extended hence in various directions, so that the greater part of the brain was enveloped either in blood-stained serum or in actual coagulum. The latter was tolerably abundant over nearly the whole of the base of the organ—extending to the bottom of the sulci; and was abundant also along the lower part of the apposed portions of the cerebral hemispheres. The substance of the brain generally was pretty healthy; but in the anterior part of each corpus striatum were the imperfect cystic remains of old apoplectic effusions. The lateral ventricles contained a little serous fluid; the fourth was distended with coagulum.

The vessels at the base were very extensively diseased. The vertebral and basilar arteries formed irregular, opaque, buff-coloured, thick-walled, rigid cylinders, but were not larger than

natural; and the latter, at its point of bifurcation, presented a small rounded commencing aneurysmal dilatation. Almost all the branches of these vessels were in the same condition as the parent trunks. The internal carotid arteries and their branches were equally diseased with the basilar; and the anterior communicating artery was dilated into an aneurysmal pouch, about as large as a horse-bean. It was of irregular shape, and of varied thickness; and in its thinnest part presented a large slit, through which the fatal hæmorrhage had taken place. Another aneurysm about as large as a tare was discovered in the left middle cerebral artery, about one inch from its origin.

Pericardium and heart healthy. The latter weighed twelve ounces, and its ventricles were contracted and empty. The pleuræ presented a few old adhesions, but the lungs were healthy. The aorta was thickly studded with earthy and atheromatous plates, and was in its lower part converted into a rigid cylinder. The kidneys were small, one weighing two ounces and three quarters, and the other one ounce and a quarter. The former one appeared healthy under the microscope, but the Malpighian bodies and other ultimate structures of the latter were generally and extremely atrophied. All the other abdominal viscera were healthy.

Dr. Bristowe, *7th of December*, 1858.

---

3. *Small Aneurysm in the substance of the Cerebellum; Gout; Renal Disease; Emphysema of the Lungs, &c.*

The following case is recorded with a view to illustrate the immediate cause of cerebral apoplexy. There can be no doubt that, had no other sufficient cause of death been in operation, this patient's life would still ere long have been cut short by rupture of the aneurysm and consequent sanguineous effusion. Under these circumstances, however, the existence of the aneurysm would probably have been overlooked; a consideration which leads one to the suspicion that such a condition of the smaller cerebral vessels may be present, yet undetected in many actually apoplectic cases.

J. B., a lighterman, æt. 56, was admitted on the 26th of October, 1858, for an attack of acute rheumatism (gout?). No distinct

account of the previous duration of his illness was obtained. Five days after admission he complained of severe epigastric pain, and had some vomiting. Shortly afterwards he became comatose, and continued so until his death, which took place on the 2nd of November.

Post-mortem examination.—There was a considerable amount of serum both on the surface and in the ventricles of the brain; and much atheromatous and earthy deposit in the arteries at the base and their branches. In the right corpus striatum was a small apoplectic cyst, but in other respects the brain substance appeared healthy. In the substance of the right hemisphere of the cerebellum was accidentally discovered an aneurysm about

WOODCUT 1.

The Fig. represents the aneurysm in the substance of the cerebellum. (Slightly larger than natural.)

twice as large as a grain of wheat; it was irregularly fusiform; its parietes were thickened and hardened with atheromatous and earthy deposit, and it gave off several perfectly ossified branches, each about half a line in diameter. Its anterior extremity was continuous, with a thin-walled healthy vessel, having between one-third and one-half the calibre of the aneurysm

itself, and found to be a branch of the right superior cerebellar artery.

Pericardium healthy. Heart hypertrophied (seventeen ounces) and firmly contracted; valves healthy. A few old pleural adhesions. The lungs were highly emphysematous, and congested and somewhat lacerable behind. The bronchial tubes contained much mucopurulent secretion. Larynx and trachea healthy.

The liver, spleen, pancreas, stomach, small intestines, and supra-renal capsules were healthy. The lower half of the œsophagus was congested and covered by slightly adherent flakes of white false membrane. The mucous membrane of the large intestine presented, upon the edges of its prominent folds, numerous excoriations covered by a little yellowish granular deposit. The kidneys were small, together weighing seven ounces; were smooth but mottled on the surface, contained a few cysts, and were studded with yellow gritty granules. The aorta presented numerous bony plates and patches of atheroma.

Several of the joints were examined and found to contain gouty deposits. Dr. Bristowe, *7th of December*, 1858.

---

4. *Case of Hydatid in the Brain.*

The specimen was removed from H. R., æt. 14, a boy, supposed to be in perfectly good health until the early part of July. He went out early in the morning of an intensely hot day, and was engaged in driving away birds from a field, when, at half-past ten, he suddenly fell down senseless. Consciousness gradually returned, and it was then discovered that he was quite blind.

I saw him for the first time about three weeks afterwards; he was conscious, but dull and heavy. Complained of severe headache; pupils moderately dilated and insensible; no vision with the right eye, but he could occasionally distinguish a large object or a bright light with the left. Hearing not affected; pulse 80, and soft.

In four days he could see with the left eye to the extent of distinguishing the nurse from others around the bed; but he had no vision with the right eye. He had had two bad nights; the next

night he was delirious and violent, and in that state he died the next day—about four weeks after the first attack.

Post-mortem examination.—In the apex of each lung were small quantities of retrograde tubercle; the lungs were otherwise healthy. The liver was large but healthy. In the substance of the posterior and left angle of the organ was a cyst, the size of the fist, which was exactly filled by a solitary hydatid, which was perfectly healthy. Its parietes were thin, pearly, and elastic, and it was filled by transparent colourless fluid. The other viscera were healthy.

The dura mater was less firmly united to the calvaria than usual. Its outer surface was congested and mottled, shreddy, and somewhat pulpy. The calvaria was healthy, but exceedingly thin, so as to be transparent in numerous places; the outer surface was natural, but the inner presented a series of shallow depressions, separated by angular ridges, evidently produced by the long continued pressure of the subjacent convolutions, of which they presented an accurate mould. The surface, also, was congested, rough, and softer than natural. The base of the skull and its dura mater were healthy. There was no sub-arachnoïd fluid, the convolutions being compressed against each other, and against the parietes, so as to obliterate the sulci; the surface was not congested. In the posterior lobe of the left cerebral hemisphere was a hydatid cyst, occupying nearly the whole lobe, which was thus converted into a fluctuating cyst. It had rendered the lobe irregular and lobulated, and increased its dimensions; but the hydatid was covered everywhere by brain substance, although in many situations it was a mere film. The lobulated character seemed to have been produced by the superficial veins acting as ligatures. The cyst was single, about as large as a middling-sized orange, and contained two hydatids, one nearly as large as the cyst itself, the other the size of a walnut. They contained no secondary cysts; the brain in all other respects was healthy.

Dr. Barker, *7th of December*, 1858.

---

5. *Case of red softening of the central portions of the Brain, produced by Syphilitic Disease of the Bones of the Cranium.*

S. C., æt. 42, a farmer, with all the indications of having been a peculiarly muscular and well-developed man, was admitted into the Lock Hospital on the 2nd of October, 1858. Six years previously he had a chancre, which healed in about three weeks, under the use of mercurial frictions. About a month after he considered himself quite well he "caught cold," and his left eye became inflamed. He experienced also pain at the back of the head, for which leeches were applied. The inflammation of the eye continued; it became swollen and ultimately "burst." Soon after this some red blotches appeared on his back; these were followed by soreness of the throat and an ulcer on the right leg, which gradually extended over nearly the whole leg. He was now confined to his bed and treated with mercury. Subsequently he was again salivated; and after this he was treated with sarsaparilla and nearly recovered. The ulcer on the leg was reduced to the size of a shilling; it, however, soon again began to increase, and the left leg became similarly affected. Some sores appeared also at this time upon his hands. About two years ago he again nearly recovered, but the sores on the legs never completely healed. Twelve months since some ulcerations appeared on the face; the left nostril became affected, and in the process of cicatrization was completely closed. A portion of bone now came away from the neighbourhood of the right eye. During the time that he was suffering from these various maladies, extensive ulcerations affected the scalp, and portions of bone of various sizes, were at intervals separated. This disease of the bones of the skull appeared to have commenced from the time that he first experienced the pain at the back of his head, and to have continued till the last.

Towards the end of October the ulcerations on the right side of the scalp extended rapidly, and the surrounding skin was affected with erysipelatous redness. His intellect, which from his first admission to the Hospital, had been dull, was now farther impaired, and it was with difficulty that he could be made to answer any question. On the 4th of November he became slightly

delirious and paralytic on the whole of the left side, including the face. He died on the 12th of November.

On *post-mortem examination* a considerable portion of the skull was found deficient at the upper part; but the dura mater here extended across the opening, and no marks of recent disease were visible.

The right parietal and right side of the frontal bones were extensively affected with caries, and in one part the internal table of the parietal was necrosed for a space equal to that of a shilling. The upper part of the occipital bone was likewise carious, and its internal table worm-eaten in appearance. The *dura mater* corresponding to the diseased portions of the frontal and parietal bones, was covered, in two distinct situations, by a tenacious brown

WOODCUT 2.

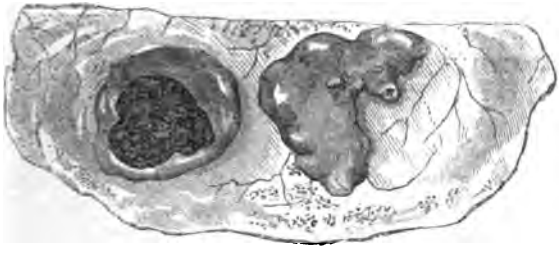

Represents the brown effused patches on the dura-mater, half the size of nature.

semi-fluid effusion, one or two lines in thickness, and occupying from one to two square inches in extent. The arachnoïd on its opposed surfaces was covered by a similar effusion, the outlines of which accurately corresponded with those upon the dura mater. Upon the removal of the arachnoïd the brain beneath was found of a greenish slate-colour; this affection of the brain was confined to the parts covered by the diseased membranes.

On making a section through the *centrum ovale minus*, two distinct patches of a greenish-slate discoloration were seen near its central part. These corresponded and were continuous with the discolorations upon the surface; the affected portions of brain were softer than the rest. On slicing the right hemisphere, on a level with the *centrum ovale majus*, a very peculiar bloodshot

appearance presented itself. (Plate I.) This was most remarkable in those parts which corresponded with the discoloured portions above described; it consisted of a vast number of small circumscribed red patches, a line or two in diameter, which contrasted in a marked manner with the intervening perfectly white cerebral substance. The *corpus striatum* was, perhaps, a little softer on this than on the opposite side.

Corresponding with the disease in the occipital bone the posterior lobe of the left hemisphere presented on its surface the same greenish slate-colour as on the opposite side. The discoloration here occupied the space of a walnut and was softened down in its centre to the consistence of cream. When the membranes of the brain were removed a portion of this softened substance flowed out, leaving a kind of cavity in the posterior lobe of this side of the brain. The other portions of the brain were remarkably distinct, firm, and healthy. The left optic nerve was considerably diminished in size and of a greyish appearance.

Remarks.—It may reasonably be asked, whether this case should strictly be regarded as one of syphilitic disease affecting the brain? It is evident that the disease commenced in the bones of the skull, and spread from thence through the membranes by continuity of action to the brain itself, and it is remarkable that where the bone had been entirely removed no disease of the brain manifested itself. From the history of the case, however, it appears that the affection in the occipital bone commenced at a very early period, and after the patient had used one short course only of mercurial frictions. The formidable disease which supervened would, therefore, scarcely be attributed to the mercury alone. It must also be noted that the softening of the brain had made the greatest progress opposite that part where the pain was first experienced. With this disease of the brain, and the consequent defective nervous influence, may probably be associated the destructive inflammation of the eye and nostril of the same side.

Mr. Henry Lee, 21*st of December*, 1858.

---

6. *Fibrous Tumour of the Dura Mater.*

This tumour, of about the size of a nut, was found on the

DESCRIPTION OF PLATE I.

The Figure illustrates Mr. Henry Lee's case of Red Softening of the Brain, p. 10.

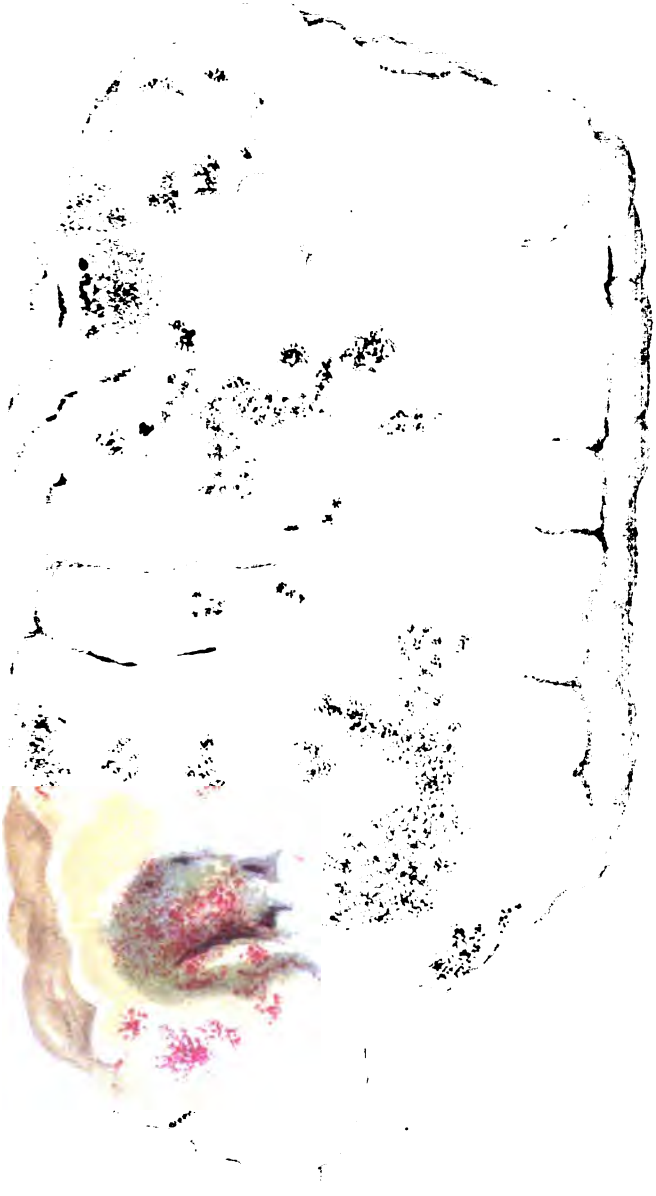

internal surface of the dura mater, opposite the parietal protuberance on the right side, in a female subject, in the dissecting-room of the Westminster Hospital. The arachnoïd was reflected over the tumour, which had produced a considerable indentation on the surface of the convolutions of the cerebrum. The tumour was fibrous, with a small deposit of bone in its centre, and nothing abnormal was found in the brain, except a somewhat increased vascularity. Having made inquiries as to the previous history of the case, I received the following particulars from Mr. Dover, who had had the woman under his charge in the Kensington Union.

"M. L., æt. 99, so long as I have known her, a period of five years, has been insane and subject to violent paroxysms—amounting at times to mania. In the intervals of these fits she was cheerful, took her food well, and appeared much the same as persons at her advanced age usually do. A few days before her death she had one of these fits, then sank into a comatose state and died." Mr. CHRISTOPHER HEATH, 18*th of January*, 1859.

---

7. *Fatal Epilepsy, resulting from Superficial Cerebral Hæmorrhagic Effusions.*

The following case presents several points of interest. During life, from the absence of historical details, it was necessarily very obscure, furnishing merely an example of fatal epilepsy. But after death, much of this obscurity was cleared away: for pathology revealed not only the immediate cause of the convulsive attacks, but indicated pretty clearly the successive stages which had finally resulted in the conditions observed at the autopsy.

The immediate cause of epilepsy was a diseased state of the surface of the brain. This condition was clearly the result of by-gone superficial hæmorrhage; and this hæmorrhage, from the position which it occupied, and from the healthy condition of all other parts of the brain and of the arteries, could scarcely have been caused by anything but the "contre-coup" due to a blow or fall on the back of the head. It may perhaps be considered that the absence of all trace of external injury, and of fracture of the skull is fatal to the latter inference. But the objection is not so serious as it at first sight appears; for, not only may fractures of the skull be produced by accident, yet,

without external wound, but such laceration even of the surface of the brain by contre-coup as I assume to have occurred in the following case, may certainly result from violence, and prove speedily fatal, as I have myself witnessed, without any visible marks of violence either in the integuments or the calvaria. I need scarcely add, that the history thus indicated almost necessarily implies that the patient must have experienced epileptic attacks prior to that series of them which terminated his existence.

T. D., a man, æt. 43, and in tolerably good condition, was brought to the Hospital in an epileptic fit on the morning of the 8th of February, 1859. He was accompanied by persons with whom he had been lodging for about a fortnight only, and who knew scarcely anything of his previous history. It was stated, however, that he had been a sailor, had worked recently in a white-lead factory, had been drinking much of late, and was not known to have been subject to epileptic attacks. He went to bed the previous night in apparently good health; but in the morning was discovered in an excited state, and with imperfect articulation. He was at once brought off in a cab, and on the way to the Hospital was seized with a violent epileptic fit. Up to three o'clock P.M. he had seven distinct severe epileptic attacks attended by the usual convulsions, and by frothing at the mouth. Between, and subsequent to them, he remained perfectly unconscious, with twitching of the eyes and head to the right side, and occasional twitching in the limbs. Pulse 100. No paralysis—no anasarca. Ordered to have the hair cut short, to take five grains of calomel with a drop of croton oil at once, and again after four hours if needful. In the evening, the fits having ceased, but no further improvement taken place, a blister was applied to the back of the neck, and mercurial inunction was ordered.

February the 9th, one P.M. Has had no return of the fits. Became this morning sufficiently sensible to ask for drink; and even now, though he has relapsed again, attempts to reply when roused. He lies on his back; his respirations are rapid and attended by a loud rattle in the throat. Pulse 124. Skin bathed in perspiration. Limbs twitch occasionally. The left pupil is more dilated than the right, and neither of them acts distinctly under the influence of light. The bowels were

thoroughly well opened by the pills; the urine passes, as it has done all along, unconsciously. Ordered two glasses of wine.

He gradually sunk and died at four P.M.

Post-mortem examination.—Calvaria and dura mater healthy. There was no fracture, and no trace of injury. There was a moderate amount of sub-arachnoïd fluid; and the pia mater was generally congested. On endeavouring to remove the brain, its anterior lobes were found to be adherent to the orbitar plates of the frontal bone. The adherent portions, together with many other patches on the surface of the anterior and middle cerebral lobes, were diseased. They had a pale ochrey tint, and appeared to consist of an accumulation of delicate areolar tissue infiltrated with serum, and sufficiently abundant to conceal the surface of the brain itself, and to mask its convoluted character. They did not project beyond the general level, and on section were found to extend, in proportion generally to their superficial extent, from a line or two to half an inch in depth, the brain structure itself being correspondingly removed. A vertical section shewed that the diseased tracts consisted of delicate succulent areolar tissue, the deep surface of which blended insensibly with the subjacent brain structure. A patch, two or three square inches in extent, occupied the anterior angle and under surface of each anterior cerebral lobe, involving the anterior half of each olfactory nerve. A similar but somewhat smaller patch occupied the anterior and under part of each middle cerebral lobe, and numerous patches from the size of a fourpenny-piece downwards, were irregularly scattered over the remaining portions of the under and lateral surfaces of the anterior half of the cerebrum—somewhat more abundantly, however, on the left than on the right side. No nerves besides the olfactory were affected. The vessels at the base of the brain were healthy. There were no clots or remains of clots in any part of the interior of the organ.

On *microscopical examination*, the cellular tissue forming the diseased tracts was found to consist of delicate fibrillated material, with numerous blood-vessels like those of the brain; and towards the deeper part presented a few scattered brain-cells and nerve-tubules. Mixed with these were numerous orange-coloured granules and granular cells, to which the buff

colour was apparently due; but no crystals. The patches were evidently the remains of superficial hæmorrhagic effusions, which from their position had in all probability been caused, on the principle of contre-coup, by an injury inflicted on the back of the head some considerable time prior to death.

Lungs somewhat congested. Heart healthy, contracted; kidneys healthy. There was no disease of any other organ.

Dr. Bristowe, *15th of February*, 1859.

---

8. *Abscess in the Pons Varolii.*

The case occurred under the immediate care of Dr. Down, in a male idiot, æt. 20, at the Asylum, Earlswood. Four years since he was noticed to have purulent discharge from the right ear, which continued to within about four months of his death. His carriage was always remarkably stiff, and he kept his head and upper extremities fixed in every movement of his body. On the 22nd of December his neck was observed by an attendant to be rigidly bent back and his mouth forcibly closed; no loss of sensibility or power of voluntary motion in his arms and legs existed. On the following day his head was still more violently bent backwards, and the whole of the spine, although not to such an extent, had become implicated in the curve. The sterno-mastoïd muscles were relaxed, and he had some rotatory power of the head. Any attempt to draw the head forwards elicited expressions of great pain. He partook freely of bread-and-milk, and was very eager for fluids. In the evening the curve of the neck had so increased that the thyroïd cartilage seemed as though it would burst through the integuments; and at seven o'clock he became, although anxious for food, quite unable to swallow it. On the following day, he became suddenly asphyxiated and died, the symptoms generally having become aggravated. His craving for drink became excessive, and there was no embarrassment of breathing until his last moments.

On *post-mortem examination*, twenty-four hours after death.—Dr. Down found an abscess in the pons Varolii about the size of a walnut. The anterior wall had given way at its lower part, and the matter had found its way beneath the pia mater, below both

hemispheres of the cerebellum, along the surface of the medulla oblongata, and down the anterior surface of the cord as far as the fourth spinal nerve. "Does not the order of the organs involved," writes Dr. Down, "satisfactorily explain the succession of symptoms:—1st, the backward curve of the neck and back; 2ndly, dysphagia; and lastly, asphyxia?" There was no disease of the cranium. Mr. GAY, *2nd of March*, 1859.

---

9. *Brain of an Idiotic Boy nearly Eleven Years of age.*

The subject of this case, was the fourth child of his parents, and was born at the full period, but was then scarcely half the size of their other children. His head was very small, the anterior fontanelle closed, and the surface of the body generally very dark coloured. For the first six months he throve fairly, but the discoloration of the surface continued; he cut the lower incisor teeth about this time, and was then first seized with severe convulsions, but they had previously found that that he was blind. After the attack of convulsions, he fell off, and his head did not appear to increase in size after the expiration of the first year. He was never able to support himself without assistance, he cried or moaned incessantly, and required to be constantly carried in the arms; he was never able to utter any articulate sound, and suffered from severe convulsions at frequent intervals. The first set of teeth were cut naturally, except the second grinders, which did not appear till he was about 7 years old. When about 5 years old, he was found one morning quite comatose and with the left arm paralyzed; and the limb was ever after entirely powerless. After this period the convulsive attacks occurred less frequently, generally about two or three times in the year; when in them, the right side of the face, the right arm and leg, and occasionally, also, the left leg, were convulsed, but the left arm was not affected. The surface of the body continued very livid, the extremities were cold, and he was subject to chilblains. His intelligence was extremely imperfect, he knew his father and mother and the servant who attended to him, and manifested by laughing or crying his pleasure at their presence; he was conscious of their being

pleased or dissatisfied with him, and was affected accordingly; he was apparently affectionate. Though he was incapable of distinguishing objects, his mother thought he was conscious of light and that his attention was attracted by bright objects. His taste was natural, and his hearing and the sensation of the body generally were *unusually* acute. His mother was not able to ascertain whether he had the sense of smell. His appetite was generally good but he could only swallow food which was cut very small, and he occasionally vomited what he had taken. He passed his evacuations in bed, but this was from inability to be taught otherwise, not from want of power to retain them. He could not support himself in any position and lay continually on his side, and especially on the left side. He could not hold anything in his hand, though he sometimes endeavoured to grasp objects, and if he succeeded in doing so, had equal difficulty in relaxing his hold.

For the last two years he was less intelligent and more powerless than he had previously been, and he had latterly become very thin. The spine was arched forwards, the neck very short, and his chin rested upon the breast; the ribs were flattened, the sternum prominent and the abdomen tumid; the arms were drawn towards the front of the chest, the wrists flexed upon the forearms and the fingers clenched. The thighs were drawn up to the abdomen, the knees bent, and the feet were turned inwards. The scalp was covered with thick coarse hair, and the head was of very small size, the forehead retreating rapidly from the orbits; the sides were flattened and there was a sharp ridge along the course of the sagittal section; there was no marked inequality between the two sides. The eyes were very prominent and were in constant motion; the mouth was large, the lips thick and the saliva dribbled from the mouth. The mother considers that in the latter years of the boy's life the head decidedly decreased in size. Towards the end of January, 1859, he took scarlet fever and the disease was ushered in with severe convulsions, he died exhausted in about ten days, when nearly 11 years of age. About three years before his death, his thigh was fractured as it was supposed by a slight fall, and the lividity of the surface continued during his whole life.

The parents of the child, and the mother in particular, were

unusually intelligent, and all their other children were healthy; nor was any other member of the family known to have suffered from cerebral disease or defect. The mother ascribed the condition of this child to a severe shock which she received about the fifth month of her pregnancy from witnessing the sudden death of another of her children by convulsions; she quickened at the time, but did not increase in size afterwards.

The body was greatly emaciated and weighed only twenty-one pounds and a half, avoirdupois. Another child, a girl, æt. 8, weighed forty-two pounds.

The heart weighed two ounces eleven drachms and a-half, and was quite healthy, except that the right auricle and ventricle, and the pulmonary orifice and artery, more especially the latter, were considerably dilated. The lungs were very small, much congested and sparingly crepitant, and had apparently never been fully expanded. The liver was large and fatty; the gall bladder distended with a colourless viscid fluid which could not be made to pass through the cystic duct, though that passage allowed of air being blown through it. The hepatic and common ducts were natural. The kidneys were large, congested and softened.

The calvarium was in some parts translucent, and varied in thickness from one-twelfth to one-tenth of an English inch, the sutures were completely ossified. The dura mater was loosely adherent to the skull, and much fluid escaped on the sac being laid open. The anterior portion of the falx was entirely wanting. The hemispheres adhered firmly along the whole course of the longitudinal fissure, and the membranes were considerably thickened, and opaque on the right side towards the posterior part. The convolutions were unusually small and especially on the right side and posteriorly; the substance of the brain when recent was moderately firm and not unduly congested.

The brain, on closer examination, in which I was obligingly assisted by Mr. Rainey, presented the following peculiarities:—

1. The whole encephalon was of small size, having weighed only twenty-one ounces three drachms and a half, avoirdupois.

The average weight of the brain of male children of similar age, as ascertained from seven observations (six collected by Dr.

Reid,* and one by myself †) of boys from 7 to 9 years of age inclusive, is 46 ounces 6.28 drachms. The heaviest of the number weighed fifty-two ounces fourteen drachms, the lightest forty ounces twelve drachms. Estimated by this standard, therefore, the encephalon of the idiot child was considerably less than half the average size of the healthy brain at the same age; and not much more than half the size of the smallest healthy brain. Indeed, it does not appear to have been as large as the brains of ordinary children of about nine months old.‡

The proportion of the weight of the brain to that of the body was as 1 to 16.2, which, considering the great emaciation, indicates equally the very small size of the brain. In three of the seven cases above referred to, the proportion was as one to seven, one to twelve, and one to fifteen, according to the degree of emaciation of the subjects.

2. The cerebral hemispheres were especially small relatively to the cerebellum, and the cerebellar lobes in consequence projected considerably beyond the posterior lobes of the cerebrum.

The cerebrum weighed seventeen ounces two drachms and a-quarter, and the cerebellum with the pons Varolii and medulla oblongata, four ounces one drachm and a-quarter.

Of the seven healthy brains, the average weight of the cerebrum was 40 ounces 10.4 drachms; the heaviest weighed forty-seven ounces three drachms, and the lightest weighed thirty-six ounces two drachms. The cerebellum with the pons Varolii and medulla oblongata weighed on the average, 5 ounces 11.8 drachms; and the lightest weighed four ounces ten drachms. While, therefore, in the idiot child the cerebellum with the pons Varolii and medulla oblongata was about a fourth less than natural, the cerebral hemispheres were considerably less than half their natural size; or, while in the idiot, the proportion of the cerebellum with the pons and medulla was to the cerebrum as 1 to 4.2, in the healthy sub-

* London and Edinburgh Monthly Journal of Medical Science, 1843.

† London Journal of Medicine, 1851. Dr. Boyd estimates the average weight of the male brain between 5 and 10 years of age, at 41.69 ounces. Appendix to Wagner's Physiology, by Willis, 1844.

‡ In Dr. Reid's tables, a female child aged nine months, and in Dr. Sims' tables (Med. Chir. Trans., Vol. 21, 1833 to '35), two children of the same age had brains weighing twenty-seven ounces eight drachms, twenty-five ounces, and twenty-six ounces.

DESCRIPTION OF PLATE II.

The Figure represents the upper surface of the Brain, of the natural size, in Dr. Peacock's case of Idiotcy, p. 19.

The small size of the whole cerebrum, the irregular development of the cerebral convolutions, the more extensive atrophy of the right hemisphere, and the consequent projection of the cerebellum beyond the cerebrum, are well shown. The latter condition was even more marked than is represented by the Figure.

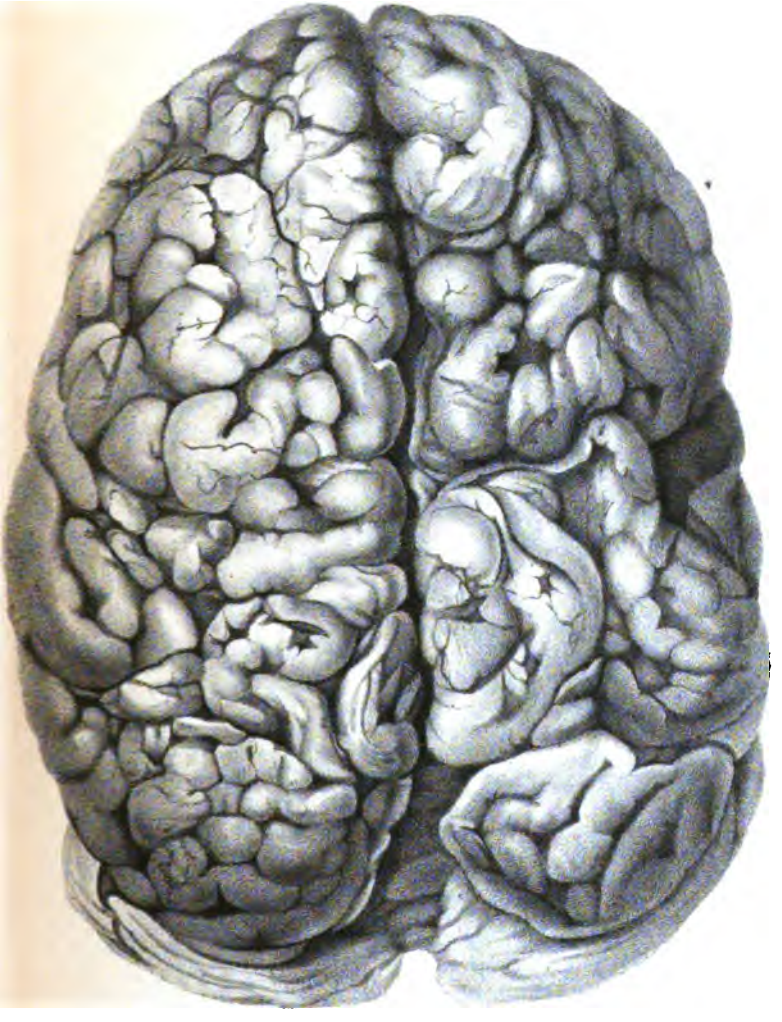

Tuffier West del. et lith. ad nat.

W West imp

DESCRIPTION OF PLATE III.

The Figure represents a Section through the Lateral Ventricles of the Cerebrum in Dr. Peacock's case of Idiotcy, p. 19.

The lateral ventricles, and especially their cornua, are shown very greatly dilated, and the dilatation is the most marked on the right side. There are also indications of sulci apparently obliterated.

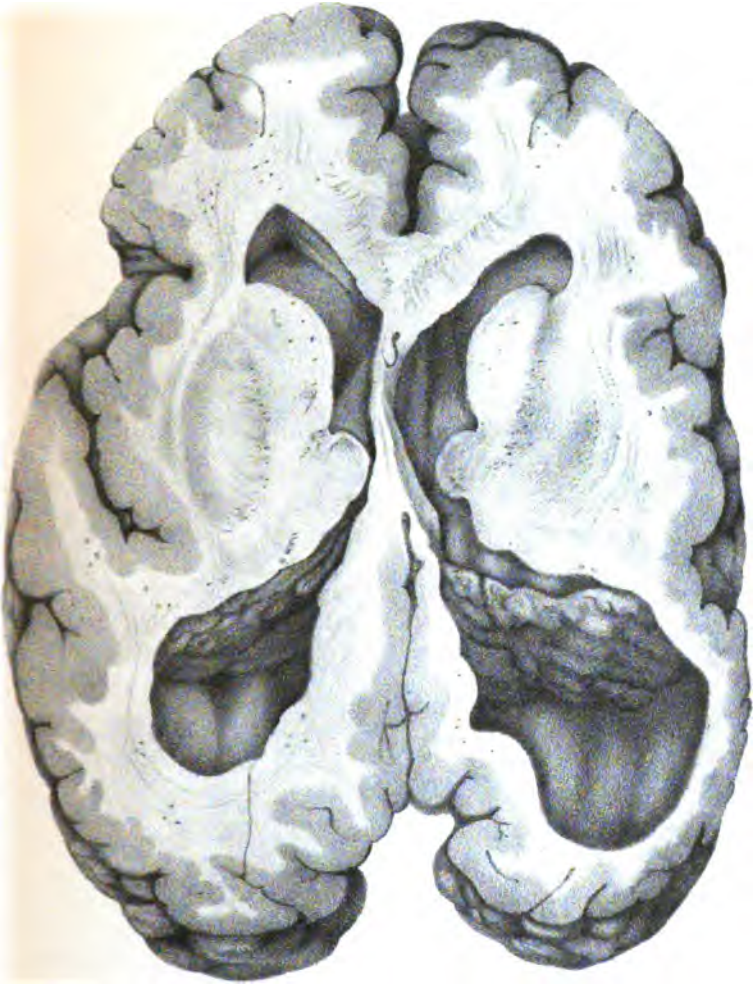

Chas West del et lith ad nat

W West imp

jects, at a similar period of life, the cerebellum, etc., was to the cerebrum as 1 to 7.8.

3. The convolutions on the surface of the hemispheres were very small (Plate II.), and the sulci shallow, and on section (Plate III.), the surface presented indications of sulci which had apparently become obliterated. The lateral ventricles, and especially their posterior cornua, were very greatly dilated and distended with clear serum, of which fully three ounces escaped.

4. The right cerebral hemisphere was much less than the left; the convolutions on the surface, and especially of the posterior lobe, were smaller and much separated, and the corresponding lateral ventricle was much larger than the left.

The following were the dimensions of the two hemispheres. Width measured on the upper surface of the

Anterior lobe, right side	1 Fr. in.	and 6½	lines.
,, left ,, ...	1 ,,	9	,,
Middle lobe, right ,, ...	1 ,,	8	,,
,, left ,, ...	2 ,,	3	,,
Posterior lobe, right ,, ...	1 ,,	10	,,
,, left ,, ...	2 ,,	1	,,
Height of the vertex, right side ..	1 ,,	9	,,
,, ,, left ,, ..	2 ,,	1	,,
Length of hemispheres, measured along the upper surface :—			
right side ..	6 ,,	4	,,
left ,, ..	6 ,,	11	,,

The right lobe of the cerebellum was slightly narrower than the left.

5. The optic tract was wanting at the part where it passes over the crus cerebri on each side, while the optic nerves, the commissure, the anterior portion of the tract, and the corpora geniculata and quadrigemina were fully in proportion to the size of the brain. The corpus callosum, the fornix, the corpora striata, and thalami, the anterior, posterior, and soft commissures, and the pineal gland with its peduncles, were also in full proportion to the rest of the organ. The grey matter on the surface of the convolutions appeared natural, and the different nerves, originating from the brain were fully developed.

6. The pons Varolii and the medulla oblongata, with the

pyramidal, olivary, and restiform bodies, were well marked. The spinal cord was small; deprived of its nerves, it weighed only five drachms, and measured seven inches in length. It was decidedly soft, but probably only from decomposition.

7. The specific gravity of the whole brain estimated by weighing in air and in water was 1030. The specific gravity of the healthy brain of a boy, æt. 11, similarly estimated, was 1039.6.

Remarks—The above case is interesting;—1. From the confirmation which it affords of the theory which ascribes the production of cyanosis to congestion of the venous system. The child was first sent to me by my friend and then colleague—Mr. Gay, when about a year old, under the suspicion that it laboured under some defect in the conformation of the heart, and such was my own idea. It will, however, be observed, that the heart was well formed and healthy; but from the dilatation of the right cavities and the condition of the lungs, there had, doubtless, been permanent congestion of the venous system.

2. It affords a remarkable instance of imperfect development of the brain, the "agenesia cerebralis" of Breschet, and "microcephalia" of other authors. Similar cases of defective development have been recorded, Otto,* Jadelot and Andral,† Cruveilhier,‡ especially Cazauvieilh,§ but the weight of the brain is not given in any of the cases related by these writers. Dr. Todd has, however, placed on record the dissection of the brain of an adult idiot, in which, after being several days in spirits, the organ weighed twenty ounces and a quarter, avoirdupois.‖ Dr. Tuke mentions that the lightest brain, recorded by Solly, weighed nineteen ounces and three quarters; and he has himself related the case of an idiotic lady, who died at the age of 70, at the Friend's Retreat, York, whose brain weighed twenty-two ounces and three quarters.¶ Dr. Bucknill** gives the weight of the brain in an adult idiotic

* Pathological Anatomy by South.

† Clinique Medicale, and Path. Anat.

‡ Anat. Pathol., Liv. 5 and 16.

§ Arch. Gen. de Med., 5me annee, t. XIV., 1827, p. 5 and 347.

‖ Cyclop. of Anat. and Phys., Vol. III., p. 718.

¶ Psychological Medicine, 1858, p. 98.

** Brit. and For. Med. Chir. Rev., Vol. XV., 1855, p. 216-217.

female as thirty-two ounces and a half, and Dr. Boyd* found the brain of an adult male epileptic to weigh thirty ounces, and that of an adult female thirty-one ounces.

3. The description of the case during life corresponds with the symptoms generally observed where the development of the brain is materially defective. The complete idiotcy, the frequent epileptic paroxysms, the defect of muscular power, the contraction of the limbs, and the imperfect growth of the different parts of the body, are characteristic of the condition of the cerebral hemispheres—the deficiency of the tractus opticus in one portion of its course equally explains the defect in vision—and the greater imperfection of the right cerebral hemisphere corresponds with the paralysis of the left arm. It rarely happens that, when the nervous system is so imperfectly developed as in the present case, the patient survives for many years; but when the defect is less marked, life may be prolonged to the average or even to the full period. Dr. PEACOCK, *2nd of March*, 1859.

---

10. *Syphilitic (?) Disease of the Brain and Liver; with Obstruction by clots of Cerebral Arteries.*

G. H., æt. 34, a steam-packet engineer, was admitted on the 4th of January, 1859. Some years ago, while at his employment he was seized with a fit, during which he was insensible, and from which he speedily recovered. Eighteen months since he had a second fit, which lasted for two hours; he was insensible, had slight frothing at the mouth, but did not bite his tongue. No loss of power or speech followed either of these seizures; and he pursued his employment, although after the second one he became subject to attacks of headache and vertigo, accompanied by hysterical symptoms. During the last three weeks, he is said to have suffered from rheumatism. He had a third fit eleven days ago, attended by slight frothing at the mouth, and followed by partial hemiplegia on the left side, with indistinctness of speech.

He is pale, sallow, childish or somewhat fatuous, and varies in his statements. There is considerable weakness in the left side, and his speech is thick. He has pain in the forepart of

* Med. Chir. Trans., Vol. XXXIX., 1856, p. 59.

the head, and impaired vision; the pupils are much dilated. Tongue clean and moist; appetite poor; bowels somewhat costive; he has perfect control over both bladder and rectum.

He continued under treatment until the day of his discharge, the 5th of February, with no decided change in his symptoms. It may be added, that it became apparent that he saw with the left eye much less distinctly than with the right; and that the pulse, which varied between 56 and 85 in the minute, was most commonly about 60.

He was reädmitted on the 22nd of February, in much the same condition as when he left; but he was perhaps more fatuous; he was very troublesome, occasionally spiteful, and on one occasion, threw his fæces at the sister. On the 25th, he passed into a comatose condition, which speedily became complete, and was attended by stertorous breathing and occasional starting of the limbs. He remained thus for twenty-seven hours, and died on the evening of the 26th.

The body was examined two days after death, and appeared to be in pretty good condition. There were the cicatrices of ulcerated buboes in both groins.

On removing the calvaria, the dura mater over the greater part of the upper and lateral part of the left anterior cerebral lobe was found to be thickened, rough, and a little congested—the corresponding surface of bone being 'also rough, congested and slightly softened. The surface of the brain was generally healthy, though a little injected; but the dura mater in the situation before indicated, and in an area of some eight square inches, was firmly adherent to it by means of the intervening layer of fibroïd tissue, in which and partly in the brain itself were embedded two or three tough opaque-white fibrinous masses, from the size of a hazel-nut downwards. The brain substance corresponding to the adhesions was to some little depth softer than natural; and in places the grey-matter had wholly disappeared. In the anterior part of the left corpus striatum was an imperfect cyst, apparently apoplectic, and about as large as a hazel-nut. The anterior half of the right corpus striatum was congested and much softened. The rest of the brain substance was somewhat injected, but otherwise healthy. The lateral ventricles contained only a small

amount of serum. The vessels at the base and their contents were generally healthy; but the left internal carotid and its branches, for a length of about an inch, presented externally a buff-colour and looked atheromatous. On slitting them up, however, they were found obliterated by adherent cylinders of tough old coagulum.

Pericardium and heart healthy. Pleuræ and lungs healthy. The bronchial tubes contained a good deal of vomited material. Larynx and trachea healthy; except that the left side of the epiglottis was irregularly crenate. Yet there was no distinct evidence of ulceration.

The liver was attached to the diaphragm by numerous old adhesions—the adhesions corresponding for the most part to fissures on the surface of the organ. It was of usual size, and generally healthy; but presented numerous fissures, more or less deep, corresponding to cicatrix-like formations of fibroïd tissue in the subjacent liver-structure, embedded in some of which were small fibrinous masses or knotty tumours. Spleen of usual size, pulpy, with distinct Malpighian bodies. The remaining abdominal viscera were healthy.

Under the microscope the fibrinous masses connected with the brain were found to consist of imperfect fibrillated tissue, with large numbers of nuclear bodies and much granular matter.

The above case was exhibited chiefly in reference to syphilitic disease of internal organs, a subject which has been several times brought under the notice of the Society by Dr. Wilks and other observers. The kind of deposit supposed to result from the syphilitic poison was recognised both in the liver and in the brain, and was associated with scars of what were, doubtless, venereal buboes in both groins. The history of the case shows that the disease had crept on insidiously, and therefore to some extent confirms the view of its syphilitic nature. It is true that no written record exists of the patient having ever laboured under venereal disease; but that is not remarkable when it is borne in mind that it was never suspected while under treatment that his symptoms were in any way connected with that disorder, and that his previous history was obtained from his wife, who was not very likely to volunteer a statement to that effect, even if she had been justified, by a know-

ledge of the fact, in doing so. It is worthy of remark that the chief disease of the brain was on the same side as the hemiplegia.

Dr. Bristowe, *2nd of March*, 1859.

---

11. *Two cases of Cholesteatomatous Tumour of the Brain.*

These cases were sent to me by Dr. Tyerman, of the Colney Hatch Lunatic Asylum, to be recorded in the Society's Transactions, for the purpose especially of discovering, when a sufficient number of instances shall have been collected, whether there be any truth in the belief that this class of tumours occurs only or more frequently in the insane. If such be the fact, it will be very remarkable, seeing that as a rule, tumours in the brain are the cause of the nervous symptoms with which they are associated, and are met with in general hospitals, while the cholesteatomatous spring up in connection with brains previously diseased, and are found only in lunatic asylums. The first case recorded is the one alluded to by Busk in his translation of Wedl's Pathology, where also he refers to this opinion of their occurrence in the insane.

Case 1.—T. H., æt. 26, a shoemaker, was first admitted into Guy's Hospital, where he appeared fatuous; he spoke thickly, with tremor, and he had general loss of power, so that he moved with difficulty, and he complained of pain at the back of the head. He soon became quite maniacal and unmanageable, and was admitted into Colney Hatch Asylum. He was there described as suffering from general paralysis, the articulation was much impeded, facial nerve partially paralyzed, so that he was scarcely intelligible when attempting to speak. He was labouring under various delusions about himself. He continued in the Asylum for fifteen months; he was able to move about by laying hold of the chairs and other objects in the room; he was quiet, though scarcely able to use intelligible language;—he never had any fits. He at last took to his bed and died tranquilly.

After death, there was found at the base of the brain, on the right side, a tumour of the size of a pigeon's egg, and weighing about ten drachms; a portion of this was sent me at the time, and

found to be cholesteatomatous, consisting of delicate polyhedral or oval cells, and cholestearine crystals; it was enveloped in a cyst of pearly glistening whiteness. The tumour made a bed for itself by compressing and producing atrophy of the right side of the pons Varolii, and a portion of the right lobe of the cerebellum, and insinuated itself between the middle and anterior lobe, in fissura Sylvii. The pons was pushed on one side and not absorbed. The brain otherwise was not diseased, but the ventricles contained much fluid. The spinal cord was softened.

Case 2.—This was a case of Mr. Marshall's.

A woman æt. 35, had been several years epileptic, and was very violent at intervals, besides being prone to suicide; she was sallow and unhealthy-looking, and very difficult of management. It was observed that she had numbness of the side of the face on which the tumour was found, and dilatation of the opposite pupil.

On *post-mortem examination*, February 1859, there was found a cholesteatomatous tumour at the base of the brain; situated on the middle lobe of the right side, and encroaching on the pons and tractus opticus, causing partial absorption of those structures and complete absorption of the fifth, seventh, eighth, and third nerves at their origin. It was not attached to the arachnoïd, but lay loose between it and the brain, having no manifest attachment. It was the size of a chestnut.

The structure of these tumours is very simple and has been described in a former volume. As regards the especial point of interest—their occurrence in the insane—not sufficient cases are recorded to arrive at any positive conclusion. In our Transactions, one is described without a history, another came from a lunatic, and in a third case, described by Mr. Sibley, the adventitious structure in the brain was only partly cholesteatomatous, it was situated on the anterior surface, and appeared to have resulted from a blow. Cruveilhier, in his Pathological Anatomy, gives a plate containing three such tumours, which he styles pearly, and which, very remarkably, are situated at the base of the brain, just as in those instances which I have mentioned; the histories of his cases are imperfect or altogether wanting, excepting in the one

instance, which came under his own notice in La Charité; the subject of it was a girl who had no paralysis, but for some months had lost her reason.

I might also allude to the interesting fact of tumours growing in the membranes of the brain, which exactly correspond to the contents of ordinary sebaceous cysts, and also that several specimens have been brought before the Society of other cerebral tumours which resembled ordinary epithelial cancer.

Dr. WILKS, *2nd of March*, 1859.

---

12. *An Encephaloïd Tumour attached to the Cerebellum of a Child.*

F. W., æt. 3 years and 9 months, son of German parents, of fair complexion and light hair, was brought to me at the Hospital for Sick Children, on the 28th of February. He had been suffering for a month previously with obstinate vomiting, for which he had been treated at a Dispensary without any relief. This was the only symptom to be detected at that time. Various remedies were tried but with very slight relief of the sickness. There was no headache, no dimness of sight, and no alteration in the action of the pupils.

The sickness appeared to be independent of the times of taking food, coming on almost as often when the stomach was empty as when it was full. On the 10th of March, two or three attacks of convulsions occurred in which the arms were stretched out, the hands flexed, but not very rigidly so, and consciousness appeared to be absent; there was little or no action in the muscles of the face, and no lividity of the face. From this time the convulsive attacks, with rigidity of the limbs, became more frequent, and the sickness still more troublesome. There was still no headache, no heat of head or any symptoms, except the sickness, which pointed to the head, but there was frequent spasmodic pain at the pit of the stomach. His mother found that the fits were less frequent when he could vomit, than when he was unable to do so.

On the 25rd of March, from one to ten A. M., he was in a constant succession of convulsive attacks accompanied by screaming, and (for the first time) complaints of pain in the head. He died at half-past ten o'clock.

On the 22nd of March I saw him, and found him conscious, seeing and hearing and smelling well. The pupils were dilated and indolent on the approach of light. The vomiting was incessant.

Post-mortem examination.—Body emaciated. Head large. The hemispheres of the brain were moderately injected. The lateral ventricles contained a few ounces of clear fluid. There was no softening of the central portions of the cerebrum, and no tubercle was discovered at the base of the brain.

After removing the encephalon from the skull there was found attached to the membranes of the underpart of the left cerebellar lobe, and indenting but not embedded in the cerebellum, a roundish lobulated mass about the size of a large walnut. It was separable from the cerebellum with moderate facility. Its exact relations to the cerebellum were not so well ascertained as could have been wished in consequence of its not being noticed till several slices had been made in the cerebellum. It was enclosed in a thin distinct membranous capsule. On section it presented the usual naked eye characters of encephaloïd cancer. On pressure a considerable quantity of creamy juice exuded.

On *microscopical examination*, the juice was found to present numerous round nuclei with distinct nucleoli, also a considerable number of delicate finely shaded round cells, with large well defined nucleolated nuclei. The substance of the tumour appeared to be made up of similar cells. The cells varied in size from $\frac{1}{3000}$ to $\frac{1}{1500}$ of an inch in diameter; the average diameter of the nuclei was $\frac{1}{4000}$ of an inch. There were also some larger granular cells in smaller numbers, in some of these were to be seen several nuclei. Other nerve organs healthy, I suppose the constant vomiting must be ascribed to pressure on the pneumogastric nerve. Unfortunately the urine was not examined. After death the mother stated that he had passed a considerable quantity of urine in bed during his illness, and that he always left a white incrustation which made the linen sticky and stiff. After death I could not obtain a drop of urine from the bladder.

Dr. HILLIER, 19*th of April*, 1858.

---

13. *Cases illustrating Disease of the Central and other parts of the Brain as a result of obstruction to the passage of Blood through the Veins and Sinuses of the Cranium.*

CASE 1.—Fibrinous laminated coagulum partly converted into a greenish-yellow puriform fluid within the cranial sinuses. Ulceration of the dura mater connected with disease of the internal ear following scarlet fever. Abscesses of the brain. Strabismus and facial paralysis following a general spasmodic state of the muscles of the limbs.

History.—The patient was a woman, C. B., æt. 22, who was brought into St. George's Hospital with febrile symptoms, albuminous urine, leucorrhœa, and sharp pain in the right ear, from which a considerable discharge was flowing. She had had scarlet fever some years previously, and ever since the attack had been the subject of a discharge from the ear. The pain of which she complained had existed about ten days only. After being in the Hospital about two days she was seized with a violent convulsive attack which left her with the mouth and face drawn to the left side, and convergent strabismus of the right eye. It was not certain that she had lost consciousness, and on the same day she was sitting up and reading in bed. She complained, however, of much pain in the head, and was very restless and uneasy in the region of the chest. About a fortnight after her admission into the Hospital she died.

On *post-mortem examination.*—Purulent fluid was found in the right pleural cavity, and one or two collections of pus in the upper part of the right lung, with hepatization of the neighbouring tissue. The spleen was very large, soft, and flabby; the other abdominal organs were natural. On dividing the scalp, much purulent fluid was found beneath the pericranium covering the right temporal region, and at this part on section of the bones of the cranium a considerable amount of pus was met with in the veins of the diploë. Pus was also found between the dura mater and the inner surface of the cranium at the posterior part of the middle cerebral fossa on the right side, and in one place the dura mater itself was in a softened blackened and sloughy condition, being with facility removable from the bone. This condition corresponded with caries of the bony part entering into the composition of the internal ear.

The lateral, and petrosal, and cavernous sinuses on this side were very prominent and hard, and on opening them, were seen to be entirely occupied with firm, not very dark coloured coagulum, which in one part observed a most decidedly laminated disposition resembling the coagulum often met with in aneurysms. (See Woodcut below.) In one spot this coagulum was converted into

WOODCUT 3.

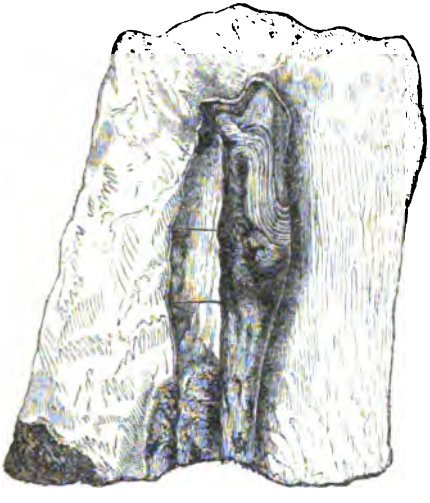

Represents the laminated and partly disintegrated clot from the lateral sinus. (Reduced one-fourth.)

a light-greenish fluid having bright-red clot among it, and presenting a beautiful coloured mass by reason of the bright contrasts of its hues: and in one place a large vein full of dark firm clots, existed near the mastoïd process, penetrating through the cranium from without into the sinus. Moreover, a certain amount of purulent and fibrinous material existed in the arachnoïd cavity of the right middle cerebral fossa; and a portion of the middle cerebral lobe on the side was very vascular, and slightly softened, and on section, was found to contain a collection of purulent matter of about the size of a walnut. The other parts of the brain, and also the cerebellum were healthy.

CASE 2.—Fibrinous coagulum (partly softened and transformed into a puriform discoloured fluid) within the veins and sinuses of the brain. Abscess of the brain. Hemiplegia.

Previous History.—The patient, R. S., æt. 26, was admitted into St. George's Hospital, affected with well-marked pneumonia on the left side of the chest. According to his statement, he had been ill only a few days. Under suitable treatment he got apparently well; but suffered a relapse. From this second attack he was recovering, when he experienced what was called by him a "weakness" of the right eye.

On admission the pulse was very feeble, and the patient was in a very weakened state. He afterwards began to complain of great pain in the head, especially at the back, and subsequently at the left temple, and was treated with wine and requisite stimulants. After being in the Hospital about five weeks, he was unexpectedly found one morning in bed totally unconscious to all around him, and to have lost all power of moving the *left* arm and the *left* leg. He remained for three days in a condition of half stupor, until death took place.

Post-mortem examination.—Showed evidence of considerable and recent pneumonia on both sides (but chiefly the left), of the thorax. In one or two places the lung-tissue had given way, accumulations of purulent matter having formed. On examining the cranium, the following conditions were met with:—The external coverings of the cranial bones, as also the cranium itself, were natural. The external surface also of the dura mater was natural; but on slitting up the sinuses, the superior, longitudinal, and the *left* lateral and *left* petrosal sinuses completely down as far as the commencement of the internal jugular vein, were found to be fully plugged up by firm, and, for the most part, dark, reddish-brown coloured coagulum. This was on the whole, pretty firmly adherent to the walls of the venous sinuses; but in one or two parts had become diffluent, and broken down into a greyish-brown grumous fluid material. Similar brown adherent clot was found to exist in several of the small and large veins passing from the surface of the cerebral convolutions, and empty-

ing into these sinuses; but in none of these was any of the contained coagulum disintegrated or altered as in the sinuses. The right arachnoïd cavity presented nothing note-worthy, excepting that the vessels seen covering the cerebral hemisphere were very gorged; but the left arachnoïd sac contained a considerable amount of mixed, yellowish, purulent fluid, and soft, fibrinous material. This passed down to some extent into the superior longitudinal fissure, but nothing of the kind was found to exist with respect to the spaces or tissues beneath the arachnoïd membrane covering the brain itself. On dividing the brain, it was generally found healthy and tolerably firm; but at the inferior and posterior part of the middle lobe of the left cerebral hemisphere, it was very slightly diminished in consistency, and at the distance of about one-third of an inch from the surface of the organ at this spot, there existed a cavity of the size of a hazel-nut, lined by a soft, fibrinous material, and filled with purulent fluid. The thin stratum of grey brain substance, which separated this collection of pus from the arachnoïd cavity, was somewhat softened, but nothing more. On opening the lateral cerebral ventricles, they were found to contain a large amount of turbid fluid, and here and there portions of yellowish-white, soft, effused fibrine masses, which were in some cases slightly adherent to the walls of the ventricles, and partly connected with the choroïd plexuses. Other parts of the body presented nothing unusual.

Microscopical examination of the rather softened brain mentioned as existing at the base of the middle cerebral lobe, showed the presence of a quantity of granular and refracting matter in several places, the walls of the minute capillaries being beset with fatty particles, and here and there with granular bodies of about the size of pus cells, and occasional ones of a much larger and conglomerate character, and of a dark-grey colour.

The yellowish masses connected with the choroïd plexuses and lining of the ventricles, were found to be covered by a layer of fibrin. These masses were seen under the microscope to contain a large quantity of fat and granular matter, with occasional crystalline particles, and numbers of delicate round cells of the size of pus-corpuscles, with here and there larger cell-like bodies. These bodies on the addition of acetic acid, obviously possessed

a distinct surrounding wall. Very rarely aggregations of refracting and granular particles forming on the large bodies existed.

Commentary on the two preceding cases.

The *first* case of the two is an interesting example of a series of phenomena not infrequently met with after an attack of scarlet fever. The throat affection, attendant upon the scarlet fever, travels, I presume, along the Eustachian tube to the internal ear; suppuration is established there; then caries of the bony surrounding parts, with inflammation and perhaps sloughing of the dura mater investing the petrous element and the temporal bone follow; then, perhaps, arachnitis, and abscess or softening of the brain attended or not by variable degrees of headache, coma, and convulsive symptoms. In most of these cases, if not all, are to be found deposits of fibrinous material in the neighbouring veins and sinuses, either of the diploë, of the surrounding bones, or of the parts external or internal to them. This fibrin is very apt to soften, break down, and undergo various secondary changes.

Such a course of events, of which scarlet fever is the precursor, is not uncommonly met with; but I would at this time particularly make use of the case in question for the purpose of fixing attention upon the connection which I believe to exist between the abscess of the brain and the peculiar condition of the cranial sinuses and veins.

That a substantive relation often obtains between suppurative disease of the inner ear and that of the brain tissue, has long been observed; but I don't remember to have previously seen any surmise that this connection was brought about by the intervention of a plugging up, and it may be other conditions also, of the intervening venous channels. Of course there is no doubt, that very often the connection between this disease of the internal ear (whether or not contingent upon scarlet fever), and the softening or abscess of the brain, has been simply that of an extension of the diseased action, in a direct way, as by contiguity, from the carious temporal bone, the dura mater being inflamed, and it may be, sloughing; then the arachnoïd becoming implicated, and subsequently, one step further, the subjacent brain. This I say may in *many* cases be the order of sequence in the phenomena which occur, but assuredly there are other cases

in which, as I believe, the relationship is of a different kind, being not one of contiguity or direct involvement, but immediate in character.

We know that a sloughing or purulent condition of parts, especially of such as are rigid and inextensible like bone (and this will more manifestly be so in the case of the inner ear, boxed up as it were in the midst of the unyielding petrous bone) is very apt, particularly in debilitated constitutions, to produce what is termed pyhæmia, for which dangerous result no doubt the plugging or sealing up of the neighbouring venous canals is nature's best and readiest remedy. We also well know, that any considerable amount of constriction or infarction of veins, unless, indeed, speedy and extensive corresponding enlargement of collateral venous communications be established, must of necessity produce great congestion and eventually destructive invasion, so to say, of the tissues which such venous channels are delivering from a surcharge of blood,* by reason of the consequent serous and fibrinous exudations, or even effusions of blood from the ultimate commencements of such veins. This extreme congestion, with its consequences so highly detrimental as they are to the integrity of ordinary areolar and other such tissues, leading to induration, suppuration and ulceration, &c., as in the case of varicose veins, is in a manifold way more pernicious in the case of so finely organized a structure as that of the nervous centres; and our surprise need not be excited when we find with what facility it may lead to abscess in this delicate texture. Thus do I believe, that softening and abscess is frequently originated in the brain: and the assumption obtains considerable support and force when we find, as we do in some cases of abscess of the brain or cerebellum connected with disease of the ear, that the temporal bone surrounding the inner ear-cavities, is but slightly affected; or again, when we find that a certain degree or thickness of more or less uninvolved brain tissue intervenes between the contiguous diseased ear or bone, and the cerebral abscess itself. Surely, if mere contiguity or extension of

* It may be not amiss to recall to mind the anatomical fact that the lateral sinuses as a rule receive the blood from the inferior surface of the posterior lobes of the brain and cerebellum; and the cavernous sinuses from the anterior and middle lobes of the brain.

inflammation only were the foundation of the connection, it could hardly be that inter-lying parts, such as a thickness of the brain (at times of no inconsiderable extent), and even the cerebral membranes themselves would, in many cases, continue to be uncomplicated.

But much as I am of opinion that the above is a truthful interpretation of the connection between discase of the internal ear and certain affections of the brain in many cases,* much more do I suppose it to exist in many instances where softening or abscess of the brain with distention and occlusion by fibrinous deposit of the contiguous veins and sinuses co-exist, and where there is *no* disease of the inner ear or cranial bones. In such cases, I believe, first in order occurs the precipitation or deposition of the fibrin from the blood within the veins, and the disintegration of the brain substance takes place as a secondary but direct and immediate consequence,† the sanguineous overcharging of the particular affected portion of the brain, from which the minute and

* In some cases no doubt the connection alluded to is not at all of a vascular nature like the above, nor yet one attributable to a direct extension or propagation from the ear to the brain (*via* the bone and the dura mater, then the arachnoid, and so on to the brain tissue), but I believe it to be established by means of the small process of arachnoid, which all anatomists describe as passing in the form of a tubular sheath, along with the auditory nerve and through the internal auditory foramen into the petrous part of the temporal bone. I have notes of one or two cases which, when recent, appeared to me to be instances of this. This delicate process of arachnoid membrane becomes implicated in the pathological process within the bone and about the internal ear, and so becomes the medium for its travelling inwards and backwards to the general arachnoid cavity. In these cases, perhaps, as a rule, the brain substance would not be so much affected, but the stress of the morbid action would remain with the investing arachnoid.

† By way of illustration, it may be not amiss or uninteresting to recall to mind the evil effects found in certain untoward cases to follow such a plugging up of venous channels in other parts of the body. For instance, it is well known that gangrene at times follows extreme conditions of so-called phlebitis in the limbs, and in phlegmasia dolens it is not by any means a very rare circumstance to have erysipelatous inflammation and the formation of purulent matter in the affected limb, besides, in milder cases, slight local inflammations. An interesting instance is related by Hasse (see the old Sydenham translation of his work, p. 24), as occurring in his own person. In him the whole saphena venous system had become blocked up by fibrin, and, as he says, "*even the minute twigs of the corium had, by the formation of pustules beneath the epidermis, given proof of active participation in the disease.*"

radical veins pass to form tributary streamlets to the larger out-going currents, producing quite as dire effects as does an over diminution of blood-supply (leading to atrophic disintegration), from the plugging up of its corresponding arterial vessels. The one pathological condition I believe to be as prejudicial, although in a completely opposite direction, as the other. And this method of connection between the affection of the brain and the occluded state of the cranial sinuses and veins may happen, of course, whatever may be the cause of the coagulation within the vessels —whether it be of pyhæmic origin, and succeeding to the formation, retention, and perhaps absorption of pus or its dêbris in other and distant parts of the frame (it may be in the viscera, &c., or on the various surfaces), and therefore, no doubt conservative or protective in intention—or whether it be totally independent of such contamination and spontaneous, so to say, depending on some general and inherent cause which induces a tendency to the precipitation of fibrin in the blood-vessels, accompanied or not as the case may be, with similar precipitation in various organs or other parts of the body.* Such a plugging up and obstruction, primarily of the various venous main channels with their larger ramifications, and secondarily, of the more minute radicles is, I am very much disposed to think, from what I have met with on several occasions, much more apt to occur as a result than is generally imagined, and to pass unnoticed when it exists.† The presence of such a condition of the venous outlets is, in my belief, by no means a rare cause of other changes in the brain, than abscess in the vicinity of the inner ear. The softening of the more interior white parts of the brain, and especially of the central white portions such as the fornix, the

* This might well be owing either to a positive or comparative superabundance of fibrin, or to some agency by which the fibrin, natural in amount, might be more easily than usual induced to precipitate; or it might arise from some altered condition of the fibrin itself under which a similar tendency existed.

† I would here allude to the *in*frequency with which the various cranial sinuses are examined in *post-mortem* examinations. The superior longitudinal one should habitually be examined immediately on the removal of the skull-cap, and before the dura mater is divided; and the other sinuses after the removal of the brain. I may be, perhaps, pardoned for here alluding also to a common error often fallen into, and that is the examination of the organs of the chest before that of the cranial contents, a procedure which of course allows, to a great extent, of the emptying of the cranial veins and sinuses.

septum lucidum, and the surfaces of the various ventricles may, under such a supposition, be accounted for in many cases; as our anatomical acquaintance with the venous system of the cranium teaches us, than any plugging up or narrowing of that tolerably capacious channel called "the stright sinus," existing as it does in the middle of the tentorium cerebelli, and discharging itself posteriorly into the "torcular Herophili," would, by reason of the so-called great veins of Galen, which conduct the effete blood returning from the central parts of the great nervous central mass to this sinus, lead to very considerable detention of blood, and consequently to more ultimate injurious change in those central parts before alluded to.

In the last of the above-detailed cases, it might be thought that the abscess of the brain was a phenomenon secondary to the pus-producing alterations in the lungs, to whatever cause they were attributable. It might again be deemed probable that the accumulation of pus in the lung and in the brain were the results of a cause acting commonly on both organs, and disposing to a precipitation of fibrin which underwent softening changes. It appears to me, however, to be equally open to suppose that whether the collection of fibrin in the cranial veins and sinuses had a common origin with similar deposits in the lungs or not, the abscess of the brain was determined, as I have before said, by the plugging up of such small veins as are allotted to the locality affected, and by the consequent retardation and eventually the arrest of the venous circulation in them.

I have in other places * brought forward instances of diseased conditions which appeared to be the result of a spontaneous tendency to precipitation of fibrin from the blood, along with observations on the general question. In one case which I adduced, a very similar state of the cranial veins and sinuses existed to the ones above recorded, but it was unaccompanied by any organic alteration in the substance of the brain itself. Of course, such ultimate changes and results of this venous obliteration, will only result from a blocking up of the venous channel, in proportion to the rapidity with which the resulting embarrassment to the blood's transit is established, and according as the freedom of col-

* Transactions of this Society, Vol. IV., p. 142, and Vol. VI., p. 31.

lateral circulation as permitted by still uninjured veins is maintained. The degree of such freedom permitted will naturally be dependent upon the amount of plugging up of individual veins or sinuses, and upon the number of collateral or anastamosing channels involved in the blocking up, and otherwise likely to act in a compensatory manner.

In addition to the general remarks above called forth by the consideration of these two cases, I would in particular call observation to one or two additional details connected with them. Thus, in Case 1, whilst the disease of the inner ear and of the intra-cranial veins, and the cerebral abscess, were on the *right* side, the loss of power in the muscles of the face and mouth was on the corresponding (the *right*) side. At first sight this paralysis might have been thought to be dependent on the cerebral abscess, and to form one of those exceptional and somewhat enigmatical instances of paralysis resulting from disease of the corresponding side of the brain; but the discharge from the outer ear and the actual destruction of the inner ear, in which, no doubt, the portio dura of the seventh pair of nerves was affected, would serve duly to explain the paralytic symptom, quite apart from any supposed absence or deficiency of cerebral influence.

This form of muscular paralysis, however, from injury on the same or corresponding side of the brain, *is* very remarkably illustrated in Case 2. In this case we have an instance of this somewhat perplexing pathological phenomenon. Hemiplegia existed on the "*left*" side of the body clearly dependent on disorganization of the *corresponding* side of the brain. This I will not now more particularly advert to, as I shall have another opportunity of doing so in a communication which I am preparing for another place, on the general subject of such a form of paralysis.

Dr. John W. Ogle, *3rd of May*, 1859.

---

14 *Epilepsy; Idiotcy; Hemiplegia on the left side of the Body, with frequent spasmodic action, and chilliness of the paralysed limbs. Atrophy of the Right Hemisphere of the Brain in connection with distention (from old inflammation?) of the lateral Ventricles; also Atrophy of the Left Cerebellar Hemisphere.*

History.—The patient G. C., was a boy æt. 13, who was brought into St. George's Hospital, extensively burnt on the surface of the body, and who died in consequence. It seemed, that from the age of 9 months he had been subject to epileptic attacks, and it was in the course of one of these, whilst unwatched, that he fell into the fire. These attacks, of which the first took place during dentition, had become more and more frequent, and latterly he had had as many as twelve or thirteen in a night. The first epileptic seizure was a severe one, and was followed by paralysis of the muscles of the left arm and leg, which, as the mother said, were constantly "drawn up." During the attacks, which were generally preceded by certain changes in the features, known by the mother to be signs of the coming event, he generally turned very pale, never, however, screaming or foaming at the mouth, and would fall down quite insensible as if fainting. His mouth during the seizures was often drawn to the left side, and the left leg and arm would often be dragged up with force. Otherwise no struggling occurred, and he would lie down quite quietly. After the attacks he generally slept a long time.

As regards the general condition of the body, his left arm and leg were always very powerless, and the whole of the left side of the body almost always felt very chilly, so that he would constantly sit with that side towards the fire. The limbs on the right side were quite unaffected, and he was described as being very "handy" with the right side. His special senses appeared to be perfect, but his temper was most irritable, and at times, especially before the "fits," at which period he could not endure the noise made by other children, he would bite at those near him and even at his own shadow. His mind was decidedly idiotic, and he never could speak more than a few monosyllabic words at a time, and then very indistinctly. His general health was tolerably good, having no habitual cough, palpitation, &c., but he

DESCRIPTION OF PLATE IV.

The Figure represents the Upper Surface of the Brain, in Dr. John W. Ogle's case of Atrophy of a large portion of the Right Hemisphere of the Brain, and of the "left" Hemisphere of the Cerebellum, p. 39.

always suffered from ascarides in the bowels. His appetite was generally good but fastidious. As before said, he died from the effects of the burn.

On *post-mortem examination*, the left arm and leg were found much more rigid than the right ones, and were partially flexed.

The cranium was unusually large, but its coverings and the cranial bones themselves were natural, excepting that the latter were of unusual thinness. On removing the skull-cap the various sinuses were found healthy, and the dura mater on both sides, but especially so on the right, was seen to be more than usually distended. On dividing the dura mater the surface of the left cerebral hemisphere appeared to be tolerably firm and natural (Plate IV.), except that in one or two places between the convolutions and under the arachnoïd, specks of light-yellow coloured recent fibrin existed. The large longitudinal sulcus between the contiguous hemispheres was obliterated by firm light-coloured adhesions, and the right cerebral hemisphere had the following unusual appearances. It had the look (at least the anterior three-fourths) of a huge bag distended with fluid, the surface being roughened, and for the most part of an opaque-yellow colour. This colour was owing to great thickening and hardening of the investing arachnoïd membrane, but here and there towards the outer circumference where this membrane was less thick, the blood-vessels were seen to be very numerous and very injected, so as to give in these places a rather vivid-red hue to the surface. The roughening of the surface, which here and there was almost scabrous, depended on the hardening and contraction of the summits of the various cerebral convolutions. Moreover, in several places under the thickened arachnoïd, specks and small masses of yellow old-standing fibrinous exudation were seen. This condition also extended to the lateral portion of this hemisphere, but not to the base. On slicing the brain, which was of unusually large size, from the upper surface, the general structure of the left hemisphere was perhaps not so firm as it should be, but nothing more unusual presented itself. The left ventricle was extremely large. The substance of the right cerebral hemisphere was, however, in a very different condition. The upper surface of the greater portion of this part,*

* The posterior fourth of this hemisphere had its superficial convolutions as

which at the first sight gave the appearance of a large distended bag, was found to be formed merely of the cortical portion of the brain structure very condensed and indented, and having the thickened and hardened arachnoïd intimately adherent to it. The whole of the medullary part had been absorbed, and the remaining cortical part which formed only a thin lamina or covering of an enormously dilated lateral ventricle, was of a yellowish-brown hue. Three parts of this corrugated hemisphere then was occupied by this very large right ventricle, which like the left one, contained yellowish clear fluid. (The drawing (Plate IV.) represents the brain after the fluid contents of the ventricle had been in a great degree let out, and therefore somewhat collapsed, having also lost its proper form.) On examining the walls of the dilated ventricles, the right one, that which was so very much the largest, was found to have its inner surface unusually firm and thickened, and at its base the corpus striatum was found particularly prominent and very indurated, forming a knot-like elevation. The cerebellum was apparently natural as to its surface and general texture, but its left hemisphere was very much smaller (perhaps one-sixth), than the right one.

Unfortunately I did not describe at the time of post-mortem examination, the various structures at the base of the brain, so that I am unable to say exactly if the healthy proportion was maintained in point of size, &c., between the various elements at the base, and those composing the surface of the medulla oblongata, &c.

In the spinal cord nothing remarkable was noticed. On examining the abdomen, the testicle on the right side was found to be retained within the abdomen, the other one being in its proper place; both were healthy.

Microscopical examination.—Showed the indurated and enlarged corpus striatum at the base of the right lateral ventricle, to be greatly occupied by fibrous and fibrinous granular and fatty

broad and large as those on the opposite or healthy side. The posterior part of the hemisphere, however, did not extend so far back as it should naturally do, and this was, doubtless, partly owing to actual want of substance, but in part, doubtless, to the shrinking and atrophy of the more anterior portions which allowed it to retire forwards. At least this appearance prevailed on the removal of the brain from the skull. It might have been not so marked when *in situ*.

matters diffused throughout its texture, very little of the proper nervous elements remaining, at least comparatively to the entire mass. In the case of the shrivelled and discoloured cerebral convolutions, fibrinous and granular and amorphous material greatly preponderated, no proper tissue being visible. On examining a portion of voluntary muscular fibre from opposite sides of the body, I could not detect any difference; this was also the case with regard to portions from opposite sides of the spinal cord.*

Commentary.—In this case we have the ordinary law observed of paralysis as to voluntary power of one side of the body corresponding with lesion of the *contrary* side of the brain. It is curious to remark that along with destruction of so large a portion of one hemisphere the organs of special sense enjoyed their complete functions, and the movements of the face, eyes, &c., were entire. The great loss in the substance of the dynamic or grey matter of the brain correspond well with the deficiency of intellectual power.

As regards the causation of this condition of things, the state of the arachnoïd, the effused fibrin both on the surface of the brain and within the substance of the structures within the ventricle, point clearly, in my opinion, to some long antecedent inflammatory action. Some extreme congestion connected at the onset with the general disturbance attendant on the disturbing processes of dentition, and causing the initiatory convulsive attack, was no doubt, as I think, the starting-point. Whether this led to any extravasation, which in a secondary and irritative way established some surrounding inflammatory action, or whether this latter originated independent of any extravasation, it was impossible to determine. The inflammatory processes of course would lead to the excessive distention of the ventricles by the effused fluid, and this over-distention in its turn, to atrophy, by compression of the surrounding parts of the hemisphere.

Two facts involved in this case are so worthy of regard that I would especially allude to them.

1. The circumstance that although the right cerebral hemisphere was so interfered with, and consequently voluntary motor

* (See note * in p. 42.)

power over the muscles on the left of the body so impaired, yet I could find no alteration in the microscopical structure of several of these muscles, which I examined minutely. It must, of course, be borne in mind that the hemiplegia was not absolute, and the remaining power of action may have sufficed to keep the impaired muscular structure sufficiently well nourished. If so, it lends some strength to the expectation that in not hopelessly incurable paralyzed limbs, even a comparatively moderate degree of stimulus duly and persistently kept up daily may suffice to maintain histological integrity, and thus to bridge over, so to say, the great evils entailed by temporary loss of power, which otherwise might become permanent. Neither did I discover any alteration in the microscopical character of the spinal cord.*

2. Another fact of great interest is afforded by this case, as the illustration connected with this communication well shows, and that is the correspondence between atrophy of the *left* cerebellar lobe and a similar but much more advanced state of atrophy of the *right* side of the brain proper. At the time of the *post-mortem* investigation, I did not observe the coincidence in this case, but on inspecting the careful drawing made of it by Dr. Westmacott, Dr. Brown-Séquard, to whom I was showing it, at once pointed to it.

I may take the opportunity here of stating that the highly philosophical observations of Dr. Turner on this subject of the connection between atrophy of one side of the brain and the alteration of nutrition of the opposite side of the cerebellum and spinal cord,† are of the utmost interest and value. In those observations, it will be seen that Turner adopts the following view of the sequence of pathological changes attendant on this atrophy of the brain, which shows itself during life by paralysis of voluntary motion, with conservation of sensibility. In his opinion, cerebral convolutions are first destroyed, and thus the ventricles are in a

* I mention this in reference to the statements of Turck, who has found (see Wagner's Zeitschrift, Vol. VI., 1850, and Vol. VIII., 1852, &c.), that in certain cases, secondary changes as shown by the microscope, are induced along parts of the spinal cord in consequence of disorganization or alteration of the cerebrum.

† "De L'Atrophie partielle ou unilaterale, du Cervelet, de la Moelle Allongee et de la Moelle Epiniere, consecutive aux destructions avec Atrophie d'un des Hemispheres du Cerveau." These inaugurale, Paris, 1856.

secondary manner, dilated to compensate for the retreat of indurated brain substance, along with atrophy and induration of the optic thalamus and corresponding mamillary tubercle. Consecutive to this, the atrophy is continued in the corresponding half of the medulla oblongata, in the crus cerebelli and anterior pyramid of the same side, and then after the decussation of the pyramids, in the opposite half of the spinal cord, and in the opposite lateral lobe of the cerebellum.

In this case of mine, owing to the induration and the very great enlargement of the optic thalamus and the corpus striatum at the base of the third ventricle on the right side, I was inclined to think that the cause of the diseased condition was an inflammatory attack of the inner surface of the ventricle under which the fibrinous deposit had become exuded into the brain tissue, and the ventricle dilated with fluid; that to this the atrophied state of the cerebral convolutions was consecutive. On the point of causation I am inclined to differ with the observations of Dr. Turner in supposing, from such a case as mine, that other causes than that which he assigns, may exist for such cases of cerebral atrophy.

I regret very much that in this case I did not minutely examine the base of the brain, with reference to the statements of Dr. Turner as to consecutive atrophy of the medulla oblongata, &c., I had not, however, at the time read Turner's work on the matter. The atrophy could not have been very marked or it would not, I think, have passed entirely unnoticed; but I am well aware how facts and circumstances do escape observation, unless there be a predominant idea in the mind of the observer.

I may mention, in conclusion, with regard to the testicle retained within the abdomen that I have, on previous occasions, found that the testis, although undescended, has possessed all the proper and healthy microscopical characters of a healthy organ. Of such is a specimen which we have in St. George's Hospital Museum, which, although retained firmly within the abdominal cavity, yet had quite a healthy character when minutely examined. This specimen exists in the new catalogue as No. 2, Sub-series IV., Series XXXV., and was presented by Mr. Cæsar Hawkins.

Dr. John W. Ogle, *17th of May*, 1859.

---

15. *Analysis of seven cases of Obstruction of the Cerebral Arteries.*

The following series of cases have been collected from the records of the *post-mortem examinations* which I have conducted at St. Thomas's, for the sake of ascertaining how far my experience confirmed or otherwise the important principles with regard to obstruction of the cerebral vessels laid down by Dr. Kirkes, in an interesting and important paper, published some years ago in the Transactions of the Medico-Chirurgical Society. At the same time, it has not been my intention to debar myself from making any further observations, which might be warranted by the cases under consideration.

1. *Cause of Obstructive Coagula in Cerebral Vessels.*—Dr. Kirkes believes that the obstruction of cerebral vessels is mostly due to the transference of accidentally detached cardiac vegetations or clots, which, carried onward by the circulating fluid, become impacted in the smaller arteries of the brain. And in proof of his views he points out in respect of the cases which had come under his own observation, that there had been vegetations on the aortic or mitral valves; that the clots contained in the vessels of the brain resembled closely, if not accurately, the cardiac vegetations; that the cerebral symptoms indicating the presence of these bodies had manifested themselves, as they should do in accordance with his theory, quite suddenly; and that the obstruction occurred in particular vessels (the right or left middle cerebral) into which it seemed from various considerations probable, that such bodies would be most naturally conveyed—all, facts of great importance, and in combination appearing fully to justify the inferences which he ventured to draw. Now, considering the apparently conclusive character of these observations, considering, too, that many confirmatory cases have since been published, it is certainly remarkable that not one of the seven cases which constitute my experience affords a positive instance of the operation of Dr. Kirkes's law; in five of the number there were no old cardiac clots or vegetations at all; and in the remaining two, although friable excrescences were connected with the valves, it was anything but clear that the plugs in the cerebral arteries were dependent on the conveyance thither, and arrest therein, of fragments of these excrescences.

Before, however, expressing any positive opinion, it is desirable to examine and weigh the facts and teachings of the several cases here alluded to. In those numbered 1, 2, and 3, there was no cardiac affection of any kind, there was no apparent disease of the pulmonary veins or lungs, no source, in fact, whence by any possibility transferred clots could have been derived. Further, there was no such advanced or extensive disease of the brain itself, as could have induced stagnation and coagulation of blood in the arteries leading to, and impeded in their passage through, the diseased tract. It seems certain, therefore, that the obstruction of the vessels must have been due either to spontaneous coagulation of the blood contained within them, or to coagulation determined by some local arteritis. It is easy to express an opinion, but difficult to decide, and probably of no real importance, which of these two latter causes most claims our attention. It is undoubted that in certain cachectic conditions and in certain states of the circulation, spontaneous coagulation of the blood takes place during life in the very centre of propulsion; and it can hardly, therefore, be far-fetched to assume that similar coagulations might, under certain circumstances, occur at the extremes of the arterial system. On the other hand, arteritis is a recognized and real disease; the microscopic characters presented by the clots, in at least two of my cases, were rather in accordance with this view of their origin than any other; and the successive way in which, at comparatively long intervals, the several basal arteries became engaged in Cases 2 and 3, points in the same direction.

In Cases 4 and 5, as in those of Dr. Kirkes, the obstruction occupied the right middle cerebral artery and its branches; and friable vegetations existed on the left valves of the heart. It seems not unnatural, therefore, to suppose (especially as the histories are in full accordance with such a supposition), that the arterial obstruction was due to the impaction of detached fragments of these vegetations. Yet it is perfectly certain that the obstructing clot in Case 4 had not been carried from the heart, for it differed in appearance from the cardiac fringes, and was, moreover, accurately moulded to the vessels in which it was contained. And like objections apply with even greater force in regard to Case 5. In both instances I endeavoured to ascertain

whether any transferred vegetation could have acted as a nucleus for subsequent coagulation. But my efforts were fruitless; and although I do not venture to regard their results on this point as conclusive; they served, at least, to render it additionally clear that the clots obstructing the arteries had not been carried from the heart in the condition in which they were discovered. It is possible, of course, that disintegrating particles detached from the valves, and cemented, as it were, in their transit by coagulated fibrine, may have become arrested in the arteries of the brain; it even suggests itself as a possibility that in one case (5) pus or tubercle from the lungs may in a similar manner have produced the coagula; but it is important to bear in mind that neither case furnishes any proof of the correctness of such views, and that in the absence of such proof there is no satisfactory reason for regarding the cause of obstruction in these two cases as different from that which we have shown to have operated in the first three.

Cases 6 and 7 I am disposed to place in a different category to any of the others; in both of them there was extensive brain disease, and in both I am inclined to regard the arterial affection as secondary to that of the brain substance, or at all events, as not productive of it. In neither of them, unfortunately, does the history aid us much in arriving at a determination in regard to this point. But the pathological conditions presented by case 6 seem to show clearly that there had primarily been effusion of blood; that this effusion occupied a central position in reference to the softening, and had probably produced it; and that the coagulum in the artery was of more recent origin than the apoplectic clot, and probably, therefore, as in the analogous examples offered by cases of pulmonary apoplexy, was to be regarded as its natural accompaniment or sequel. So also the post-mortem appearances discovered in case 7 indicated an amount of chronic disorganization far too extensive to have been caused by arterial obstruction alone (judging at least from the facts presented by the first three cases of the series), and suggested consequently the secondary, and possibly dependent nature of the arterial affection.

The conclusions, therefore, which I derive are, that in two out of the seven cases, there is some reason to suppose that the arterial obstruction was primarily due to transference of matters furnished

by cardiac vegetations; that in two others, there are good grounds to believe that the formation of plugs was dependent upon cerebral disease; that in the remaining three the blocking up of the arteries was certainly produced by either spontaneous coagulation or local arteritis; but that one or other of the latter two causes may with almost equal plausibility be applied in explanation of every one of the entire series of cases.

In two of the cases, the patients had suffered from well-marked syphilis; is it possible that the secondary cachexia of this disease is capable of producing the condition of cerebral arteries under consideration?

2. *Vessels affected and their condition.*—The cases adduced in this communication point to no definite rule with regard to the relative liability to obstruction of the several cerebral arteries. If cases 4 and 5 be really examples of conveyed vegetations, they tend of course further to confirm Dr. Kirkes's views, inasmuch as in both of them the arteries affected were the right middle cerebral and its branches. But apart from this, we find that sometimes one main artery or a branch of it was alone obstructed, and sometimes two or even three of the more important trunks were involved at the same time; that the right common carotid or its branches was the seat of disease in four instances; the left carotid or its branches in an equal number of cases; and the basilar or vertebrals in two. As regards the coagula themselves, some were small and occupied but a small portion of the length of a vessel, others formed a continuous branching system an inch or two long. Some were recent and presented most of the usual characters of newly coagulated fibrine, but in two cases (3 and 5) there were appearances which seemed clearly to indicate that something more than mere coagulation (that admixture in fact with inflammatory products had taken place. In several instances the disease was of old date, and the material obstructing the vessels had undergone various of those changes which transformed coagula commonly present; thus in two or three the vessel was found obliterated by a development of fibrous tissue, inseparable from the arterial walls; and in two the channel was occupied by a kind of elongated cyst, reminding one of softening cardiac clots, or of the cavities which succeed to apoplectic effusions.

3. *Effects on the brain substance.*—The immediate effect of obstruction appears to be patchy congestion, limited generally to the locality with which the obstructed vessels directly communicate. To this, however, succeeds a yellowish or slightly greenish discoloration attended by marked softening, and the formation of numerous compound granular cells. The affected patches appear usually to be small and circumscribed, but are sometimes extensive and diffused. It is manifest that the obstruction of a single vessel is competent to, and frequently does, produce all the mischief above spoken of, and speedy death; but it is equally manifest (and this is an important fact) that such mischief may be more or less completely recovered from, as is conclusively shown by the history and pathological conditions of cases 2 and 3, in both of which there is a history of prior attacks similar to those that ushered in death, and in both of which there were distinct post-mortem proofs that these attacks had depended on the same kind of cause as those which proved fatal.

4. *Symptoms.*—In all the cases in which the cerebral symptoms were due to the obstructed vessels, and of which a history exists, it appears that the symptoms arising from the obstruction were suddenly developed and in such a manner as to constitute what may be called a fit—and indeed, in most, the character of the fit was stated (a statement not always repeated in the appended notes) to have been epileptic. There is good reason, however, to doubt the general correctness of the reported nature of the attacks, for in some of those in which the history is most complete, including one under my own care, the attacks though sudden were unattended by loss of consciousness or by convulsion; were, perhaps, as in some of Dr. Kirkes's cases, rather of the nature of syncope and accompanied or speedily followed by well-marked hemiplegia. The further symptoms and subsequent progress of these cases do not seem to call for special notice; the characteristic features of them being those alone which belong to the period of invasion.

The cases are not sufficiently numerous to justify any generalization with regard to the influence of age, sex, and other minor, but still, no doubt important, particulars; and for this reason I re-

frain from offering on these heads comments which might be ingenious, but would certainly prove useless.

CASE 1. *Obstruction of both Vertebral and Basilar Arteries. Circumscribed Softening of posterior part of Left Cerebral Hemisphere.*

H. H., a cellarman, æt. 36, was admitted on the 19th of July, 1855, and died on the 23rd. No history is preserved; but the bed-ticket shows that he was labouring under cerebral symptoms, and that for the last two days at least he was in a state of excitement, probably like that of delirium tremens. He was treated with leeches to the temples, a blister to the head, and small periodical doses of calomel; and on each of the last two nights took half a grain of morphia.

Post-mortem examination.—Membranes of brain normal. Brain somewhat congested, but generally healthy. Near the under surface of the posterior angle of the left cerebral hemisphere, was an indistinctly circumscribed portion of brain substance as large as a filbert; which was slightly but decidedly softened, of a tawny hue, and somewhat congested; and which, under the microscope, displayed, in addition to the normal elements, numerous compound granular cells, and vessels more or less copiously studded with granular matter.

The vertebral and basilar arteries were dilated, rigid, and presented some atheromatous deposit. At their point of union, they were filled by an adherent clot. This clot was three-forked; one process, about a quarter of an inch long, extended along the right vertebral, one about one eighth of an inch along the left vertebral, and the third measuring an inch in length was prolonged into the basilar. The portion occupying the vertebrals and commencement of the basilar artery, distended these vessels, adhered to their parietes, was tough, and decolorized; but the remaining part of the basilar coagulum was comparatively soft, more or less coloured, and became thinner and less perfect towards its anterior extremity. The axis of the firmer clot was softer than its periphery, and retained more or less colour; and it seemed probable, therefore, that though the formation of the coagulum must have begun some time prior to death, a gradually diminishing central channel may have existed up to within a short

time of that event. All the abdominal and thoracic viscera were healthy. There were no vegetations connected with the cardiac valves.

CASE 2. *Obstruction of both Internal Carotids and their Branches. Congestion of the Brain without softening.*

J. S., a male, æt. 35, admitted for hydrocele. Six months previously, he had a sudden seizure, in which he was paralyzed, and became partially blind. Of this he almost completely recovered. Three or four days after admission, he began to lose the use of his right arm, and subsequently his speech became affected. About three weeks later, he became suddenly comatose, and died in two days.

Post-mortem examination.—Brain congested, not softened. The basilar artery was completely filled up by an old adherent fibrinous clot. The cerebral portions of both internal carotid arteries and their branches were diminished in diameter, and blocked up by solid adherent coagula of old formation. The latter two arteries were wholly impervious; the former allowed probably a little blood to pass still between it and the arterial walls. The heart was large, but otherwise healthy. Path. Trans., Vol. IX. p. 65.

CASE 3. *Obstruction of both Internal Carotids and their Branches. Softening of the Anterior Cerebral Lobes and Right Corpus Striatum.*

S. T., a female, æt. 23. Had four fits. The first two appeared to be epileptic, and occurred the one six years, the other three or four years before death. The nature of the third was not ascertained, it took place eight days before death, and was followed by partial loss of consciousnes and hemiplegia of the left side. The last was distinctly epileptic, was followed by complete coma, and death at the end of twenty-four hours. She had been subject to dyspepsia, and about a year previously was under treatment for secondary syphilis.

Post-mortem examination.—The brain was generally congested. The anterior lobe of each cerebral hemisphere was decidedly softened, but the softening was most extensive on the right side, and involved the corpus striatum; which latter was decidedly softer

than any other part of the brain, and presented patches of congestion. The right internal carotid and its anterior and middle cerebral branches were filled and obstructed by an adherent cylinder of softish coagulum. The left internal carotid and its branches were contracted and obliterated by a white membranous formation, which was evidently a transformed clot. The other arteries were healthy. Heart healthy. Path. Trans., Vol. VII., p. 111.

CASE 4. *Obstruction of the Right Middle Cerebral—Softening of the Right Corpus Striatum—Vegetations on the Mitral Valve.*

M. S., a married woman, æt. 53, was admitted on the 19th of June, 1858, having suffered for six weeks from headache, drowsiness, double-vision, pains in the limbs, and general depression.

On the 18th, the day before admission, she had two consecutive fits, during which she was insensible and spasmodically drawn to the left side. Complete loss of power and sensation followed on the same side; but there was no pain. When admitted, the face was not perceptibly drawn, but the tongue was protruded slightly to the left. The complete motor and sensory paralysis continued; but the excretions were voluntary. There was no evidence of cardiac disease.

She improved a little at first; but the bowels were obstinate.

On the 2nd of July (fourteenth day) she began to complain of pain in the right temple, and had slight contraction of the left side. A week later, some erysipelatous inflammation appeared on the legs; and soon after bed-sores formed. She died with partial comatose symptoms, but not in an apoplectic state, on the 29th of July; the forty-first day after the hemiplegic attack.

Post-mortem examination.—Much emaciated.

The surface of the brain and its membranes appeared healthy; there was no congestion, and no excess of fluid.

The arteries at the base were generally healthy; but the right middle cerebral at its point of bifurcation was remarkably plump and had a yellowish-colour like that due to atheroma. On laying it open this appearance was found to depend on the presence of a small coagulum. The portion in the middle cerebral itself was scarcely so large as a grain of wheat; its proximal end was

smooth and rounded, but its distal was bifurcated, sending into each of the branches gradually tapering cylinders about half an inch long. The clot was firm and elastic, it had generally a faint yellowish tinge, but its posterior extremity had a deep red colour, and its distal prolongations were lost in ordinary dark-coloured clot. The portion resting against the angle of bifurcation had an opaque-buff colour, and was firmly adherent; but there was no decided adhesion elsewhere. On section the clot was found to be solid throughout, but a considerable portion of its interior had a deep reddish-black colour.

The substance of the brain was for the most part healthy; and the ventricles contained only a little serum. The surface of the right corpus striatum presented a slightly depressed patch of a greenish-yellow tint; and the subjacent tissue, in a bulk equal to a filbert, exhibited a similar colour, was less elastic and yielding than the surrounding brain structure, but much more friable and pulpy. It was tolerably well circumscribed; but several smaller and less distinctly marked patches of the same kind were observed in the neighbourhood.

The clot in the cerebral artery consisted microscopically of an indistinctly fibrillated material, containing in many parts blood corpuscles more or less altered. The diseased patches of brain tissue presented large numbers of globular or ovoid compound granular cells, but nothing of the nature of pus-corpsules. There was a little recently deposited lymph on the surface of the heart. The heart itself weighed eight ounces; and with the exception of the mitral valve was healthy. The mitral was thick and contracted, admitting only the tip of the finger; its chordæ, too, were a little thickened; and a solid fibroïd mass containing a little earthy matter, and about as large as a small hazel-nut, occupied its left angle, and was covered on its auricular aspect by a little tough granular adherent lymph. There were old pleural adhesions on both sides. The left pleura presented a circumscribed empyema, and the corresponding lung was œdematous and somewhat carnified. No other organ exhibited any appearances worthy of note.

CASE 5. *Obstruction of the Right Middle Cerebral Artery. Congestion of the Right Corpus Striatum. Vegetations on the Aortic and Mitral Valves.*

E. W., a childless married woman, æt. 27, was admitted under my care, April 26th, 1859, with a history of phthisis extending back six months, and of slight anasarca for the previous two weeks.

On admission, she presented the usual symptoms and other indications of advanced phthisis, was suffering from severe diarrhœa, and had slight anasarca. The urine, however, was healthy, and the heart's sounds and rhythm apparently normal. Her chief complaints were of diarrhœa and extreme difficulty of breathing. She continued in much the same state until the 6th of the following month; at two P.M., of which day she was attacked without previous warning with sudden and complete loss of power on the left side of the body. The attack was attended by loud groaning and other cries of distress, which attracted the nurse's attention, who found the patient quite conscious, without headache or convulsions, but suffering from greatly increased difficulty of breathing, and from hemiplegia. From this moment the loss of power continued complete, but sensation somewhat impaired, remained; she passed her excreta unconsciously; but she retained her intelligence nearly to the last, becoming a little delirious an hour or two only before her death, which took place on the 8th, at one A.M.

Post-mortem examination.—The surface of the brain and its membranes appeared healthy. The substance of the organ, too, was generally of normal consistence and colour; the right corpus striatum, however, though not altered in consistence, presented on section a rosy tinge very different from the natural colour of its fellow, and was studded with irregular patches of deep congestion, varying in size and in intensity, but never displaying the depth of colour characteristic of extravasation. The arteries at the base seemed at first sight healthy; but by a little dissection it was shown that the right middle cerebral, with some four or five of its branches for a length of nearly a couple of inches, was distended and completely obstructed by a branching coagulum. This was chiefly fibrinous, and slightly but decidedly ad-

herent to the walls of the vessels. Its proximal end was rounded, and its distal terminations in the several arteries were generally rounded also and nearly equally definite. Its surface was tolerably smooth and consistent, but its interior was somewhat soft and pulpy. The obstructed branches were traced in the direction and to within a distance of half an inch of the affected striated body; but their continuations into the diseased tissue were empty and otherwise normal.

Under the microscope, the congested portion of brain substance presented no deviation from the healthy state. The clots in the arteries were made up chiefly of ordinary coagulated fibrine; but they displayed numerous large densely aggregated groups of cells which looked exactly like pus, and were characteristically affected by acetic acid. From their number, and their grouping, they could scarcely have been the ordinary white corpuscles of the blood; yet I do not venture to assert that they were really pus. The pericardium was healthy. The heart was of usual size and shape, and its valves were competent. But the aortic valves were a little thickened, and presented, chiefly in connection with the corpora arantii, a few small, soft, earthy vegetations. The curtains of the mitral also exhibited several similar formations near the free edge of their auricular aspect; but they were larger and varied from the size of a small pea downwards. The vegetations presented microscopically the usual characteristics of coagulated fibrine, and in some places were studded more or less thickly with opaque granular matter apparently earthy; but they contained no corpuscles. They did not appear to be of very old date.

Both lungs were far advanced in tubercular disease, and contained many and large cavities. The colon presented several large tubercular ulcers. The liver was a little fatty; but all other organs were healthy.

Case 6. *Effusion of blood into the Left Corpus Striatum. Extensive softening of the surrounding Brain Substance. Blocking up of the Left Internal Carotid and its Middle Cerebral Branch.*

H. R., æt. 41, a cabinet-maker, was admitted January 17th, 1859. It was stated that he had had two nocturnal struggling fits, one three months, the other two months previously; but that

there had been no consequent paralysis. Two hours before admission, he had a third fit; it did not appear to have been attended by convulsions; neither did it seem to have been strictly apoplectic, insensibility not having been perfect. On emerging from the attack, he was found to have complete loss of power on the right side. When first admitted, he was sensible, and for a day or two improved; but his intellect shortly became impaired; contraction of the paralyzed limbs soon followed, the excretions became involuntary, and large bed-sores formed. Latterly he lay quite still in bed, unconscious, or only calling out at intervals, and muttering to himself. He died on the 10th of March, twenty-four days after the seizure.

Post-mortem examination.—The surface of the brain was a little congested; the sub-arachnoïd fluid (which was not superabundant), was somewhat turbid, and the angles of the sulci were generally occupied by soft opaque-yellow, inflammatory deposit, accumulated chiefly on either side of the larger veins. The inflammatory exudationwas most abundant on the left hemisphere, and in the confluxes connected with the cerebellum. The brain substance was generally healthy; but nearly the whole of the middle lobe of the left cerebral hemisphere had something of a granular or mottled aspect, presented a greenish-yellow hue, was inelastic, but soft and friable, and broke down readily into a pulp. This condition was manifested by the whole of the central portion of the lobe; extending on all sides to within but a short distance of the surface, but actually reaching it in those parts only corresponding to the middle fossa on the one hand, and bounding the floor and side of the lateral ventricle on the other. The surface of the affected optic thalamus and corpus striatum was somewhat depressed, and partook in the general hue of the diseased brain structure. Embedded in the diseased tissue, and situated near the anterior, outer, and lower part of the corpus striatum, was an irregular mass of friable, brick-red, or rusty-coloured, old clot, about as large as a horse-bean; and round about it a considerable amount of orange-coloured pigmentary deposit. The ventricles contained an ordinary amount of fluid.

The vessels at the base were generally healthy; but the left internal carotid and its middle cerebral branch were distended by

a slightly adherent cylinder of tough, oldish, and almost wholly decolourised fibrine.

Under the microscope, the orange-coloured matter presented ruby-coloured rhomboidal crystals, and yellow-ochrey, or orange-coloured clusters of granular matter. The softened brain substance was studded with vast numbers of large but various-sized compound granular cells; together with numerous irregular aggregations of minute oily globules. These bodies were so numerous as almost to conceal everything besides. The normal nervous elements, however, were really present. There was no appearance of pus in the substance of the brain.

The heart was perfectly healthy; its valves presented no vegetations. There was no noticeable affection of other organs.

CASE 7. *Syphilitic (?) Disease of the Brain. Obstruction of the Left Internal Carotid and Branches.*

G. M., male, æt. 34, had three apparently epileptic fits, severally some years, twenty months, and two months prior to death respectively. After the second he became subject to attacks of headache and vertigo; and after the third remained partially paralyzed on the left side, became imbecile, and for some hours before death comatose.

At the *post-mortem examination*, the dura mater was found adherent over the anterior lobe of the left hemisphere of the brain, and beneath it embedded in the cerebral substance were several fibrinous masses from the size of a hazel-nut downwards. In the anterior part of the left corpus striatum was a small cyst apparently apoplectic; and the anterior half of the right one was congested and much softened. The left internal carotid and its branches, for a distance of about one inch were obliterated by adherent cylinders, of tough, old coagulum. The heart was healthy. The liver presented cicatrices and small knotty tumours.

(This case is given in detail at p. 21 of the present volume.)

TABULAR ARRANGEMENT OF CASES.

No. of Case.	Sex.	Age.	Number of fits, and date of last.	Condition of Cardiac Valves.	Arteries of Brain obstructed.	Condition of Brain.	Other particulars.
1	M.	36	No history.	Healthy.	Basilar artery and terminations of both vertebral.	Circumscribed softening of posterior part of left hemisphere.	Nothing worthy of remark.
2	M.	35	Three attacks; the last two days before death.	Healthy.	Both internal carotids and branches, and the basilar. A little blood still passed apparently by the latter vessel.	General congestion.	Hydrocele and chronic inflammation of testicle.
3	F.	23	Four attacks; the last twenty-four hours before death.	Healthy.	Both internal carotids and branches.	Softening of both anterior lobes, but chiefly of right corpora striatum.	Secondary syphilis.
4	F.	53	One attack, six weeks before death.	Vegetations on mitral.	Right middle cerebral.	Softening of right corpus striatum.	Circumscribed empyema. Slight pericarditis.
5	F.	27	One attack, thirty-six hours before death.	Vegetations on aortic and mitral valves.	Right middle central.	Congestion of right corpus striatum.	Phthisis.

No. of Case.	Sex.	Age.	Number of fits, and date of last.	Condition of Cardiac Valves.	Arteries of Brain obstructed.	Condition of Brain.	Other particulars.
6	M.	41	Three fits; last twenty-four days before death.	Healthy.	Left internal carotid and middle cerebral.	Apoplectic clot in left corpus striatum; extensive softening of left middle lobe; meningitis.	Nothing worthy of remark.
7	M.	34	Three fits; last two months before death.	Healthy.	Left interal carotid and branches.	Syphilitic (?) disease of left anterior lobe; apoplectic cysts.	Secondary syphilis. Cicatrices in liver.

Dr. Bristowe, 17*th of May*, 1859.

16. *Softening of the Spinal Cord, from concussion, arising from Fracture of the Cranium and of the sixth Cervical Vertebra.*

The patient was a woman, æt. 38, of drunken dissipated habits, who had fallen from a window thirty feet high. On admission to the Westminster Hospital (under the care of Mr. Holt), on the 15th of September, 1858, she was suffering from all the symptoms of concussion. A tremendous scalp wound, which ran in a direction from before backwards, almost peeled the right side of the head. This was dressed, and the patient put to bed and kept quiet. In the course of five or six hours, she had pretty well rallied, and a careful examination of her general condition was then made. It was found that all sensation was lost in the parts of the body below the ensiform cartilage.

The abdomen was tympanitic (palsy of the abdominal muscles and intestines), and later in the day the bladder became distended and paralysed. Twenty-four hours from admission it was noticed that the intercostal muscles were powerless, and the breathing performed only by the diaphragm. There was complete paralysis of both arms. Articulation was somewhat imperfect. Consciousness had returned completely, now that the state of concussion had passed away.

No remarkable change of the symptoms ensued during the next five or six days. On the morning of the 22nd, however (the eighth day from admission), a certain feverishness which had all along been present, increased materially, and delirium set in. Through the whole of the day she sank rapidly, the pulse becoming quicker and more feeble, the breathing hurried, deglutition difficult, and the sphincters paralyzed. Death took place at eight P.M. on the eighth day from the occurrence of the accident.

Post-mortem examination detected a fracture of the cranium, which only partly corresponded with the position of the wound in the scalp. Starting from a point opposite the middle of the inter-parietal suture and about one quarter of an inch to the right of it, the crack extended obliquely across, so as to join the coronal suture about a quarter of an inch to the right of the mesian line, running through the left coronal and the suture between the

temporal and the great wing of the sphenoïd, splitting into the foramen ovale, winding round the apex of the petrous portion of the left temporal, and extending into the basilar portion of the sphenoïd bone. The edges of the coronal suture were a great deal separated, and the interval filled with clotted blood. A large clot of blood was found between the dura mater and the left half of the frontal bone, which seemed to have been formed by a rupture of the meningeal artery. The dura mater was everywhere much congested. The ventricles contained no fluid, and the rest of the brain was healthy. The wound of the scalp had never taken on an active condition, none of it had united by adhesion, and scarcely any pus or granulations had been thrown out.

The body of the sixth cervical vertebra was found to be crushed into many pieces, which were not, however, materially displaced.

Opposite the fracture, there was some blood effused between the dura mater and the bone, on the anterior surface of the former. The central grey matter of the cord for the distance of one inch, corresponding nearly with the "intumescentia cervicalis," was in a state of red softening, exactly resembling raspberry jam. The anterior and lateral columns were quite healthy; and the effects produced by the injury can therefore only be explained on the principles laid down by Dr. Brown-Séquard as to the functions of the various parts of the spinal cord.

The calvarium of the fractured skull was exhibited to the Society, showing the non-correspondence in direction of the wound and the fracture. The fractured spine was also shown.

Dr. Anstie, 17*th of May*, 1859.

II.—DISEASES, ETC., OF THE ORGANS OF RESPIRATION.

1. *Cicatrization and Contraction of the Trachea and Bronchi after Expectoration of Rings.*

The specimen consisted of several rings which had been expectorated during the spring of 1850—nearly two years and a

half before death. The case occurred in a gentleman, æt. 31; and the disease was supposed to be of syphilitic origin. For about a couple of inches above the bifurcation the internal surface of the trachea was puckered by cicatrices, and to the same extent there had been destruction of the rings. The internal surface of the right bronchus was irregular from cicatrices, and the rings were more or less destroyed. The left bronchus, for about an inch, was quite deficient in rings; and its calibre was much diminished, barely admitting the passage of a No. 12 catheter.

Mr. Sydney Jones, *7th of December*, 1858.

---

2. *Atelektasis Pulmonum.*

The case was that of a child, æt. six weeks, who had never shown any indication of bad health, and who was found dead in bed, its face being partially covered with bedclothes.

On *post-mortem examination*, the lungs only showed morbid change: the lower half of the upper lobe of the left was brown-red in colour, shrunken and depressed, having a collapsed appearance, which showed a marked contrast with the surrounding healthy structure, a distinct line bounding the sound from the defective structure, and to the feel it was firm, like India-rubber; on the free edge of the right lung were several parts, the size of a nut, into which no air passed when inflated from the trachea.

The foramen ovale of the heart was open, and the right side contained fluid blood.

Mr. Henry Obré, *7th of December*, 1858.

---

3. *Specimen of Wound of the Lung extending to its Roots.*

The wound established a communication which allowed the passage of the little finger between the pulmonary vein and the bronchus. The preparation was removed from the body of a very stout woman, æt. 30, who on stumbling, fell upon the broken end of the handle of a parasol. The broken end had perforated the soft parts above the right mamma, and entered the thorax

between the second and third ribs. The pulling of it out by a passer-by was followed by an increased gush of blood from the mouth, and she died almost instantaneously.

Mr. Syndey Jones, 18*th of January*, 1859.

---

4. *Cancerous Tumour in the groove between the Trachea and Œsophagus, on the left side, eating into the Trachea just below the Larynx and into the Œsophagus. Death from Dyspnœa, occasioned probably by destruction of the left recurrent nerve.*

J. G., a coachman, æt. 60, considerably emaciated, was admitted into King's College Hospital on the 20th of November, 1858, with a loss of voice and a harassing cough.

It appeared that three months previously he had a dry cough and a difficulty in swallowing solids. A month later he lost his voice, and could subsequently only speak in a whisper. The fits of coughing became more frequent and violent up to the time of his admission. A fortnight before his admission he brought up some matter from the throat, and since that time swallowing had been less difficult. When he entered the Hospital he had an almost incessant cough, and expectorated a large quantity of watery fluid, in which were suspended some clots of yellow mucopurulent matter. On auscultation, loud sibilant and sonorous râles were heard all over the chest. The conjunctiva of the right eye was inflamed. There was no evidence of disease elsewhere. The sounds of the heart were normal.

The cough continued very harassing and he had in consequence very little sleep.

In the evening of the 26th, extreme difficulty of breathing came on, with inability to expectorate. In the hope of relieving his distress fifty grains of sulphate of zinc, a drachm of ipecacuanha, and three mustard emetics were given in succession by the physician's assistant, but they all failed to excite vomiting: and at half-past ten that evening he died of dyspnœa.

It was contemplated to open the trachea, but the operation was not performed.

On *post-mortem examination*, a globular cancerous tumour rather more than two inches in diameter, was found situated on the left

side of the trachea, extending from the second to the ninth ring. It penetrated the trachea and formed a slight nodular projection on its inner surface. The interior of the tumour contained a small cavity, which communicated by an ulcerated opening with the œsophagus. The tumour was firmly united to the prevertebral aponeurosis.

The lungs were partially adherent on both sides to the pleura costalis and the diaphragm. They were a good deal congested, and the bronchi filled with frothy mucus, which exuded when they were cut across.

No other disease worthy of note was discovered.

Dr. Budd, 1*st of February*, 1859.

---

5. *Epithelioma of the Larynx.*

A gentleman, æt. 59, came under the care of Mr. Debenham in May of last year, complaining that for three months previously he had been suffering from cough, hoarseness, and soreness of the throat. The following symptoms came on rapidly after he had been first seen by Mr. Debenham: wasting of flesh and strength, considerable enlargement of the submaxillary glands, particularly on the right side, severe lancinating pain, great dyspnœa with incessant cough, and copious fœtid, and occasionally bloody expectoration, and dysphagia, which last symptom became at last so distressing that solid food could not be taken, and liquids only in small quantities. The patient slept but little, and never for more than ten minutes at a time, in consequence of the collection of an enormous secretion of fœtid mucus, which gave rise to repeated attacks of coughing. On passing the finger into the throat, the isthmus of the fauces and border of the epiglottis were found occupied by an ill-defined tumour, very ragged in outline. In the ninth week after the patient had consulted Mr. Debenham, tracheotomy was performed by Mr. Ward wih the trocar and canula, above the isthmus of the thyroïd body. The gentleman's life had, prior to the operation, been several times endangered from severe attacks of dyspnœa. The operation was immediately followed by cessation of cough and expectoration, tranquil sleep, and great improvement in swallowing, solid food being in the course of the

day readily taken. Five weeks after the operation, the only evidence of the advance of the disease was an increase in the size of the glands under the jaw; dyspnœa, dysphagia, cough and expectoration were all in abeyance, and the patient so far improved in general condition as to be able to go into the country for change of air.

As regards the details of this case, Mr. Debenham observes, "This history bears witness that we ought not to deny to patients the chance of relief by tracheotomy, even in cases of malignant disease which at first sight appear very unpromising. From the amount of dysphagia and dispnœa which existed before the trachea was opened, I must confess that I urged the operation upon my patient rather with the view of substituting a comparatively peaceful for a very painful death, than with the idea that life would be much prolonged by the procedure. The good results that followed exceeded my most sanguine expectations. It proves, I think, that the dysphagia and copious expectoration principally resulted from the gorged and swollen condition of the pharynx and larynx occasioned by the tremendous efforts to respire. The provision of another channel for the passage of air to the lungs not only relieved these symptoms, but the progress of the malady itself appears to have been considerably retarded by maintaining the diseased parts in a quiescent state. The patient lived five months and more after the operation, and was able to swallow with tolerable comfort to the last, and to breathe without distress, death taking place from exhaustion. The diseased structure was represented by an irregularly oval cauliflower-looking mass, occupying the depression between the right side of the pharynx and larynx. It extended upwards to the lower part of the isthmus of the fauces, and downwards as far as the oblique portion of the upper border of the cricoïd cartilage, and measured about one and a half inches vertically, and transversely about one inch; from its inner border projected two smaller masses, the one above involving nearly the right half of the epiglottis, and the lower the posterior surface of the right arytenoïd cartilage. The right aryteno-epiglottidean fold of mucous membrane had disappeared. A small pendulous mass, about the size of half a pea, covered over by

mucous membrane, was attached to the anterior parts of the right true vocal cord.

No further examination of the body could be obtained.

Mr. N. WARD, *15th of February*, 1859.

---

6. *Note in reference to the Specimen of Casts of the Bronchial Tubes figured in Plate III. Figs.* 3 *and* 4 *of the IXth Volume of the Transactions.*

Since the publication of the last volume of the Society's Transactions, the patient by whom the mass referred to at p. 54 was expectorated, has died: the following particulars of the case during life, and of the condition of the lungs detected after death, will be interesting to the members of the Society.

The patient was a printer, æt. 38, who was sent to Dr. Peacock in May last by Dr. Jones of the Queen Street Dispensary, under whose care he had been for some time. He stated, that he had then been ill about twelve months, and that his illness had commenced with spitting of blood. The mass figured in the Society's Transactions, was ejected by the patient on the 29th of May, and he at different times, both before and subsequently, expectorated similar, but smaller, pieces. On examining his chest, there was found to be considerable want of expansion and deficiency of resonance on percussion beneath each clavicle, and especially on the right side, where also bronchial respiration and irregular crepitation were audible.

On the 15th of July he was admitted into St. Thomas's Hospital, and he then complained of dyspnœa, cough, expectoration and pains in the chest, especially on the left side. He could lie with most ease on the right side. His appetite was defective, and he had pain at the epigastrium and diarrhœa, and his face was puffy. The œdema increased after his admission, and in the middle of August he was very anasarcous—the urine had a specific gravity of 1012, but was not albuminous. On the 18th of September he was taken with increased dyspnœa, and severe pain in the lower part of the left side, and dulness on percussion, and mucous and subcrepitant rhonchus were there detected. On the 20th of October, the general dropsy had to a great extent sub-

sided but the face continued swollen. He gradually sank, and died exhausted on the 11th of November.

Post-mortem examination.—Permission to examine the body while at the Hospital was refused by the friends, and and it was only after it had been removed, that the opportunity for an examination, and that a very imperfect one, could be obtained. Both lungs were found to adhere very firmly to the parietes. The left lung, which alone was removed, was voluminous; at the upper part it contained numerous anfractuous cavities, and in the lower and posterior portions there was much solidification with collections of pus. In the anterior portion there were several masses of a whitish-yellow coloured deposit resembling medullary sarcoma—some of which were as large as hen's eggs. The right lung was less extensively diseased. The heart was of large size, but otherwise healthy.

The liver, spleen, supra-renal capsules, and kidneys were healthy.

Dr. Bristowe has kindly furnished the following notes of his examination of a portion of the deposit removed from the left lung.

"The section of the diseased tissue from the lung was of an opaque buff colour, granular, soft, and friable, yielded no pus, and no distinct cancer juice, but looked more like a fragment of degenerating encephaloïd than anything else. Under the microscope it presented in addition to granular matter, oil, compound granular cells and other evidences of degeneration, and a considerable number of large cells of various sizes and shapes. Some of them presented one, some two, and others a still larger number of elongated tail-like processes, and many of them contained from two to three up to nine or ten, or even a larger number of nuclei. The cells were much like those characteristic of myeloïd. The nuclei were oval, between $\frac{1}{2500}$ and $\frac{1}{3000}$ of an inch long, and contained a single nucleolus, and were frequently observed free in the field of the microscope." There can be no doubt that the tissue examined was similar to that expectorated by the patient and exhibited to the Society. Dr. Peacock, *5th of April*, 1859.

---

7. *Hydrarthrosis of the Left Thyro-hyoïd Articulation, and Dislocation of the Os-hyoïdes.*

The superior cornua of the thyroïd cartilage, and the extremities

of the greater cornua of the os-hyoïdes are connected together by the two lateral thyro-hyoïdean ligaments, which are round cords. Usually they contain cartilaginous or osseous grains, representing sesamoïd bones in other situations. The superior cornua do not possess synovial membranes, nor capsular ligaments, as in the slightly moveable arthrodial joints, formed by the articulation of the inferior cornua with the cricoïd cartilage. The superior cornua, however, are subject to dislocations, arising either from a natural weakness of the parts, or else the result of previous violence. I have seen instances of both. The consequence of this is the formation of an abnormal pouch, or synovial capsule, around the thyro-hyoïd articulation, which is liable to assume the diseased conditions of the natural joints. The specimen exhibited serves to prove the truth of this, for when it was removed from the body and carefully dissected, a capsule filled with fluid was found to exist at the left thyro-hyoïd articulation, but completely embracing the parts entering into its formation, and containing in its outer wall a comparatively large sesamoïd bone of a rhomboïd form. This condition explained the symptoms present during the life of the patient, who was a man æt. 45. He used to feel a sudden click on the left side of his neck, which produced a sensation as if something was sticking in his throat; this depended upon a dislocation of the left horn of the hyoïd bone, and was reduced after several efforts of throwing the head backwards towards the right side, so as to stretch the neck, and then suddenly relaxing the lower jaw. This condition was diagnosed during life and was the fourth example in which I had noticed this peculiarity. The patient in the present instance died of pulmonary phthisis. It may be remarked that all these instances were of the male sex; I believe the hydrarthrosis was present in but the one described.

On the 6th of December, 1848, I was present at a meeting of the Parisian Medical Society, when a short paper was read by Dr. Ripley, of Charleston, South Carolina, upon "Dislocations of the Os Hyoïdes," occurring more particularly in his own person, and the manner of reducing them. He described the latter process, which I have seen him perform several times, when the dislocation was present: it consisted in throwing the head backwards as far as possible, so as to place the muscles of the neck on

the stretch, then relaxing the lower jaw, when the dislocation becomes reduced after a few attempts with a cluck, at the same time gently pressing or rubbing over the displaced part. Sir Charles Bell is the only author who has noticed this interesting subject.

Dr. Gibb, 19*th April*, 1859.

---

8. *Complete Ossification of the Thyroïd and Cricoïd Cartilages.*

The specimens were taken from an old soldier, upwards of 70 years of age, named McKay, who had been in many campaigns, and was at the battle of Egypt in 1801. He became a patient for catarrhus senilis, with cramps throughout the body, and died of old age and debility. His voice possessed a peculiar cracked and harsh sound, and his neck was unusually skinny from emaciation.

Post-mortem examination.—The lungs were found healthy, but adherent almost throughout to the pleuræ; with the exception of a few patches, almost the entire surface of the pericardium was glued together: the intestines were generally adherent to one another, the spleen to the stomach and diaphragm, and the liver to the stomach. A large abscess was present below the right kidney, anterior to the psoas muscle, communicating by means of a small opening with two of the lumbar vertebræ in a carious condition. The thyroïd cartilage was completely ossified, except a small portion of each ala beyond the mesial line, and in general characters resembled the spongy texture of bone. The same feature was present in the cricoïd cartilage, the transformation of which, however, into osseous material was complete. Some of the rings of the trachea were affected in a similar manner. The costal cartilages were also completely ossified.

It may be observed that ossification of the thyroïd and cricoïd cartilages is not looked upon as a morbid condition in persons of advanced life, their conversion into bone being regarded as a natural process, commencing at a certain period of life, and becoming complete as old age is reached. That this is true to a certain extent, I am willing to acknowledge, but it will not explain the occurrence of the same phenomenon in even an advanced degree in persons of the age of from 30 to 40 years, and

in many instances much younger. It is rather an indication that life is advancing rapidly to a termination, and when present in a person, for example, of 35 years, taken with a general fatty degeneration of the tissues associated with atheromatous deposits in the coats of the blood-vessels, life has nearly run its span, although the patient may have a most healthy and ruddy aspect. It is in subjects of this kind that the saccharine element predominates, which rapidly becomes transformed into fat and gives rise to a condition of body which is analagous to that of old age.

Dr. GIBB, 19*th of April*, 1859.

---

9. *Case of Croup, in which the False Membrane extended from the Fauces to the Minute Bronchial Tubes.*

H. J. G., æt. 14, was attacked with catarrh, and two days before he was seen by me the symptoms became severe. On the 6th of January, I found urgent symptoms indicating obstruction in the larynx. The fauces were red, but not much swollen; and on the uvula and right tonsil were two small grey patches. At this time there was no symptom of the lungs being diseased, beyond a little dulness on percussion of the centre of the left lateral portion of the chest.

Opening the trachea gave great and immediate relief. For twenty-four hours after the operation, he appeared much better; he then became rapidly worse; large crackling sounds could be heard over the greater part of the chest, at noon on the 8th, and he died at five P.M., forty-eight hours after the operation.

Post-mortem examination.—The upper lobe of the left lung was of the usual size, but airless and fleshy. The rest of this lung and all the right were crepitant, for the most part; but here and there solid. The tonsils and soft palate were injected and covered to a considerable extent by adherent false membrane. This membrane had a greyish tint, was smooth on the surface, rather tough, presented abruptly defined sinuous margins, was very adherent, of considerable thickness, and sent processes into the substance of the tonsils. The anterior surface and the edge of the epiglottis were healthy; but the posterior surface, and the rest of the larynx and trachea were lined by a false membrane. On the epiglottis it was

pretty firmly adherent, grey, smooth, and not very thick. In the lower part of the larynx and upper part of the trachea, it formed a distinct, thick membrane, which had evidently been displaced and torn by the introduction of the tube. Below this, the false membrane was imperfect, forming adherent shreds, and irregular longitudinal bands, which were incorporated with the subjacent surface. Indeed it seemed that the mucous membrane itself was generally thickened, opaque, whitish, softened, and marked with irregular longitudinal folds, which it was difficult to distinguish from lymph. In the lower part of the trachea and bronchi the false membrane became again thicker, more distinct, and more adherent; and its internal surface was soft, irregular, and shreddy. Into all the tubes proceeding immediately from the bronchi, the false membrane was prolonged in the form of a nearly solid cylinder of toughish grey fibrine. It passed anteriorly into the secondary tubes of the lower lobes, and then for the most part ceased; the smaller ramifications of the bronchial tubes contained puriform mucus; and the mucous surface presenting here and there shreds of adherent lymph. In the upper lobes of both lungs the casts were prolonged, not only into the secondary divisions of the tubes, but into the tertiary, and even into the smaller divisions; so that, to the naked eye, all the tubes appeared to be occupied by fibrinous casts. The casts in the lower part of the trachea, in the bronchi, and in the bronchial tubes, were exactly equal in calibre to the tubes containing them; the outer surface of the one, and the inner of the other, being everywhere in contact, and in some places slightly adherent. The mucous surface presented everywhere strongly marked alternate ridges and grooves; and these markings were exactly reproduced on the outer surface of the casts, which thus presented a fluted appearance. The casts, in the lower part of the trachea and bronchi were hollow, the internal portions being much softer than the outer; and the cavity was occupied by mucus. But the central canal diminished from the trachea downwards, and in nearly all the tubes, except the two bronchi themselves, the casts were solid, the central portion being much softer than the peripheral.

Dr. Barker, *3rd of May*, 1859.

III.—DISEASES, ETC., OF THE ORGANS OF CIRCULATION.

1. *Communication between the Aorta and the Left Bronchus.*

This specimen was taken from a patient of Dr. Halford's, who had long complained of dyspeptic symptoms. Dr. Halford had noticed a peculiar thrill in the pulse, which led him to suspect a want of elasticity in the aorta; but a careful examination failed to detect anything abnormal in either lungs or heart. The man died very suddenly in bed, after throwing up an immense quantity of blood. The preparation showed a diseased condition of the coats of the artery, but a healthy condition of the bronchial mucous membrane, except at the point where the communication was established. There was no evidence of a diseased bronchial gland in that situation. The channel of communication had not been laid open. Mr. Spencer Wells, *2nd of November*, 1858.

Report on the above Specimen.—The lining membrane of the arch of the aorta, for about an inch and a half beyond the valves, presents a rough, irregular surface, with here and there small rounded elevations. Two inches from the attached margin of one of the valves is a depression, one-tenth of an inch in diameter, and surrounded by a slight elevation, but with no solution of continuity of the lining membrane. Immediately beyond the origin of the left subclavian artery, the inner surface of the aorta becomes again very irregularly rugose, and this condition continues for two inches, which is the entire length of the portion of the vessel in the specimen. One inch and three quarters from the orifice of the subclavian, is an orifice, of an irregularly elliptical form, measuring one-sixth of an inch by three-eighths of an inch. This opening is situated upon the right side or concave aspect of the descending portion of the arch of the aorta. Within a circuit of an inch around the orifice are four or five elevations, about one-seventh of an inch in diameter, with as many depressions of similar dimensions. This part of the lining membrane also exhibits a dark-red discoloration, but no apparent breach of

continuity in its surface. The lining membrane of the vessel is continued over the margins of the orifice, and everted in the direction of the adjoining bronchus, apparently to the extent of one-sixth of an inch.

Between the aorta and left bronchus is a rounded tumour one-seventh of an inch in diameter, to the interior of which the opening just described passes. The outer coat of the aorta is prolonged over one-third of the external surface of this tumour.

The general mucous surface of the trachea and bronchi is normal. In the right posterior aspect of the left bronchus, three-eighths of an inch from the bifurcation of the trachea, is an opening three-eighths of an inch in diameter. This is situated in the centre of a slight bulging, which corresponds to the position of the external tumour just alluded to. The margins of the opening are thickened and irregularly crenate. The edges of the opening are nowhere everted towards the tumour, but from one point, a shreddy portion of membrane, one-eighth of an inch in length, projects into the cavity of the bronchus.

A probe passes readily from the opening in the aorta through the tumour, and not at the opening in the bronchus. On laying open the tumour a cavity is displayed, measuring two-thirds of an inch in its long, and half-an-inch in its short diameter. The walls of this cavity are irregularly rugose, and of a dark-red colour.

Microscopic examination (One quarter of an inch, Ross).—A small particle of one of the yellowish deposits in the middle coat of the aorta, near the valves, was examined, and exhibited numerous oil globules (but no cholestearine), infiltrated through yellow fibrous tissue.

A still larger quantity of oily matter was found in the coats of the vessel immediately surrounding the opening, and in its vicinity, and distinct nucleated epithelium was detected in the lining membrane, where it became inverted into the cavity of the tumour, beyond the margins of the orifice.

The walls of the tumour consisted of well-formed fibrous tissue, in parts areolated, with numerous oil globules, much colouring matter, and a few irregularly shaped crystalline particles (hæmatine ?). Their inner surface exhibited at some points distinct traces of an epithelial lining.

Bands of many white fibres were observed in the portion of the outer coat of the vessel which was prolonged over the tumour.

The examination of the preparation left no doubt that the tumour between the aorta and the left bronchus was the sac of a small aneurysm. This would appear to have commenced by a saccular dilatation of the coats of the vessel, and to have been subsequently completed by a condensation of the surrounding areolar tissue. The most direct course for the aneurysm to take being towards the bronchus. Gradual ulceration of the walls of this tube, and sudden fatal hæmorrhage were the results.

FRANCIS SIBSON, M.D.
CHARLES MURCHISON, M.D.
T. SPENCER WELLS, 16*th of November*, 1858.

---

2. *Aneurysm of the Arch of the Aorta.*

The case was that of a man, æt. 50, of spare habit, narrow chest, and middle height. He led an active life as manager of extensive works in Wales. Last winter he slipped down some steps and sprained his ankle, but his health appeared perfectly good till March, 1858. At this time he began to have cough and dyspnœa, and the peculiar sound of the cough and of his voice attracted his wife's notice.

In July he became worse, the dyspnœa increased, and he felt a sense of tightness, thickening, pain, and weight in the chest. Soon after, he had fits of insensibility lasting from half-an-hour to three-quarters of an hour, frequently repeated, and preceded by gasping dyspnœa. Five weeks ago he had another of these attacks very severely; and two or three lesser ones following. He came up to London, and presented himself to me on the 4th of November. His aspect was that of extreme distress from dyspnœa. His colour was rather dusky, and he sat bent forward, and with the shoulders contracted. His voice was very peculiar, and he coughed as if through a small tube, in a high key, sharp and ringing.

Occasionally the aphonia was complete, at other times he described his voice as having a "squeaky tone." Even before any chest examination was made, the diagnosis of pressure on

the trachea was inferred. He had never had dysphagia. He complained of pain, which at first was felt in the sternum, lately between the shoulders. He described it as "slight and dull—not as soreness."

There was no hereditary predisposition to cancer, or phthisis, and his habits had been regular and temperate.

His chest presented the following peculiarities. There was marked immobility of both sides, the walls of the chest scarcely moved. The left was slightly flatter. No external tumour. Percussion was pretty even, or, as we thought, some dulness over the upper and right side of sternum; but having a suspicion of aneurysm, percussion was very slightly practised lest the sac should give way. The sounds of the heart were heard at the top of the sternum, and to the right side rather louder than over the aortic valves; the second sound was loudest in this space. There was no murmur heard in any part of the chest, and no sense of pulsation to the hand.

The whole of the left lung presented a very marked deficiency of respiration, the percussion note being clear, and the contrast with the right lung was very marked in this respect. The respiration was nearly one-sided, although faintly heard even to the base on the left.

The right lung presented loud, rather puerile respiration all over, excepting in the superior scapular region. Here there was bronchial voice and bronchial respiration, and the expiration was loud, prolonged, and blowing. The heart's-sounds were heard in this region, but no murmur was present.

The right subclavian pulsation seemed stronger than the left, the carotids equal. The left radial was less in volume than the right. There was no external venous enlargement. The diagnosis of tumour, probably aneurysm, pressing on the left bronchus, was recorded at the time. His dyspnœa rapidly increased. On the 10th, I was sent for hastily, and found him seated in a chair gasping for breath. He had been in that position for twenty-four hours, and remained so for three more days and nights, when he died. He could not speak, but was sensible. I had his head supported forwards, and had him fanned frequently. Swallowing was impossible; next day he was in the same position,

both radial pulses were imperceptible—he was unconscious. The respiration, formerly nearly absent over the left lung, was now heard equal to that on the right. To my surprise he lived for twenty hours longer, and died quietly without any struggle.

Post-mortem examination, twenty-four hours after death.—Great lividity of the nails of the fingers; chest narrow—contracted; no dulness perceptible on percussion; unusual deposit of fat over the chest and abdomen. The right lung voluminous, slightly emphysematous, its tissue condensed at upper back part, some fluid in right pleura. The left pleura adherent throughout. The left lung collapsed but permeable to air.

The aorta much dilated and diseased, immediately after its origin, the dilated portion inelastic, and with numerous patches of atheromatous deposit on its lining membrane.

An aneurysm springing from the back portion of the vessel before the origin of the innominata, lay pressing on the bifurcation of the trachea, more prolonged towards the right side, but pressing more immediately on the left bronchus so as to narrow the diameter of that tube. It is about the size of a small orange, and when recent was filled with coagula. On examining the bronchial tubes, it will be found that the sac had nearly opened into the right bronchus, a small portion of the coagulum actually pressing into that tube in one or two places, covered only by the mucous membrane. The left bronchus presents similar marks of thinning.

Both pulmonary arteries were much pressed on, the left rather the most; the right runs close behind the sac. The aortic valves were thickened, and the lining membrane close by them much roughened by deposits. The urine found in the bladder after death was albuminous—there was no trace of sugar. The sac lay out of the direct stream of the circulation, and was filled with coagula.

Remarks.—The patient died of apnœa; but had he lived much longer, he must have died of hæmorrhage. It is remarkable that the circulation failed so long before the respiration; he having lived for two days without a radial pulse.

Dr. Pollock, 16*th of November*, 1858.

---

3. *Aneurysm of the Arch of the Aorta.*

W. M., æt. 34, had suffered for two years from difficulty of breathing, which had gradually increased. He had also a cough, and latterly profuse muco-purulent expectoration, amounting to half-a-pint in the day. He had seen streaks of blood in the phlegm, and two months before presenting himself at the Hospital for Consumption had severe night-sweats, and had lost flesh considerably. One brother had died of phthisis. He is a man of middle height, and very round backed.

August 16th.—He has now severe fits of dyspnœa, his respiration is stridulous; there is slight occasional loss of voice, and occasional difficulty of swallowing. The cough is paroxysmal, and very severe; expectoration copious. The urine is scanty, high-coloured, not albuminous. There is slight œdema of the ankles.

Physical Signs.—A patch of well-marked dulness on percussion in the right subclavicular space, extending for about three inches, and encroaching on the sternum. Slight pulsation is felt here, and the heart's-sounds are heard. There is no murmur. Loud bronchial râles over both chests to the bases. The mobility of both sides of the chest is much impaired. There is slight inequality of the radial pulses, the right probably less in volume. Diagnosis recorded at the time—"probably aneurysm." He became an in-patient on the 23rd of September, 1858. On the 25th, he had a very severe attack of dyspnœa, and after struggling for breath for nearly an hour he became pulseless and seemed to have drawn his last breath. However, respiration slowly recommenced, and he recovered so as to become sensible, but almost immediately after he had another similar attack, and this was repeated ten or twelve times. One of these proved fatal the same evening. Stimulants, when administered, seemed rather to aggravate the distress.

Post-mortem examination.—Slight adhesions of the right pleura —none of the left. Trachea and bronchi filled with purulent matter. Both lungs very voluminous, congested, emphysematous, and were very imperfectly crepitant. On incision, thick purulent matter exuded freely from the cut ends of the bronchi.

An aneurysm, about the size of a large orange, was found coming

off from the ascending portion of the arch of the aorta, towards the right side. It was situated in the apex of the thorax, chiefly behind the first and second costal cartilages on the right side, and was adherent to the apex of the right pleural cavity. Backwards it lay on the trachea, which tube, just above its bifurcation, was much compressed and flattened.

Remarks.—This patient's death was the result of apnœa, of which the aneurysm was, although the exciting and principal, not the sole cause. Bronchitis secondary to and depending on the pressure of the aneurysmal tumour, exasperated the symptoms and precipitated the fatal result. Dr. Pollock, 16*th of November*, 1858.

---

4. *Constriction of the Thoracic Aorta.*

This resembled very much the hitherto recorded cases of this remarkable malformation, both as to the site of the contraction, and the consequent vicarious circulation. In some cases it has been found accidentally and at advanced age, while in others it has appeared to have led to a premature death. In the present case, the heart was otherwise malformed. The patient was J. D., æt. 22, under Dr. Rees, in Guy's Hospital. He was a well-developed, strong-looking young man, and his mother stated that he had good health until about the age of puberty, when having obtained work for him in the Docks, it was found he was unable to perform any great manual labour, and a light position was procured for him. He thus continued until 20 years of age, when he joined the militia, but he soon found the exercise too distressing for him, and was obliged to leave the service; he, however, continued his employment at the Docks until two weeks before admission into the Hospital, or until six weeks before his death. (On asking the mother if she had ever had rheumatic fever, she stated that she had at one of her pregnancies, but could not remember the date.)

On admission the patient was evidently suffering from heart disease, shown by the dyspnœa, œdema of legs, increased dulness over cardiac region, indicating enlargement, &c.; at the same time there was no bruit, although the action of the heart was

tumultuous, and the pulse had a peculiar fluttering or throbbing character. After death, the appearance of the body and different organs was that seen in heart disease; it was equally well-developed in all parts, presenting no peculiarities. The heart was much enlarged in all its proportions, but the normal shape maintained, the hypertrophy of the right side being proportional to that of the left; the arch of the aorta and its vessels were as usual, but the former gradually narrowed into a conical shape, until it ceased altogether just below the left subclavian artery, or rather, upon looking at the arch and thoracic aorta together, it appeared as if a ligature had been placed around the vessel at the site of the ductus arteriosus. The constriction, however, was not complete, as there was still a communication which would admit an ordinary probe. Below this the thoracic aorta was small, but the vessels from it large, showing that blood passed by them through means of inferior intercostal, into the trunk, and not from it. The abdominal aorta and iliacs were also small, but after receiving the large epigastric, they become suddenly larger, as this vessel conveyed blood by the internal mammary to the lower extremities. Other branches from the subclavian were of large size, but could not be dissected to their termination. The aortic valves were only two in number, and at the bottom of one of them a slight ridge could be seen, indicating a previous division between them. At the junction of the two valves there was another small valve, but this appeared rather as a new formation, than as remains of the normal structure. At the intermembranous septum, near the valves, there was a pouch projecting into the right ventricle, and all around, the endocardium was much thickened. The mitral valve was also malformed; the muscular columns being altogether wanting, and thus the cords were attached all around the auriculo-ventricular orifice.

Remarks.—These malformations within the heart constituted the interest of the case, and would make it appear that this form of constriction of the aorta was allied in its mode of formation to other congenital affections of the aorta, and not due simply to some local and inordinate action at the site of the ductus arteriosus after birth. It was a difficult point to determine what was the cause of the fatal result in this case, as the constriction

and malformation of the valves had been from infancy. Probably a certain amount of enlargement of the heart had been always present, and that this had of late become inordinate from manual exercise, and at last unfitted the organ for its work.

Dr. WILKS, *7th of December*, 1858.

---

5. *Malformation of the Pulmonary Valves.*

M. L., æt. 18, was admitted into Guy's Hospital for phthisis, of which she shortly died. She was a girl of small stature, was suffering from acute disorganization of both lungs, and had considerable lividity of the surface of the body. She never had any illness previous to the present pulmonary symptoms, but had been able to follow her occupation as a domestic servant. A few weeks before admission the catamenia first appeared, and at the same time hæmoptysis, cough, dyspnœa, &c. The pneumonic phthisis ran a very rapid course, and the girl died about three months after the first symptoms. The most remarkable feature of the case was the existence of a bruit heard over the valves of the heart; this was superficial and was traceable more in the direction of the upper and left side of the sternum; from these circumstances it was considered to be a form of bruit sometimes heard in phthisis, and which is believed to be due to an obstruction of the branches of the pulmonary artery, arising from the consolidated tissue, or perhaps from tuberculous disease in the bronchial glands; this also accounted for the lividity of the face and hands; although the subject of the bruit was discussed in reference to this obstruction in the arterial pulmonary branches, still it was considered that it might have its origin at the mouth of the vessel.

Post-mortem examination.—After death, the lungs were found extensively disorganized by acute pneumonic or strumo-pneumonic deposit; there were no miliary tubercles present either in the lungs or any other part of the body. The heart was below the average size of that of an adult, but the patient was also a person of little stature. It was of a roundish shape, and resembled very much the heart of a fœtus. This was due to the great hypertrophy of the right ventricle, which was equal in size to that of the left, but its walls were in many parts thicker. At the mouth of the pulmonary artery the valves were seen to be replaced by a conical or funnel-

shaped membrane, having an opening at its summit which would just admit a crow-quill, and whose edge was fringed with some very minute firm vegetations. An examination of this funnel-shaped process showed that it had been formed by the union of valves which had once existed, for two ridges could be seen marking the lines of union, and on one side the cone was adherent to the pulmonary artery marking the remaining junction. The aortic valves were only two in number, and on looking into the interior of the larger one a raised line could be seen indicating the point of union of two former valves. The foramen ovale was widely open, being an inch in diameter; ductus arteriosus quite closed. Auricles equal in size and thickness.*

Remarks.—The case was interesting as an example of the effects of endocarditis and union of the valves in fœtal life, for the fact of changes being found on both sides of the heart left this explanation without a doubt; it having been proved to demonstration that two valves will unite and run into one as effects of adhesion, it follows that the change in the pulmonary valves also had such a cause, and that this occurred in fœtal life is shown by the open foramen ovale. It is interesting to observe the difference of effects of adhesion of the sigmoïd valves on the two sides of the heart; the fusion of two into one on the aortic side, and the union of all into a conical membrane on the right. This difference, however, is not universal, since a union of all the valves into one piece may sometimes be met with at the aortic orifice.

Dr. Wilks, *7th of December*, 1858.

---

6. *Hydatid Tumour in the Apex of Right Ventricle of the Heart.*

S. S., a single woman, stout and florid, æt. 23, was admitted into King's College Hospital, the 23rd of December, 1857.

She stated that her health was good till four years before, when she was laid up with pleurisy, accompanied by what was supposed to be inflammation of the kidneys; and that since that

* A case of malformation of the pulmonary valves, not unlike this in many respects, may be seen, related by Dr. Ogle, at p. 69 of Vol. V. of the Transactions; but in that case the foramen ovale was not patent.

illness she had been constantly troubled more or less with cough, shortness of breath, and palpitation.

Two years before her admission to the Hospital, she had a second attack of pleurisy. Since this second illness her health had declined, and with her cough she had expectorated phlegm, which was often streaked with blood. Nine days before she entered the Hospital swelling of the legs came on.

On her admission to the Hospital, she complained of cough and shortness of breath, and her feet were slightly œdematous. While lying still in bed she had no pain or urgent symptoms, but slight exertion caused considerable dyspnœa. With her cough, which was very troublesome, she spat up mucus, partly clear and partly opaque, streaked here and there with blood. On listening to the chest, a systolic rasp-sound was heard over the base of the heart, and extending thence a little upwards and to the right. The impulse of the heart was slight, and the pulse small and feeble. There was crepitation on both sides of the chest behind.

The urine, which was turbid with deposit of lithates, contained a small quantity of albumen.

On the 28th of December, it was noted that the abnormal systolic heart-sound was much less rough; and on the 30th that no morbid bruit could be heard.

From that time till the poor woman's death, though I often listened for that purpose, I never heard any distinct morbid sound with the heart's beats.

On the 9th of January she expectorated nearly half-a-pint of blood, mixed with mucus; and on the 27th of January she again spat a considerable quantity.

She was constantly distressed by cough and dyspnœa, and spat up mucus, generally somewhat tinged with blood. She left the Hospital on the 24th of February, and, on account of increased distress in breathing and a recurrence of considerable hæmorrhage, she was reädmitted on the 3rd of March.

On the 14th of March, œdema of the legs, which had disappeared for some time, came on again. The urine then contained no albumen.

On the 12th of April, she complained much of pain shooting through the left side of the chest.

From this time she often complained of intense pain at the præcordia. The præcordial space dull on percussion was unusually extensive; but no unnatural bellows-murmur was heard. The impulse of the heart was tolerably strong, and its action throughout was regular. The dropsical swelling of the legs increased, and ascites came on: breathing was carried on with much difficulty and distress: and, on the 4th of May, she died.

Post-mortem examination.—Both lungs were found united to the pleura costalis by old adhesions. The pericardium contained about an ounce of serous fluid. Its layers posteriorly were glued together by tolerably old adhesions. The heart was of very irregular shape, flattened anteriorly and bulging posteriorly. Its irregular shape was owing to a hydatid tumour, about the size of an orange, situated in the apex of the right ventricle, and projecting into its cavity. The right auricle and ventricle were filled with clotted blood; the left chambers of the heart were healthy. There was no disease of the valves.

Under one of the laminæ of the tricuspid valve, a small flaccid hydatid was found unattached. In the pulmonary artery, immediately above the valves, an unbroken hydatid, rather more than half-an-inch in diameter, was found; and in the further course of the artery, before its subdivision, there were several other smaller hydatids.

On tracing the branches of the pulmonary artery, several clusters of hydatids, and the collapsed skins of hydatids—ranging from one-eighth to one-fourth of an inch in diameter—were discovered in them. These hydatids were exclusively confined to the left lung, and chiefly to the upper lobe, one small cluster only being found in the centre of the lung, and one in the lower lobe. These clusters of hydatids were enveloped in pale fibrin, but not contained in organized sacs. The lower lobes of both lungs were carnified, but still crepitated slightly under the fingers. The pulmonary veins and the bronchial tubes contained no hydatids.

The abdominal organs and the brain, and the principal venous trunks of the lower extremities were next carefully examined; but, with the exception of slight fatty degeneration of the liver, some irregularity of the surface of the right kidney, and general venous congestion, nothing abnormal was detected.

On examining one of the smaller hydatids taken from the pulmonary artery, I found it to contain very perfect echinococci.

The hydatid tumour in the apex of the heart was stuffed with hydatids, and it was evident, that the hydatids found in the right ventricle and in the pulmonary artery, had escaped from it.

Dr. Budd, 21*st of December*, 1858.

---

7. *Cured Aneurysm of the Arch of the Aorta.*

D. M., a baker, æt. 54, was admitted into St. Thomas's Hospital on the 13th of August, 1850. He stated that six months before he had been attacked with vomiting, followed by icterus, which subsided after a month's medical treatment; but that he had never regained his usual strength. At the time of admission he complained of great debility, but no pain. His frame was very emaciated, his countenance pale, his legs slightly anasarcous. There was no pulmonary affection. A bruit was audible over the apex of the heart, but the organ acted regularly. The urine was not albuminous. He died five days after admission.

Post-mortem examination, the day after death.—Legs œdematous. The left pleura contained about a quart of serum, the right a pint, together with numerous old adhesions. The lungs were congested, and a little emphysematous. The bronchial tubes were congested, and contained much viscid mucus. The pericardium presented a few milk patches, and contained a little serum. The heart was somewhat enlarged, and its valves appeared healthy. The ascending and transverse portions of the arch of the aorta were somewhat dilated, and the walls roughened by atheromatous and earthy deposit. Immediately below and behind the origins of the great vessels was a thimble-shaped aneurysm, measuring about an inch in its long diameter or axis. Its walls were formed by the external arterial tunic, the middle coat ceasing at its base. Its cavity was nearly obliterated by concentric coagula; those more recently deposited forming a somewhat irregular mass, but loosely connected with the others, and encroaching to some extent upon the calibre of the artery. A second aneurysm existed at the lower and right lateral part of the

descending arch. It was globular, and an inch and a half in diameter. Its walls were formed, as in the former case, by the cellular coat, the middle one ceasing round the aperture of communication, which was circular, and about half-an-inch in diameter. Posteriorly, it encroached upon the vertebræ, which it partially eroded, and to which it was firmly adherent. Its cavity was entirely obliterated by lamellar coagula; the layers forming smaller segments of larger circles in proportion to the recency of deposition. The most recent of all entirely blocked up the mouth of the aneurysm, and were on a level with the parietes of the artery.

All the abdominal viscera were healthy.

Dr. Bristowe, *4th of January*, 1859.

---

8. *Case of Aneurysm of the Abdominal Aorta, in which death was produced by Accumulation of Effused Blood around the Lower Extremity of the Œsophagus, and consequent obstruction.*

E. P., a wheelwright, æt. 33, was admitted under my care on the 21st of September, 1858. He stated that twelve months previously he began to suffer from throbbing pain in the lumbar region, and shooting pains in the hips; that ten weeks ago he first perceived pulsation in the epigastric region, with intermittent numbness and chilliness in the legs, attended by obstinate constipation; and that about seven weeks since he was attacked with severe burning epigastric pain, which compelled him to keep in the supine posture. The above symptoms had continued with progressive aggravation up to the time of admission; and in addition to these he then complained of loss of strength and appetite, with occasional nausea. He suffered from headache, and was much emaciated. Tongue clean; pulse 84, a little jerking.

The condition of the thoracic viscera was carefully explored, and appeared to be perfectly healthy. A deep-seated, rounded, hard, pulsating tumour, apparently about as large as an orange, could be distinctly felt in the epigastrium. It was dull on percussion, and its dulness was continuous on the one hand with that of the liver, and on the other with that of the heart. A harsh

bellows-murmur, synchronous with the pulse, was audible over every part of the tumour, and slightly in the corresponding part of the back. It ceased abruptly, however, at the edges of the tumour, and at the margin of the left ribs was at once replaced by the healthy heart's-sounds.

He remained in the Hospital up to the 28th of October without any material change in his symptoms, beyond the supervention latterly of severe pain down the inner part of the right thigh. On the evening of that day he had a sudden fainting fit, which lasted about five minutes and was succeeded by vomiting. From that time he rapidly sunk. The local phenomena continued the same; but the pulse got extremely small, feeble, and rapid (between 120 and 130), the face sunken, pale, and painfully anxious. He became perfectly unable to swallow either solids or liquids, so that up to the day of his death not a mouthful of anything was received into his stomach. This did not depend on want of desire, for though not hungry he was thirsty; nor upon irritability of the stomach, for the rejection of food was not the result of vomiting, but, as he himself described it, it depended on some impediment at the lower part of the œsophagus, in consequence of which any attempt to swallow was followed at the end of a second or two by the regurgitation of what had been taken. The tongue became furred, the mouth extremely clammy, and the right hip benumbed. The bowels continued constipated, the urine moderate in quantity, and micturition easy. He died exhausted on the 5th of November. The treatment varied at different times, and need not be detailed. It may be stated, however, that during the last few days of his life, nutrient enemata of beef-tea, and wine or eggs, were administered night and morning, but without any apparent benefit.

Post-mortem examination.—Body much emaciated.

Chest.—Pericardium healthy. Its posterior and lower part was protruded forwards by a rounded mass, which was seated in the lower part of the posterior mediastinum, and appeared at this stage of the dissection to be as large as a hen's egg. Heart healthy. Right pleura healthy. Right lung crepitant and healthy; but a little extravasated blood radiated from the root along the subserous tissue for a distance of two or three inches. The left pleura contained between half-a-pint and a pint of turbid

fluid, and its surface was lined by a thick, soft, dirty-looking layer of recently deposited lymph. This was most abundant on the inner and lower surface of the parietal layer—that part which corresponded to the lower portion of the posterior and middle mediastina. The left lung was small, and in great measure airless from pressure.

Abdomen.—On laying open the abdominal cavity the peritoneum appeared healthy; but the subserous tissue of the stomach was infiltrated with blood, and blood was effused between the layers of the great omentum, into the upper part of the mesentery, and around the pancreas and neighbouring organs. Behind the stomach and connected with the spine, was discovered a tumour about as large as a moderate-sized cocoa-nut. The parts were now removed in mass and examined carefully. The aorta was laid open, and found to be irregular throughout from atheromatous deposit; and about three-quarters of an inch above the cœliac axis, but behind and to the right, was an orifice an inch and a half long, and of irregularly oval form, which was found to communicate with an aneurysm—the tumour before spoken of. This was irregular in shape, was situated chiefly to the right of the aorta, but extended a little to the left between it and the vertebræ, of which the last two dorsal and first lumbar were deeply eroded. Its parietes were directly continuous with those of the aorta, and in the greater part of their extent appeared to the naked eye to consist of the same kind of tissue. It contained a considerable amount of recent clot, and was lined by a little laminated fibrine.

The aneurysm presented two distinct diverticula of evidently very recent formation, each about as large as a goose's egg, and nearly completely filled by partially laminated clot. One extended downwards into the substance of the right psoas, the expanded muscular tissue, lined by a little recent fibrine, alone forming its parietes. The other passed upwards into the posterior mediastinum to the right of the œsophagus and aorta, producing the tumour before alluded to as occupying that situation. This latter contained, in addition to laminæ, much recent coagulum, and its continuity with the parent cavity was completely interrupted by a tough plug. It had no distinct walls, but was bounded in most directions by dense tissue, con-

sisting of blood effused and coagulated in the cellular tissue of the part. From this diverticulum as a centre, blood, now coagulated, had been poured out in various directions; upwards along the aorta and œsophagus, and into the roots of the lungs; round the cardiac orifice of the stomach forming an almost complete ring of coagulum three-quarters of an inch thick; over the whole surface of the stomach, but chiefly along its curvatures; into the greater and lesser omenta, and upper part of the mesentery; and into the cellular tissue of the upper part of each lumbar region.

The œsophagus was now laid open. The upper part was found healthy; but its lower three inches were displaced, flattened, and somewhat obstructed by the upper prolongation of the aneurysm, the walls in this situation presenting a greenish-yellow hue, and being exceedingly soft and lacerable. Near the centre of this part was an irregularly oval patch partially detached from the surrounding membrane; and its lower part—that immediately above the cardiac orifice—had become so thin, soft, and disintegrated, that it was impossible to say whether what was left was really the mucous membrane or not. This latter portion of the œsophagus lay to the left of, and in close contiguity with the upward prolongation of the aneurysm; and on passing the finger into the latter from below, the two were found to be separated by an excessively thin layer, which consisted chiefly of a soft fibrinous film, but partly of the remnants of the sloughy œsophageal walls. A communication between the two was I believe really established, the separation being solely due to the laminated fibrine of the aneurysmal pouch. The sloughy condition occupied the entire periphery of the œsophagus; and on the left side had extended through to the pleura, and had evidently caused the pleuritis which was found to exist there. The partition wall between the œsophagus and pleura was very thin and soft, but not actually perforated. The blood coagulated around the cardiac orifice by the pressure which it produced, completely obstructed the entrance to the stomach. The stomach was much contracted, and empty. Liver, spleen, pancreas, intestines, and supra-renal capsules healthy. The kidneys were large and somewhat succulent.

Remarks.—The above case furnishes an instructive example of the mode in which aneurysms tend to open upon mucous surfaces,

namely, by gangrene; and it shows further that the gangrene need not be confined to the portion of the membrane directly involved in the spread of the aneurysm, but may extend to a considerable distance beyond its presumed seat of origin. The most interesting point, however, to myself, was the sudden and complete obstruction of the œsophagus during the last few days of life in connection with its cause as revealed *post-mortem*. The patient had been going on without any material change until the 28th of October. On that day he was attacked with symptoms which excited the suspicion that a rupture of the aneurysm had occurred; the anticipated immediate results, however, did not follow; but in their place complete obstruction of the œsophagus, of which the patient died at the end of a week. The autopsy revealed a satisfactory explanation of these phenomena. There was sufficient evidence to show that rupture had really taken place at the suspected moment, but that the rupture had been into the sub-peritoneal tissue, and the hæmorrhage therefore comparatively little and speedily arrested. It was further manifest that though the amount of hæmorrhage had not been sufficient to produce immediately fatal consequences, its situation had been such as to lead somewhat more slowly to the same result, for it had spread into and coagulated in the tissues around the cardiac orifice, and had so far compressed and closed it as to form an insuperable bar to the passage of food. This inability to swallow was aided latterly, no doubt, by the gangrenous and therefore paralyzed condition of the walls of the lower part of the œsophagus.

The case just recorded has called to my recollection an almost parallel one, in which the rupture of an abdominal aneurysm into the sub-peritoneal tissue was followed by complete obstruction, similarly produced, in the duodenum. The death of the patient, however, was so rapid that none of the symptoms due to duodenal obstruction had time to manifest themselves.

J. B., æt. 23, an excavator, was admitted on the 19th of October, 1852, with abdominal aneurysm, traceable to an accident which had occurred four years previously. He died on the 10th of November following from rupture and effusion of blood into the peritoneal cavity. At the *post-mortem* examination several pounds

of coagulum were found in the cavity of the abdomen. A tumour about the size of a large orange was discovered in the lower part of the lumbar region, situated chiefly between the layers of mesentery belonging to the ileum, and having a portion of the latter sessile upon it. In relation to the upper part of this tumour was a large quantity of recently-coagulated blood, which had been effused into the sub-peritoneal tissue, and had accumulated in the upper part of the mesentery, in the layers of the great omentum between the transverse colon and the spine, in front of the pancreas and around the third part of the duodenum. The latter was, in consequence, much compressed and very decidedly obstructed, for not only was there considerable impediment to the passage even of the finger, but it was observed that the stomach and upper part of the duodenum were filled with the fluid, while the jejunum immediately beyond the constriction was collapsed, and contained merely yellowish mucus. The laceration by which the blood had escaped into the peritoneal cavity appeared to be seated in the transverse mesocolon. On further examination the tumour before spoken of was ascertained to be an aneurysm, arising in the aorta, opposite the fourth lumbar vertebræ, and causing slight erosion of that bone. It was pretty nearly full of coagulum, partly old and partly recent, and communicated by an oval orifice, about one inch and a half long, with the aorta, which vessel was somewhat irregular and atheromatous, in its neighbourhood.

The abdominal and thoracic viscera were all healthy.

Dr. Bristowe, *4th of January*, 1859.

---

9. *Malformation of the Heart, with Cyanosis.*

E. R., æt. 6½ years, was apparently healthy during infancy, with the exception that when she held her breath under the influence of passion she became exceedingly blue. The surface did not, however, permanently assume a blue tinge until the last two years of her life. During the winter of 1857-8 she had a succession of catarrhal attacks, accompanied with extreme dyspnœa, which recurred at intervals subsequently. During the last six months she suffered almost constantly from dyspnœa, cough, and expectoration of frothy mucus. On several occasions shortly before

death she suddenly fell powerless, at the same moment uttering a scream and becoming pale. The cardiac dulness was unnaturally extended, but the heart's-sounds were unaccompanied by any bruit. This condition lasted for a few moments, and on its passing off the blueness returned with increased intensity. In one of these paroxysms she died.

Post-mortem examination.—The heart weighed three ounces and a-quarter. The right auricle was remarkably dilated, and the foramen ovale sufficiently patent to allow the little finger to pass with ease. The auriculo-ventricular orifice was large enough to admit two fingers. The wall of the right ventricle was thicker than the left in the proportion of three to two. The tricuspid valve consisted of two curtains so placed that their auricular surfaces coincide completely. Of these the larger was wholly attached to the outer wall of the ventricle, and the smaller to the septum. The right and left ventricle communicate with each other by an opening in the upper and anterior part of the septum, large enough to admit the little finger. The upper margin of this opening is formed by the fibrous ring of the tricuspid valve, and from this margin a curtain hangs across the opening, the position of which corresponds to that of the wanting anterior division of the valve. The edge of this curtain being unattached, it flaps freely backwards and forwards in the opening. The pulmonary artery is constricted at its origin to such a degree as barely to admit the point of a probe. On dividing the constriction, the rudiments of the semi-lunar valves can be distinguished. The artery immediately dilates into a vessel as large as a crowquill, and gives off the right pulmonary branch in the usual position. Its continuation (the left pulmonary artery) having been unfortunately divided in removing the organ, it is impossible to determine whether or not the ductus arteriosus was open during life.

Permission was refused to remove the lungs or any other organ, excepting the heart. Dr. Sanderson, *4th of January*, 1859.

---

10. *Malformation of the Heart. The Pulmonary Artery impervious at its origin, &c.*

The subject of this malformation, a female child aged nine

months, was brought as an out-patient to St. Bartholomew's Hospital on the 15th of October, 1858. She was small but fairly nourished. Her complexion had an ash-grey tint, the hands and feet being more dusky than other parts, but the ordinary characters of cyanosis were not strongly marked; and the last phalanges of the fingers were not unusually large. The mother stated that the child had a cough, and that in the fits of coughing its face became very dark. The same change of colour occurred when she cried, and had done so ever since her birth. There were no symptoms of pyrexia, but the breathing movements were rapid and laboured with marked retraction of the lower end of the sternum, and lower costal cartilages at each inspiration, and, on auscultation, abundant small mucous crepitation was heard throughout the lower lobes of both lungs. The impulse of the heart was excessive, and felt over a wide space. No murmur could be detected over the pulmonary aorta or the aorta, but over the whole cardiac region below the level of those vessels a pretty loud bellows-murmur attended the systole of the ventricles. The child was seen four times subsequently; namely on the 18th, 21st, 25th, and 28th of October. No change in her symptoms was observed, except increasing dyspnœa and weakness. She died on the 30th of October, and on the following day an examination of the body was made.

On *post-mortem examination*, when the chest was opened, the heart was seen to be of much larger size than natural. An incision being made into either ventricle, and a probe introduced, it was found that the right as well as the left ventricle communicated directly with the ascending aorta. The heart and the large vessels connected with it were then removed for the purpose of a more exact examination, which revealed the following state of the parts: —The right auricle and the right ventricle were both of abnormally large capacity; and their walls hypertrophied. The foramen ovale was *patent*. The septum of the ventricles was deficient at its upper part, an opening being left which admitted the tip of the little finger, and the aortic orifice was placed so as to communicate as directly with the right as with the left ventricle. No opening into the pulmonary artery existed. The aorta was very wide in the ascending portion of its arch, then tapered till it was joined by the ductus arteriosus, when it suddenly became much smaller. Its

coats were of the natural thickness. The trunk of the pulmonary artery commencing by an impervious *cul-de-sac* contained at its origin a small partially decolorized coagulum of blood attached to its rudimentary semilunar valves. Its coats were as thin as those of a vein, and its diameter was not larger than of a crow-quill. The ductus arteriosus was rather wider, and its coats thicker, and the right and left pulmonary arteries, both from their direction and their structure, appeared to be branches of the arterial duct coming from the aorta, rather than of the impervious vessel coming from the heart.

The lungs presented no morbid condition except congestion of their posterior parts, and extensive collapse of the lower lobes.

Dr. Baly, *4th of January*, 1859.

---

11. *Rupture of the Aortic Valves by Violence.*

A dock labourer, æt. 36, was admitted into Jacob's Ward, St. Thomas's Hospital, on the 4th of November, 1858. He stated that he had been ill for two months, and he ascribed his indisposition to a blow which he had received on the left side. He was pulling strongly at a sugar-hogshead, when his hand slipped, and struck him on the side. He had severe pain at the time and felt faint; the symptoms continued all the day, and in the evening he had difficulty of breathing. The pain was relieved by the application of a mustard poultice, but the symptoms never entirely left him. About five weeks after, he became so much worse as to apply as an out-patient at St. Thomas's Hospital, and he continued to attend for three weeks, and suffered at that time from dyspnœa, pain in the præcordial region, irregularity of pulse, œdema of the lower extremities and puffiness of the face. There was deficiency of resonance on percussion on the left side of the chest and the respiratory sounds were feebly audible. There was no cardiac murmur, but the action of the heart was irregular. He had never had rheumatic fever or any other serious disease and was in fair health up to the time of the occurrence of the accident.

The following notes were taken after his admission into the Hospital on the 11th of November.

He still has difficulty of breathing, pain sometimes very severe in the region of the heart, and palpitation. His face is puffy but the swelling of the legs has subsided. The urine has a specific gravity of 1013 and is not albuminous. He breathes with great effort and the expansion of the chest is not proportionately free. The left side of the chest is entirely dull on percussion from a high level, and the vocal thrill is nearly abolished over the dull space. There is some bronchitic rhonchus on the right side, and on the left respiration is attended by a somewhat stridulous sound and is very feeble lower down. The same stridulous sound is heard distinctly at the root of the left lung, and less so at the root of the right. The jugulars pulsate on each side, and there is a widely extended pulsation in the præcordial region. The cardiac dulness on percussion commences below the fourth cartilage, and extends laterally from the sternum to beyond the line of the nipple. There is a to and fro murmur audible over the whole præcordial space. It is heard along the upper part of the sternum in the course of the aorta; the systolic murmur is also heard very distinctly below the nipple, and thence towards the left axilla. There is very obvious pulsation in the arteries of the extremities, and a characteristically regurgitant pulse, the blood being shot rapidly into the artery with the systole of the heart and as rapidly disappearing with the diastole. The left radial pulse is much stronger than the right.

He was directed to take the hyoscyamus and Dover's powder pills at night, with iodide of potassium and tincture of hyoscyamus during the day.

On the 22nd, it is reported that his breathing has been much better since he has been in the Hospital, and he has not had the severe pain in the region of the heart. The left side of the chest is still less resonant than the right, and the breathing is there less audible, and is attended by sub-crepitation. The to and fro murmur is still heard at the base of the heart and in the course of the aorta, and the systolic murmur is distinctly audible at the apex. The pulse is decidedly regurgitant, and the left stronger than the right. Morphia was ordered to be taken at night, and the dose of iodide of potassium was increased.

On the 25th, he was so much relieved that he applied

to be allowed to leave the Hospital, and was in consequence discharged. He, however, continued to attend as an out-patient, and from the first got worse. On the 13th of December, he was reädmitted, and his breathing was then so difficult that he could not lie down. His countenance was anxious, the eyes glassy, tongue covered with a dense white fur, the right pulse scarcely perceptible, the left larger and fuller. He had a severe cough, and spat massive, airless, muco-purulent sputa; on listening to the chest, the respiratory sounds were very feeble, but a stridulous sound accompanied the inspiration on both sides, and there was marked sub-crepitation on the left side. The heart's-sounds were very feeble, and the murmur could not be heard. He was directed to take the aromatic spirit of ammonia with compound sulphuric ether and hyoscyamus, but the dyspnœa increased; he became collapsed, and died on the 17th.

The *post-mortem* examination was performed by Dr. Bristowe. The brain was not examined.

Both pleuræ presented numerous very firm adhesions, especially the right, which was almost obliterated. The left contained about half-a-pint of serum. The lungs were congested, œdematous, and very sparingly crepitant throughout. The larynx, trachea, and bronchial tubes were healthy, apparently nowhere compressed, but containing a good deal of frothy serum. The bronchial glands were somewhat large.

The pericardium was healthy. The heart large, weighing twenty-three ounces, avoirdupois. The auricles were dilated and filled with partly decolorized clot, and the ventricles also contained a small quantity. Both ventricles were hypertrophied and dilated. The cavity of the left ventricle especially, was considerably increased in size, and its walls were thicker than natural. All the valves were healthy except the aortic, of which the left angle of the posterior segment was torn from its attachment, so as to allow the edge of the valve to be retroverted and free regurgitation to take place from the aorta into the ventricle. The other valves were perfectly flexible and presented no roughness or irregularity.

The liver was attached by old adhesions to the diaphragm, and was in a nutmeg condition. The spleen was somewhat pulpy, and the capsule rather thick; the pancreas, stomach, intestines

and supra-renal capsules were healthy. The kidneys were firm, pale and waxy-looking, but presented under the microscope a healthy appearance.

WOODCUT 4.

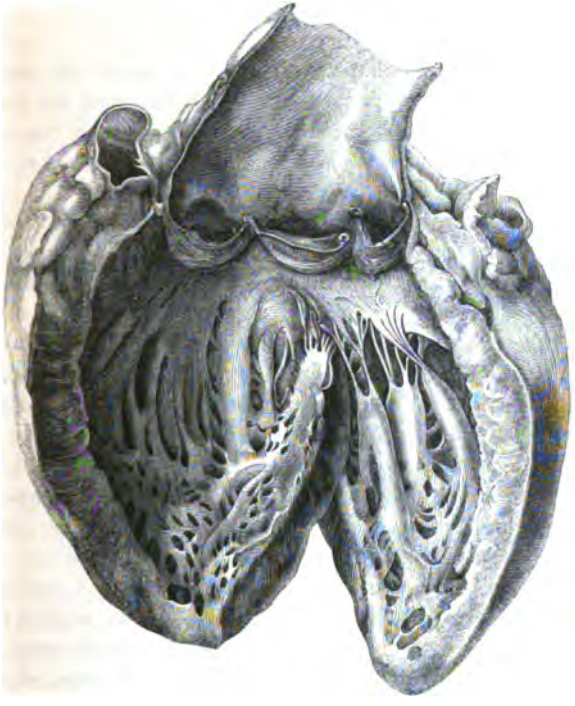

Represents the heart laid open to show the torn and retroverted aortic valve, and the thickened muscular walls. Half the size of nature.

Remarks.—1. When the patient was admitted into the Hospital, it was evident that he laboured under bronchitis with obstructive and regurgitant disease of the aortic orifice, and the history of the case indicated that the aortic valves had sustained injury at the time when the accident occurred. It was suspected that there existed some dilatation or aneurysm of the aorta, producing pres-

sure on the trachea or bronchi, and occasioning the difference between the two radial pulses, and that there was also regurgitation through the left auriculo-ventricular aperture. The former portion of the diagnosis was fully confirmed by the post-mortem examination—but the cause of the difference between the radial pulses, and of the stridulous inspiratory sound was not ascertained.

It is doubtful in what way the laceration of the angle of attachment of the posterior semilunar valve occurred, but it seems most probable that it was occasioned by the shock of the sudden loss of hold on the sugar hogshead, rather than that it occurred from the severe blow on the chest which followed.

2. That the cardiac valves, though not previously diseased, are liable to injury from external causes has been known to Pathologists since the time of Corvisart and Marat, and cases have been related by Bertin, Legendre, and Mr. Allen Williams, and referred to by Dr. Townsend. A notice of the subject was inserted by Dr. Latham in his *Clinical Lectures*, published in 1846, and in the same year,—at the first meeting of the Society,* a paper was read on the subject by Dr. Quain, and subsequently published in the *Edinburgh Journal*, detailing the particulars of a case which had fallen under his notice, two others reported to him, and the case of Dr. Bence Jones previously published by Dr. Latham. In 1852, Dr. Peacock communicated to the Society a case which occurred in his practice at St. Thomas's Hospital,† and in the following year published a short Memoir on the subject in the *London and Edinburgh Monthly Journal of Medical Science*.‡ In this paper he collected the particulars of eleven cases, of which six were instances of rupture of the aortic valves, four of the mitral and one of the tricuspid valves.

The present case corresponds in its general features with those previously recorded, and it adds another to the instances in which the aortic valves, obviously most exposed to injury, have been the seat of rupture. In several of the previous cases the heart was found to have become very greatly enlarged, most probably after the occurrence of the accidents. Thus, in Dr. Quain's patient, who lived two

* Path. Trans., 1846-47—1847-48, p. 63.
† Path. Trans., 1850-51—1851-52, p. 71. ‡ Journal, 1852.

years, the heart weighed twenty-two ounces and a-half; in Dr. Peacock's, who survived twenty-seven months, it weighed seventeen ounces and three-quarters. In the present case, which proved fatal at a much earlier period than either of the others—or in three months and a-half—the heart was still more enlarged, and weighed twenty-three ounces; but it was probably considerably hypertrophied, before the occurrence of the accident. The duration of life in cases of rupture of the aortic valves from accident or violent efforts has varied considerably. The cases referred to by Dr. Peacock in his former memoir had a range of from three weeks to twenty-seven months. In every instance the accident, as would be anticipated, occurred in persons of middle age, or from twenty-six to fifty-four years of age, and all the patients were males.

Dr. Peacock, 18*th of January*, 1859.

---

12. *An Injected Preparation of a Specimen of Obliteration of the Thoracic Aorta.*

This specimen was taken from the body of a man of remarkable muscular development. The obliteration occurs at the termination of the aortic arch, just after the origin of the left subclavian artery. The innominate and left subclavian arteries are much enlarged, being almost twice the normal size. The internal mammary arteries are four times the normal size, and communicated very freely with the deep and superficial epigastrics. The deep epigastrics were larger than the external iliacs, and supplied the greater part of the blood to the lower extremities. The superficial epigastrics were so large and tortuous as to render the abnormality of the arterial distribution evident before the body was opened. Those of the right side were rather larger than those of the left.

The superior intercostal branches of both subclavian are six times the normal size, and form a complicated mass of anastomosis with the first four aortic intercostals, both in front of the ribs in the interior of the thorax, and under the deep muscles of the back. The upward branches of the subclavians are normal.

The descending aorta below the obstruction is smaller than usual, and had evidently been filled by the stream of blood through the intercostal anastomosis. The greater part of this stream was expended in the abdomen and pelvis. The supply to the lower extremities, on the other hand, had passed through the internal mammaries and epigastrics. The obstruction was apparently complete, and appeared, on close external dissection, as if a piece of packthread had been tied tightly round the artery. The coats were not thickened, and presented no appearance of diseased alteration at the obstructed point, nor indeed in any other part of the body. The heart was somewhat enlarged. This condition of the circulation had been present evidently for a long period, and the man died of a disease nowise connected with it. That the cause of the obstruction in this class of cases is uniform, is shown by their always occurring in one place, *viz.*:—at the termination of the aortic arch. On referring to the condition of this part of the aorta in the fœtus, it will be seen that—immediately before the junction of the ductus arteriosus with the aorta—a great diminution of the calibre of the latter takes place after the departure of the left subclavian branch, while the more prominent and direct tubular continuity, is that from the pulmonary artery through the ductus arteriosus with the descending aorta. This constriction of the aorta at the termination of the arch is very remarkable in many infants, even at the full period of uterine development.

The constancy of the seat of obstruction to this particular point in this class of cases—the even regularity, flexibility, and thinness of the obstructive partition, and the pliability and healthy condition of the arterial coats, taken in connection with the appearances in the fœtus above-mentioned, rendered it difficult to avoid the conclusion, that the cause of the abnormality was arrest of development in the narrowed portion connecting the aortic arch with the descending aorta, between the separation of the left subclavian, and the junction of the ductus arteriosus. This supposition is strengthened in the case exhibited, by the presence in the same subject of another arrest of development in the penis, producing congenital hypospadias—absence of the frænum præputii, and the formation of an elongated pouch or false urethra in the situation of the fossa navicularis—a descrip-

tion of which will be found in another part of the present volume of the Transactions. The subsidiary or complemental connection of the aortic arch with the trunk and lower extremities by means of the internal mammaries and superior intercostals, joining respectively with the external iliacs and aortic intercostals, are interesting in relation to their developmental changes and homological relations. Mr. J. Wood, 1*st of February*, 1859.

---

13. *Ulceration of the Internal Jugular Vein.*

This specimen was obtained from a boy, æt. 8, who was the subject of scarlet fever. Towards the close of the fever an abscess formed in the right side of the neck, about the angle of the jaw. On the abscess being opened a large amount of sanious pus was discharged, and the discharge continued for three or four days. A swelling then formed about the same site, which burst and discharged blood and serum. It again formed next day, and burst in the same way. This occurred two or three times, and the boy then died about the third or fourth day.

Post-mortem examination.—A large clot was found lying in the cavity, caused by the bursting of the swelling, and all the parts under the jaw and at the upper part of anterior triangle of the neck, were found laid bare, as if for anatomical examination. A large portion of parotid gland was found lying almost loose in this cavity. A small aperture, about the size of a pea, with irregular edges, was found in the internal jugular vein, just above the lower border of the parotid gland and about half-an-inch higher up and behind the gland; another opening in the vein was found in the form of a slit about half-an-inch in length. Several lymphatic glands in a state of suppuration were found along the course of the vein. Dr. Murchison for Dr. Scurrah, 1*st of February*, 1859.

---

14. *Aneurysm of the Aorta with a peculiar Condition of the Liver.*

W. B., æt. 37, a carpenter, and formerly a hard-drinker, was admitted into King's College Hospital on the 31st of December, 1858—he had had no previous illness, except an abscess in the groin, which was opened in the Middlesex Hospital—and had

never had syphilis. About a year before his admission, he began to suffer from severe pain in the back and abdomen, which pain has continued to the present time, and unfitted him for work.

About seven weeks ago he first detected a swelling in the epigastrium, which has increased considerably. He has been troubled with flatulence, has had occasional vomiting, and has lost flesh.

On admission, he had a thin, sallow, unhealthy appearance, which was decidedly suggestive of malignant disease. There was a pulsating tumour in the epigastrium, rather more prominent to the left of the median line; above, it seemed to pass beneath the ribs, but below, it had a well-defined margin, about an inch above the umbilicus. Its anterior surface was rounded and convex, and it distinctly descended during a deep inspiration. There was some degree of résonance on percussion of the tumour, as if from the contact of the stomach, or intestine containing air. No murmur was heard either over the tumour, or over the lower dorsal and upper lumbar spinous processes.

Early on the morning of the 3rd of January, he was seized with sudden severe pain in the tumour, and faintness, and he became pale as if suffering from internal hæmorrhage. After a few hours he vomited coffee-ground liquid, and continued to do so occasionally for two days.

On the 13th of January, it was first noted that a soft bellows-sound was audible, not over the most prominent part of the tumour, but at its upper margin just below the ensiform appendice. This sound continued to be heard from that date; the exact spot in which it was best heard varied somewhat from day to day, but at no time was it audible over the most prominent part of the pulsating tumour.

The tumour appeared to increase in size, until it could be just covered by the half-closed hand.

On the 27th of January the spleen could be distinctly felt, enlarged, and extending nearly as low as the crest of the ileum.

On the 6th of February, while he was sitting up in bed taking his tea, he suddenly vomited a large quantity of florid blood. His face became blanched, and he quickly died. After death the tumour in the abdomen could not be felt.

Post-mortem examination, forty-six hours after death.

The thoracic viscera were healthy.

On opening the abdomen, it was found that the tumour which had been felt during life, was formed by the lower margin of the right lobe of the liver. This portion of the liver was indurated by a deposit in its substance of a material having the character of strumous matter, and it was separated from the mass of the right lobe by a deep fissure, evidently the result of atrophy of a portion of the hepatic tissue. The liver was large, its weight being three pounds fourteen ounces. The semi-detached portion of liver before-mentioned lay in front of an aneurysm which originated about the middle of the abdominal aorta. The aneurysm was about the size of the double fist, and contained laminated coagula; its pressure had caused erosion of the bodies of the second and third lumbar vertebræ, and its cavity communicated by a round opening, about two or three lines in diameter, with the lower portion of the duodenum. The stomach and the small intestines contained much clotted blood. Some blood had become infiltrated into the sub-peritoneal tissue on the left side, and had thus passed as low as the brim of the pelvis.

The spleen was large and soft, its weight eleven ounces and three-quarters.

Several of the mesenteric glands were enlarged, and contained a cheesy material. Dr. G. Johnson, 15*th of February*, 1859.

---

15. *Arterial Obstruction, producing Fatal Phagedæna of the Face.*

E. P., æt. 36, had been under observation for twenty months before his death, which took place on the 9th of February, in St. Thomas's Hospital. During this time he had been subject to a peculiar phagedænic process, under which he had lost most of the left side of his face. The disease began in the lower eyelid, and soon involved the globe of the eye; it then extended downwards, exposing the malar, maxillary, and nasal bones, which crumbled away in successive small sequestra; eventually, having opened largely into the nasal and buccal cavities, it attacked the base of the skull, and thus (after many months of extreme suffering), produced death by intra-cranial inflammation.

The destruction did not advance uniformly; it was effected by successive little acts of sloughing, which alternated with feeble

efforts of repair, and at every access left the patient with a larger and deeper excavation. There was no infiltration of surrounding textures; nor did the granulations, when they formed, ever tend in the smallest degree to exuberance.

The meaning of the disease was not arrived at during life. Before the case came under Mr. Simon's care, an opinion had been expressed that it was cancerous; but the character of the sore was, Mr. Simon thought, conclusive against this view. The man having undoubtedly suffered primary syphilis, suspicions were entertained that the constitutional taint of the disease might be the cause of his local suffering; and various anti-syphilitic drugs were therefore carefully, but unsuccessfully tried.

On *post-mortem examination*, it appeared certain that this intractable local disease had been a starvation-phenomenon resulting from obstruction of arteries.

Of the three vessels arising from the arch of the aorta, the left subclavian was completely obliterated by a firmly adherent plug nearly an inch in length; the left carotid communicated with the aorta by an aperture only just capable of admitting an ordinary probe; and the origin of the innominata was reduced by encroaching deposit to one-third of its normal calibre. Beyond their points of origin, these arteries were of proper size and contained but little atheroma. The heart was healthy; but the coats of the thoracic aorta, along its whole length, were so much loaded with earthy deposit as to crackle under pressure.

The brain was everywhere perhaps somewhat softer than natural, but with no difference in this respect between its two hemispheres. The lateral ventricles were distended with a turbid purulent fluid; their lining membrane was opaque, and their septum softened almost to diffluence. The base of the brain was coated with a layer of soft yellowish lymph, especially abundant in the middle line (about the circle of Willis and pons Varolii) and on the under surface of the middle lobe. The dura mater, corresponding to the latter portion of brain, was, for about two square inches, much discoloured, and had its arachnoïd surface covered with lymph. The bone beneath it was necrosed to about the extent of a shilling.

In the Medico-Chirurgical Transactions, Vol. XXXIX., Mr.

DESCRIPTION OF PLATE V.

The Figures illustrate Dr. John W. Ogle's case of unusually large Sub-clavian Aneurysm, p. 103.

Fig. 1. Posterior view of the Aneurysmal Tumour during Life, showing the Aperture at its summit through which the fatal Hæmorrhage occurred; as also the distortion of the Scapula.

Fig. 2. View of the lobulated sub-clavian Aneurysm, and the surrounding structures dissected after death. The Scapula and Clavicle are seen tilted up somewhat more than was the case during life, owing to the restraint of the Muscles and Integuments having been removed.

Fig 1

Fig 2

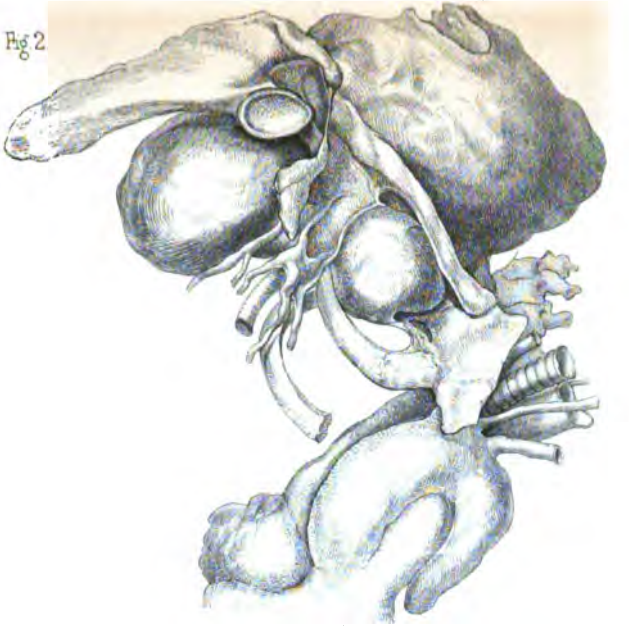

Tuffen West sculp.

W West imp

Savory has reported a case in many respects comparable to the preceding. Mr. JOHN SIMON, 15*th of February*, 1859.

---

16. *Enormous Aneurysm of the Right Subclavian Artery—Peculiar Cyanosis and Club-shaped condition of the Fingers, with remarkable Hypertrophy of their Nails—Death after two attacks of outward Hæmorrhage from Rupture of the Aneurysmal Sac.*

The specimen was removed from the body of a labouring man, æt. 50, who died in St. George's Hospital.

Previous History.—The patient had three years previously been attacked with hæmoptysis, and spat up about three pints of frothy blood. Ever since, he was the subject of dyspnœa, but went on at his work until a year before his entrance into the Hospital. At that period he caught cold, and his dyspnœa became more urgent, and he had great pain in the elbow of the right arm. He also became subject to giddiness, and swelling and numbness of the right arm and hand.

Symptoms on Admission.—At this time the pulse was remarkably jerking, and he had much pain of a shooting character in the upper part of the chest. He was also unable without very great distress to lie down in bed on the right side. There was a distinctly pulsating tumour above and below the right clavicle, and also at the same parts great tenderness on pressure and dulness on percussion. On auscultation of the tumour, a loud and distinct single murmur was heard above the clavicle over the swelling, and below the clavicle a distinctly double murmur was audible coincident with the sounds of the heart. At the cardiac region a double bruit was heard, most loudly at the apex of the heart, and a single bruit was heard posteriorly, between the spine and the edges of the right scapula. Moreover, at each impulse of the heart, the right shoulder and upper part of the chest at the affected part received a manifest shock, and synchronously the right arm was elevated and jerked outwards from the side of the body.

The tumour increased in size, (*see* Plate V., Fig. 1), and the arm became very œdematous. By degrees, nearly all sensibility of the skin of the arm and all voluntary movement became lost, and the arm presented a painful and grotesque appearance, losing its natural

character, and assuming that of a stuffed cylindrical cushion, the more remarkable as it became abducted from the side of the chest, and more and more elevated at each impulse of the heart. The pulse at the right wrist eventually entirely failed, and the nails of the fingers became exceedingly hypertrophied, becoming much broader and thicker, as well as longer; and the ends of the fingers clubbed in shape, and quite darkly *cyanotic* in colour. The tumour above the clavicle became exceedingly large, extending considerably upwards and *backwards*, and its apex gradually very deep red in colour; it eventually burst, allowing of the escape of about a pint and a-half of blood. For many months the patient could not lie down, and he was greatly exhausted by a second attack of hæmorrhage, which occurred before death. He obtained most relief from aconite as a lotion.

Post-mortem examination.—Showed that the right subclavian artery generally was very dilated, and along with the arch of the aorta was the seat of several patches of atheromatous deposit. The aneurysm which affected the aorta at a part immediately behind the right sterno-clavicular articulation (*see* Plate V., Fig. 2), had produced great displacement of the right scapula and clavicle, and also caries of the posterior surface of the latter bone, and of the right sides of one or two lower cervical vertebræ. The first rib was very greatly carious and was partly, as it were, lying surrounded by blood clot, within the aneurysmal sac. The sac extended also so much downwards into the axilla and beneath the clavicle, as completely to push forwards and compress the axillary artery and vein, and the various nerves concerned in the brachial plexus, &c. The summit of the aneurysmal sac was exceedingly thinned and softened, and of a dark gangrenous look, especially in the region where hæmorrhage had occurred during life.

The sac was capable of holding several pints of blood; about half of its contents was coagulum, but none was very discoloured. There was also extensive calcareous disease of the flaps of the mitral valve.

Commentary.—The most remarkable features of this case are:—

1. The very unusual size attained by the aneurysm before bursting, as the drawing shows; and

2. The peculiar cyanotic character of the fingers of the affected hand along with the increased growth of the nails. The increase in the size of the fingers and in the dimensions of the nails I attribute to exalted nutrition induced by the presence of an increased amount of blood in the veins of the part, detained there by the pressure upon and interference with the circulation in the neighbourhood of the axilla. The œdema and want of pulse at the radial artery, in addition to other symptoms, palpably indicate this obstruction.

The case in this respect illustrates in an interesting way the subject of cyanosis in general.

Dr. JOHN W. OGLE, *2nd of March*, 1859.

---

17. *Rupture of an Aneurysm of the Intra-Pericardial portion of the Aorta.*

History.—On the morning of Sunday, Febuary 27th, 1859, the deceased, æt. 46, appeared as well as usual, but during the same day he was found lying on the floor insensible; he was seen by a medical man a few minutes afterwards, when he was black in the face, unconscious and quite pulseless; he was placed on his bed, and recovered sufficiently to open his eyes and say "all right." He then swallowed a wine glass full of brandy-and-water, made an ineffectual attempt to rise, and almost immediately afterwards expired. From the time of the attack to his death, quite half-an-hour had elapsed.

Post-mortem examination.—Body very stout and middle sized. On removing the sternum and opening the pericardium there was a clot of black blood, weighing eight ounces, completely covering the heart; and in addition, from six to eight ounces of dark fluid blood. On uncovering the heart, I discovered an aneurysmal pouch, the size of a small walnut projecting from the posterior part of the ascending aorta, and situated immediately above the sinus of Valsalva, and at the upper part of the sac was an opening the size of a pin's head through which the blood had escaped. The walls of the aneurysm were very thin, with the exception of that portion in contact with the right auricle. The heart was loaded with fat, and striæ of fat were found mixed with

muscular fibre. On examining a portion taken from the left ventricle, under the microscope, fatty deposit was seen, upon and in the muscular fibre. The aorta throughout was thickly patched with atheromatous deposits. The lungs and viscera were generally healthy.

Mr. T. W. Coulson, 15*th of March*, 1859.

---

18. *Aneurysm of the Innominate Artery.*

The patient from whom this specimen was removed was a woman æt. 50, who was admitted into the Workhouse, where she died, two months before her death, suffering from slight cough, with stringy, mucous expectoration and hoarseness accompanied by distressed respiration and inability to remain for long together in the recumbent position. A month before her death a tumour began to form on the right side of the lower part of the neck, which rapidly increased in size and presented pulsation throughout, and a loud aneurysmal bruit. As the tumor increased the dyspnœa increased also, and difficulty of swallowing came on during the last days of life, amounting at the last to an absolute inability to swallow even the smallest quantity of food or drink. The pulse in the right arm was feeble, and all the veins of the right side of the neck very much congested. The tumour, the day before her death, occupied nearly the whole of the right side of the neck, as high as the thyroïd cartilage, and extended far into the posterior triangle. She died quietly on the 23rd of March, 1859, without any external hæmorrhage.

Post-mortem examination.—The aneurysm was found to have burst in the posterior triangle, all the muscles in the neighbourhood being infiltrated with blood. The aneurysm (of very large size) was found to be connected with the innominate artery, and to have passed underneath the sterno-mastoïd muscle, and in front of the scalenus anticus muscle, and the subclavian and carotid arteries. The aneurysm must have exerted considerable pressure upon the trachea and œsophagus as it lay close upon, but without implicating them. One portion of the aneurysm had pushed between the carotid artery (with the pneumogastric nerve) and the jugular vein, and had produced closure of the vein. The carotid and

subclavian arteries were normal, as were those of the opposite side. The arch of the aorta was a good deal diseased, and there was a distinct aneurysmal pouch at the point where the innominate artery came off.

Mr. CHRISTOPHER HEATH, *5th of April*, 1859.

---

19. *Contraction of the Orifice of the Pulmonary Artery from Fusion of the Valves.*

The subject of this defect was a man, æt 23, who first came under Dr. Peacock's care in November, 1855. He stated that he had then been ill eighteen months, and that his indisposition commenced with profuse spitting of blood. He had subsequently had two other attacks of hæmoptysis, and suffered from cough and expectoration; his voice was very husky; the percussion sound under the left clavicle was defective, and the respiratory sounds were feeble in that situation, the cough and vocal resonance being increased; a loud systolic murmur was audible along the upper part of the sternum, and especially in its left side.

In the spring of 1856, he was admitted into the Victoria Park Hospital, and again became a patient at that institution in January of the present year. During the interval his phthisical symptoms gradually advanced, and when last admitted, he was incapable of speaking except in a whisper; he had an abortive but frequent cough and profuse expectoration, and the usual symptoms and signs of advanced consumption. The cardiac murmur continued as before. He was suddenly seized with cerebral symptoms, and died comatose in February.

Throughout his illness, he never presented any appearance of cyanosis, and he had a peculiarly clear and pallid complexion.

On *post-mortem* examination, the brain was found much congested. The larynx was extensively ulcerated, and the cordæ vocales entirely destroyed. The lungs contained interspersed tubercles and cavities, especially in the left side. The heart was of natural size, and weighed nine ounces and three-quarters, avoirdupois. There was great hypertrophy of the walls of the right ventricle, which in front measured four lines in thickness. The pulmonic orifice was reduced to about half its normal capacity, the contrac-

tion being due to the adhesion of the valves. These had originally been three in number, but they were united and protruded forwards in the course of the pulmonary artery, and much thickened. The aperture only allowed of the passage of a ball measuring fifteen French lines in circumference, while the trunk of the artery itself admitted a ball measuring thirty-three lines, and the aortic orifice, one measuring thirty-nine lines. The other valves were healthy; the foramen ovale was entirely closed, and the heart otherwise well formed. In the absence of any other defect in the heart it may be doubted whether the fusion of the valves was in this case congenital or occurred after birth. The frequency of a similar condition of the pulmonic valvular apparatus in cases of undoubted congenital disease, renders it, however, most probable that the change occurred before birth. The reduction in the capacity of the orifice was also not so great as if existing at the period of birth, to have necessitated the non-closure of one or other of the fœtal passages

Remarks on this case with be found in connection with the following one, No. 20. Dr. Peacock, *5th of April*, 1859.

---

20. *Re-opening of the Foramen Ovale.*

This specimen was removed from a female, æt. 24, with curvature of the spine and deformed chest, who was attended by Mr. Brennan, assistant to Mr. Unwin, of Brixton; and to the latter gentleman Dr. Peacock was indebted for the opportunity of examining it. She was reported to have been in her usual health till a month before her death. When seen she laboured under dyspnœa, headache, and transient delirium, irregularity of the pulse, coldness, and very marked lividity of the surface, and she died comatose.

On *post-mortem* examination, the heart was found large, weighing twelve ounces and a half, avoirdupois. There was great dilatation of the right auricle, ventricle, and pulmonary artery, and the right ventricle was much hypertrophied, measuring four lines and a-half at the thickest part of the anterior wall. The pulmonary orifice allowed of the passage of a ball measuring forty-eight French lines in circumference, while the aortic orifice only ad-

mitted one measuring thirty-three lines. The fossa of the foramen ovale was very greatly expanded and the valve was defective at its anterior edge, leaving an aperture between it and the isthmus of about three lines in diameter.

Remarks.—This specimen and the one which has been described as No. 19, are examples of somewhat uncommon forms of cardiac defect, and they have special interest from their bearing upon the probable cause of cyanosis.

In the first case, in which no lividity was present during life, there was also no communication between the two sides of the heart; in the second case, in which marked lividity had existed during life, the partition of the auricles was defective, so that some intermixture of the venous with the arterial system may have occurred. The cases, therefore, would appear to support the theory which ascribes the production of cyanosis to the intermixture of the currents of blood; and to be opposed to that which regards the discoloration as due to general venous congestion. On closer observation, it will, however, be found that the facts do not warrant these inferences. For in other cases in which the pulmonary orifice has been found contracted, without any other defect existing in the heart, cyanosis has been observed during life. In his work on "Malformations," Dr. Peacock has referred to seven instances of defect, similar to that in the first case,* and he has since obtained references to two others.† Of the nine cases, however, in two‡ the history during life is not recorded, and in one § the account of the symptoms is very imperfect; deducting these, there remains only six cases, and in two‖ only out of the six was cyanosis absent, while in some it appears to have been very marked. It follows, therefore, that when lividity is not observed in such cases there are special reasons for its absence. Thus in the

* Page 87. The cases of Philouze, Burnet, Fallot, Crugie, and Graband, Tiedmann, and Fohman, Dr. Ogle, and Dr. H. Roe.

† Chelius, quoted in Tiedmann's Verengung und Schliessung der Pulsadern. Heidelberg und Leipzig, 1843, p. 20. Cruveilhier, Anat. Path., Liv. 28, Pl. IV., Fig. 2.

‡ Those of Philouze and Cruveilhier. § The case of Fallot.

‖ The cases of Dr. Ogle and Dr. Hamilton Roe; and in the former there appears to have been some lividity observed.

case described, the moderate amount of the pulmonic obstruction and the great hypertrophy of the right ventricle, render it very questionable whether there could be really any impediment to the circulation, for the obstruction at the orifice of the pulmonary artery was probably compensated by the increased power of the right ventricle.

In the second case there was very obvious impediment to the circulation through the lungs from the curvature of the spine and the deformity of the chest, and to this cause, not to the comparatively trivial intermixture of the currents of blood which can have occurred, is the lividity most probably to be ascribed. From the dilatation of the right auricle, ventricle, and pulmonary artery, and from the hypertrophy of the right ventricle, it is evident that the impediment to the circulation through the lungs had been great and of long duration, and possibly had the patient been under observation, cyanosis would have been previously noticed. The opening in the valve of the foramen ovale was most probably the result of the thinning from the expansion of the fold in the dilatation of the right auricle, and may only have occurred during the last periods of life, and long after the cyanosis first appeared.

Dr. Peacock, *5th of April*, 1859.

---

21. *Congenital Malformation of the Heart; Perforation of the Septum Ventriculorum, establishing a communication between the Left Ventricle and the Right Auricle.*

M. A., a girl, æt. 2 years and 4 months, was brought to me at the Hospital for Sick Children, Great Ormond Street, on the 15th of November, suffering from dyspnœa and pyrexia.

She was one of three children, of which one was healthy, and one in a weakly state, consequent on an attack of measles. The mother's family were phthisical. Up to the age of three months the mother considered her quite healthy. About this time, she took cold, and had a cough attended with a certain amount of dyspnœa, but there was no lividity observed at that time.

Last summer she had an attack of jaundice, and two or three months ago she had a cough, and the doctor said she had a "diseased heart," but with these exceptions, the child continued to thrive.

When I first saw her, there was slight lividity of the lips and surface of the body, and there was some heat of skin. On examination of the chest, slight dulness was found over the base of the right lung, with sub-crepitant rhonchus at this part; over the whole chest there were moist rhonchi audible. Over the præcordial region there was a loud systolic blowing murmur most clearly audible at the apex, but also very loud at the third left cartilage. Her pulse was 150 per minute, respirations 46.

Linseed meal poultices were applied to the chest, and a stimulant mixture given. She died next day.

On *post-mortem* examination, both lungs were found much congested. The left lung was hepatized in part of its upper lobe.

The heart weighed three ounces and a-half. The right auricle was capacious—containing a decolorized clot.

The tricuspid valve had not three very distinct flaps; two were almost merged into one, and bound down to the wall of the ventricle. At the upper part of septum, on the left side was seen a hole (large enough to admit a good sized pea) which lead from the upper part of the left ventricle to the junction of the right auricle with the right ventricle. The edges of the aperture were fibrous, and well bevilled off. The mitral orifice measured two inches and three-eighths in circumference. The aortic and pulmonary valves presented no unusual appearances, and the pulmonary artery did not appear contracted.

The foramen ovale and ductus arteriosus were both closed.

Dr. Hillier, 19*th of April*, 1859.

---

22. *Ruptured Aneurysm of the Heart.*

This specimen was sent to me by Mr. Cowley of Whitechapel, who was called upon by the Coroner to make a post-mortem examination of the case whence it came. The subject was a girl, æt. 12, who was said by her parents always to have enjoyed good health, when she suddenly, while playing, fell dead in the room. The *post-mortem* examination showed effusion of blood in the pericardium arising from a rent in the left ventricle; the heart was removed for subsequent examination. About the middle of the left ventricle on the outside, the muscle was replaced by a

thin membrane, which, however, did not bulge at all outwards; this was about the size of a shilling-piece, and running through its middle was a rent, half-an-inch long. On examining the interior of the ventricle, the mitral fleshy columns were pushed inwards, and on touching them, it was evident that a hollow space existed behind; on further looking for an opening into this, one was found, which would admit a small quill, situated on the right of the columnæ carneæ, and close to the septum on the front of the heart. An incision internally exposed a sac the size of a large walnut, formed within the walls of the left ventricle, having a simple membrane on its external surface, and covered internally or towards the inside of the heart, by a thin expansion of muscular fibre formed by the columnæ carneæ; when filled it must have bulged somewhat internally. It contained recent coagulum, and when this was removed, a perfectly smooth membrane was seen, continuous with the endocardium, and of the same structure communicating by the opening before mentioned. There was no appearance of any inflammatory process in any part of the interior of the heart, although probably such must once have been present, associated with a carditis and abscess in the muscle. Dr. Wilks, 19*th of April*, 1859.

---

23. *Disease of the Pulmonary Valves in an Infant. Sudden death.*

The infant from which this specimen was taken, was born in the British Lying-in-Hospital, the mother being under the care of Mr. Brookes. The child, a female, continued apparently well up to the eleventh day of its life (14th of April, 1859) and nothing peculiar was noticed. On the morning of that day the child suddenly expired. A nurse who had observed the infant asleep, and apparently in its usual health a quarter of an hour before, was called by the mother to the bed and found the child dead, quite black in the head and face.

Post-mortem examination.—It was found that the pulmonary valves were the seat of extensive disease. Two rounded red, smooth vegetations projected transversely across the orifice, the largest of which was one-fifth of an inch in diameter, the other rather less. The vegetations were attached on the pulmo-

nary aspect of the valves, which besides were greatly thickened and contracted. The calibre of the pulmonary orifice was very greatly diminished in size by the existence of the vegetations; the column of blood passing through it must, in fact, have been very small. At the base of the septum ventri-

WOODCUT 5.

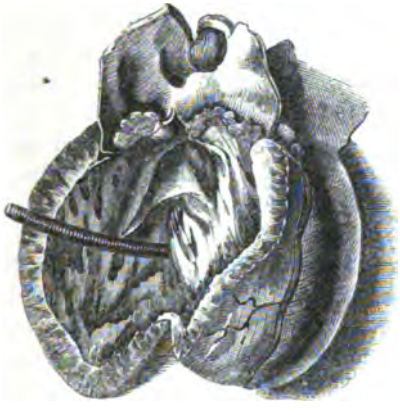

Right ventricle and pulmonary artery laid open, showing vegetations on the pulmonary valves; the probe seen inserted, is passed through the inter-ventricular opening.

culorum there was an abnormal communication between the ventricles, rounded, and one-eighth of an inch in diameter. The heart was otherwise normal. The brain and cranial sinuses were full of blood; the lungs, pleuræ, and pericardium much congested. There were no marks of violence to be discovered.

Prior to the post-mortem examination, it was by no means evident what was the cause of death. The result of the examination left no doubt, however, as to the nature of this case. It is somewhat remarkable that no symptoms of cardiac derangement had been noticed, as the disease of the pulmonary valves must have been present from birth.

DR. GRAILY HEWITT, *3rd of May* 1859.

---

24. *Disease of the Tricuspid Valve; detachment of Fibrinous Concretion, and impaction of the same in the Left division of the Pulmonary Artery.*

The sub-joined case is recorded as a pendant to the series of cases of obstructed cerebral arteries which I have furnished to the present volume. It affords an unquestionable example of the detachment of a fibrinous concretion from the tricuspid valve, and its subsequent impaction in the left branch of the pulmonary artery. The history of the case does not with any clearness indicate the date of the occurrence neither does the post-mortem prove to demonstration that any serious local results followed. It is, however, an interesting coincidence, that there was pleurisy upon the same side of the chest, and a coincidence of still greater interest and importance, if nothing more, that that portion of lung, to which the arteries chiefly interfered with by the impacted body were distributed, alone presented carnification and abscesses connected with the terminations of the tubes.

E. W., a married woman, æt. 28, was admitted the 20th of June, 1858. She had been ill since her last confinement, four months previously, at which time the labour had been severe and the hæmorrhage profuse.

It appeared she had had some cough for a considerable time, and that it had greatly increased since her confinement. She had never had hæmoptysis. There had been œdema of the lower extremities for the first week after parturition, but this had not occurred since. Emaciation had been rapid. The catamenia had not returned, although the milk had disappeared for some weeks.

On admission she was in a distinctly hectic condition, with daily rigors and profuse night-sweats. Pulse 112, feeble; skin moist; tongue clean; aspect anæmic; cough troublesome; breath short. There were supposed to be distinct evidences of tubercle on the left side; she complained of pain at the lower and back part of the same side, and was unable to lie on it. There was no palpitation; and the heart's sounds though feeble, appeared normal.

During the time of her stay in the Hospital there was no great change in the symptoms — the breath, however, became much

shorter, and the œdema returned in her legs and face. She continued sensible to the last, and died of exhaustion on the 2nd of July; the 13th day after admission.

She never manifested any lividity of face; and never, so far as could be ascertained, had any sudden paroxysm of any sort.

Post-mortem examination.—There was slight œdema of the lower extremities.

The pericardium was healthy, and contained a little serum. The heart looked large, and weighed eleven ounces. The left side presented nothing worthy of remark; but the right auricle and ventricle were disproportionately large, and the tricuspid valve was extensively diseased. It was studded chiefly along its free margin with lobulated rather than warty vegetations, which appeared thoroughly incorporated with the substance of the valve, varied in thickness from a quarter of an inch downwards, had a tough corrugated buff-coloured surface, and as shown on section, a nearly homogeneous, elastic, yet lacerable fibrinous interior. The valve presented two or three perforations, and was clearly altogether incompetent. Many similar but smaller vegetations studded the surface of the ventricle in the neighbourhood of the valve.

In the distal extremity of the left division of the pulmonary artery was a fibrinous mass about as large as a filbert, united to the parietes of the vessel by a partial capsule of rather tough transparent lymph. It admitted of easy separation from the capsule here alluded to, presented an opaque buff-colour, and a surface somewhat dry and coriaceous, much corrugated, and in places deeply fissured. On section it was found to consist of an indistinctly laminated peripheral layer rather more than half a line thick, and of a nucleus which was toughish and elastic, yet somewhat friable, of a dead-white hue and homogeneous texture. The nucleus was separated here and there from the peripheral portion by a little recently deposited partially-decolorized fibrinous clot which appeared to have insinuated itself through the bottom of the sulci formed by the irregular lobulation of the surface. The capsule of lymph binding this mass to the parietes of the vessel did not completely surround it, and varied in thickness. It was pretty firmly adherent to the mass on the one side and to the walls of the artery on the other—indeed, so firmly to the latter

as to be separated with considerable difficulty. The rest of the pulmonary artery and its branches were healthy, except that one of the latter passing from the occluded vessel into the lower lobe of the left lung contained an adherent plug of partially decolorized clot continuous with the capsule just described.

The ovoïd fibrinous mass above spoken of precisely resembled the concretions connected with the tricuspid valve; so closely that there can be no doubt that it had originated in the same situation; that it had become detached and carried with the stream of blood into the situation in which it was found, and that it had become fixed there by the subsequent coagulation of lymph around it. This view was confirmed by the microscopic examination, which demonstrated that they equally consisted of an amorphous matrix, thickly studded with granular matter, of which much was removed by the operation of acetic acid.

The right pleura presented numerous adhesions and a little serum. The corresponding lung was large, crepitant, congested, and œdematous; and the greater part of the middle lobe was carnified. The left pleura contained about two pints of turbid fluid; and its surface was covered by a reticulate layer of recently-effused lymph, which was most abundant over the lower lobe of the lung. The lung itself was much reduced in size and almost airless. It was healthy in structure in the greater part of its extent; but three or four cubic inches of the lower and anterior part of its lower lobe were distended, solid, and congested on the surface but studded with numerous yellow spots. On section of this solid portion it was found to consist of a deeply congested carnified matrix riddled with abscesses from the size of a pea downwards. These latter presented slightly flocculent straw-coloured parietes, and were surrounded by an intensely congested border. On further examination they were found to communicate freely with tubes, and indeed, appeared to have originated in ulceration of the terminal branches. The tubes connected with them were congested, and thickly studded with small adherent flakes of whitish false membrane.

The kidneys were large, but healthy in structure. The remaining organs were all healthy.

Dr. Bristowe, *17th of May*, 1859.

---

25. *Plugging of the Superior Longitudinal Sinus and Cerebral Veins, with Paralysis and Loss of Speech.*

The subject of this case, was a girl, æt. 16, who was under the care of Mr. C. S. Webber, of Connaught Square, with whom I attended the post-mortem examination, and who has supplied the following particulars. She had resided in London, and had generally enjoyed good health; she had menstruated regularly, and no cause could be assigned for her illness. A month before her death she went into the country, and as far as could be ascertained she had been ill from six to eight days with pain in the head, confusion of intellect, vomiting, and other symptoms indicating cerebral disturbance, her medical attendant in Hampshire having stated "that had she remained, it was his intention to have had the head shaved and leeches applied." When seen by Mr. Webber (after a journey of twenty miles), there was paralysis of the right side, the arm and leg being powerless, and the mouth was drawn to the left side; there was loss of speech and of power to protrude the tongue—also inability to pass water. There was pain in the head, especially of the left temporal occipital and post aural regions extending down the side of the neck and aggravated to extreme suffering on motion. There was frequent screaming and moaning, and the left hand was frequently applied to the left side of the head and neck. Perception of external objects existed, expressed by signs and frequent sobbings and indications of grief at being unable to communicate by speech. Pulse never above 80; heat of skin normal; tongue moist, slightly furred; pupils natural.

Power of motion of right limbs, of tongue, and in a less degree of articulation existed; the last was partially restored a few hours before death, which occurred somewhat suddenly after being turned from the semi-prone to the supine position for the purpose of catheterism, and was preceded by stertorous breathing for a few minutes. The duration of her illness in the country and in London was about fourteen days.

Post-mortem examination.—The body was well formed, and rather muscular. The thoracic and abdominal viscera all apparently in a normal condition. The heart contained about two tablespoonfuls of

fluid blood, and two clots, coated with fibrin, about the size of a walnut were in the right auricle; the superior longitudinal sinus was filled with coagulated blood, interspersed with portions of fibrin closely adherent to the walls of the sinus. On removing the dura mater the superior cerebral and cerebellar veins were seen to be much distended of a cord-like form, and of firm consistence; portions of straw-coloured fibrin interspersed with red coagulum could readily be seen through their thin walls, and on making a section of these blood cylinders, the fibrin was found generally placed on detached portions between the red particles. The superficial cerebellar veins were nearly all plugged with fibrinous coagula, and all the cerebral veins entering the longitudinal sinus were firm and cord-like from the same cause. The arachnoïd membrane was opaque over its upper and lateral portions on both sides. The pia mater rather vascular. The cerebrum apparently healthy, and without any preternatural vascularity of its substance. The lateral ventricles contained about two teaspoonfuls of reddish serum, and about the same quantity was present under the arachnoïd at the upper part of the spinal cord.

The left lobe of the cerebellum on manual examination appeared of less consistence than the right, but on cutting into it, no perceptible difference was observed; indeed the substance of the brain appeared to be altogether normal.

Remarks.—The case itself is of great interest, but when viewed in connection with another in the same family, is one, I think, of especial importance. I saw with Mr. Webber a sister of the deceased, at Reading, about eighteen months since, a girl, æt. 20, who generally enjoyed good health. When turning in her bed, she felt a sudden pain in the right arm, over the brachial artery; this was followed by acute pain and dry gangrene of the hand and fingers, necessitating amputation of the limb four or five weeks after the commencement of the attack. On her return to London cerebral disturbance occurred, with paralysis of the side, and at the present time she has partial paralysis of the upper extremity, arising probably from a state of vessels similar to that described in her sister's case. I believe, as I have expressed elsewhere,

that many important lesions and functional disturbances have their origin in plugging of the arteries and veins.*

Dr. CRISP, 17*th of May*, 1859.

---

13. *Two specimens of Abnormal Origin of the Right Subclavian Artery.*

In both cases the right subclavian sprung from the commencement of the descending aorta at the posterior part of the trunk, just below the attachment of the remains of the ductus arteriosus, and about an inch below the origin of the left subclavian. In both cases the abnormal artery passed across the vertebral column behind the œsophagus, reaching in nearly a straight line upwards, and to the right, the usual position of the vessel, on the neck of the first rib. In both, the right carotid was connected with the aortic arch in the usual place of the innominate. In one case, the abnormal vessel gave off its usual branches in their usual places. In the other, the right vertebral was given off, not from the subclavian, but from the carotid, about an inch and a-half above its origin from the arch, and entered its bony canal at the fourth cervical transverse process. (Fig. 8.)

These specimens were shown, not because of their rarity, for most anatomical museums exhibit the like,—and figures of them are given both in Quain's and Tiedemann's anatomical plates; but with a view of laying before the Society an explanation of the way in which this frequent irregularity is brought about. The singular constancy of the abnormal point of origin of the right subclavian from the descending aorta is noticed by Quain. Often it coincides with the very point of attachment of the ductus arteriosus. It is very seldom from the aortic arch near the usual origin of the innominate.

By referring to the development of the great vessels of the neck in the vertebrate animals—the reason of this uniformity of irregularity can best be understood.

* This case would have been inserted in the part of the volume dedicated to injuries and diseases of the nervous system, had it not come to the editor's hand too late. It was, however, in time to be added in the division of the volume allotted to the organs of circulation.

In his monograph *De Ovi Mammalium et hominis genesi*—Von Baer gives a figure of the vascular arches of the neck as seen in the ovum of the dog, of which Fig. 6 is a modified diagram. From the base of the heart springs the primitive ascending trunk (*b*), which afterwards becomes separated by a partition into the ascending aorta and pulmonary artery. This terminates superiorly in a bulbous extremity, *bulbus aortæ.*

From each side spring four arches, uniting externally in a common trunk (*c*), and lying upon the side of the pharynx. The resulting lateral trunks pass down towards the median line behind the heart and œsophagus, and unite at an acute angle to form the descending aorta, (*d*). A fifth pair of arches afterwards appear posterior to the former, and become connected with that part of the primitive trunk which afterwards forms the stem of the pulmonary arteries. These five pairs of vascular loops lie in the arches of developing tissue which intervene between the cleft for the mouth and the four branchial clefts, and in which are afterwards formed the lower jaw, the styloïd process and the horns and body of the hyoïd bone.

According to the above-named observer,* the two anterior pairs of vascular arches speedily become obscured by progressive development of the lower jaw and structures of the neck, and are lost to the observer in the enclosing tissues. In the embryo of the rabbit, however, by separating the pharyngeal structures from the spinal, he observed these arches very distinctly placed deeply near the spinal canal. The three other pairs were present at the same time, the fifth pair being very small. From the tardy appearance of the latter and the disappearance, almost simultaneous, of the first pair, four pairs of arches only have been seen at the same time, in the Mammalia, by most other observers.

In the embryo of the fish, Von Baer has figured six pairs;† in the bird and rabbit, five pairs. Rathke has seen in the viper, four pairs.‡ Bischoff in the dog and rabbit, four pairs.§

* Meckel's Archives, 1828, p. 143.

† Entwickelungs-geschichte der Fische.

‡ Entwickelungs-geschichte der Natter.

§ Entwickelungs-geschichte des Saugethiere und des Menschen.

Husckke, in the bird—and Rusconi in the salamander—the same number.*

The three posterior arches are more persistent, and their developmental changes can be better studied. They are very evident in the embryo of the pig and sheep. In the human fœtus about the fifth week, two arches, right and left, springing from the bulbus aortæ, are figured by Von Baer. These, after passing behind the heart and lungs—unite to form the descending aorta. Below these arches are given the inferior laryngeal branches from the vagi nerves. From the top of the bulbus are given off the carotids, and at the outer ends of the arches are two branches which, from their direction and position, can be no other than the united vertebral and subclavian.

About the exact nature of the transformation of these three posterior vascular arches the above-named observers are disagreed. Von Baer considers that the third pair become, by a process of partition, the innominate, carotid and subclavian arteries on their respective sides. The fourth arch on the left side becomes, in mammals, the aortic arch, while in birds, the same arch on the right side is persistent to that end.† The fifth pair become the right and left pulmonary branches,—the trunk being formed by a septum from the primitive ascending trunk. The two first arches on both sides, the right fourth arch, and the connections between the third, fourth, and fifth on the right, and the third on the left, with the descending aorta are obliterated. The connection of the left fifth with the descending aorta is persistent in the ductus arteriosus.‡

According to Rathkè, however, the third pair of arches become developed into the internal carotids only. The fourth, on the left, remains as the aortic arch, and the same on the right, as the innominate and first part of subclavian. The fifth form the pulmonary branches and ductus arteriosus. The right aorta root and its union with the fifth arch are afterwards obliterated, together with the external union between the third and fourth. According to the figures given by this author in Muller's Archives

* Muller's Physiology, by Baly, Vol. I., p. 174.
† Burdach, Traite de Physiologie, III., 519, Plate IV.
‡ Entwickelungs-geschichte der Thiere. Von Baer.

for 1843—of the vascular arches in the embryo of the pig and cow, the subclavian arteries, clearly, are derived from the outer extremity of the *fourth* vascular arches on each side, of which the left is already assuming its permanent form of the aortic arch. The left subclavian is given off just above the junction of the fifth arch with the fourth. It is in union with the vertebral, the latter being recognized by its entering the cervical transverse processes. The right vertebral is given off from the arch, while the right subclavian is formed a considerable distance afterwards, by the division of the fourth arch vessel into two branches, one (the subclavian) going to the anterior limb, while the other continues its downward course to join with the aortic arch from the left side, forming the right root of the descending aorta, as yet persistent.

This observer supposes Von Baer to have mistaken the internal carotid for the subclavian, on account of the arch the vessel makes between the third and fourth branchial clefts, before it passes upwards posteriorly, to supply the inner parts of the head and the rudimentary eyeball. He further supposes the external carotid, (*carotis facialis*), to have been described by Von Baer as the common carotid, and the true subclavian, as a twig from the aorta root to the side of the body, and he considers that the third arch has not been seen to give off any branch to the upper exremity.

By comparing the accompanying diagrams, it will be seen that the abnormal right subclavian (c^3 Fig. 8), under consideration follows exactly the course, and is united to the descending aorta at the same point as the right aorta root above described, as formed by the continuation of the fourth vascular arch and its union with the fifth (Fig 8, c^3). An obstruction arising at an early period in the right fourth arch internal to the origin of the vertebral artery from it would necessitate the persistence of the connection of the outer end of the arch with the aorta to carry blood to the right arm and right vertebral artery. This would give rise to the first form of abnormal right subclavian exhibited. But if the obstruction occurred immediately beyond the origin of the vertebral, the internal half of the fourth arch would remain in continuity with the vertebral, supplying blood to it, and thus would arise the second form, with the origin of the vertebral from

the carotid (Fig. 8 *o*). The common trunk of the carotid and vertebral would, in fact, be the representative of the innominate artery.

An obstruction in a similar position in the fourth arch of the left side, *viz.* :—at the arch of the aorta just before the junction of the ductus arteriosus, has been several times recorded. In the present volume of Transactions will be found a description of a preparation of this malformation shown by me to the Society during the current session.

In confirmation of this view, it is seen in these cases, that the recurrent branch of the right vagus passes directly from its parent trunk to the lower part of the larynx, lying internal to, and above the abnormal subclavian, and never passing round it as where the development is normal. On both sides the recurrent laryngeal nerves are given off from the vagi below the fifth vascular arches in early fœtal life. In the adult, the left recurrent will invariably be found to pass round the aorta below the junction of the ductus arteriosus. On the right side, where the fifth arch is entirely obliterated, it passes round the fourth arch,—*i.e.*, the cardiac half of the right subclavian. In well injected subjects, I have traced a small twig from the right subclavian, near the origin of the vertebral, behind the œsophagus to join the aorta about the attachment of the remains of the ductus arteriosus, which is, doubtless, the vestige of the fœtal right aorta root. (Fig. 7, e^3.) It will be seen, that in the foregoing explanation, I have followed the scheme of changes in the three lower arches given by Rathke, as I think he has clearly shown, that the normal origin of the subclavian in the Mammalia, is not from the primitive bulbus through the *third* arch, but from the *fourth* arch, external to its connection with the vertebral artery. In Fig. 6, it will be seen that the vertebral, the thyroïd axis, and the deep cervical, represent respectively the outer extremities of the third, second, and first vascular arches of early fœtal life, and that part of the subclavian which gives origin to these branches, represents a portion of the external trunks resulting from the union of these vascular arches. Thus it is only the axillary portion of the subclavian which is devoted to the upper extremity.

In the Batrachians (*proteus anguineus*) the arteries to the anterior

WOODCUT 6.

WOODCUT 7.

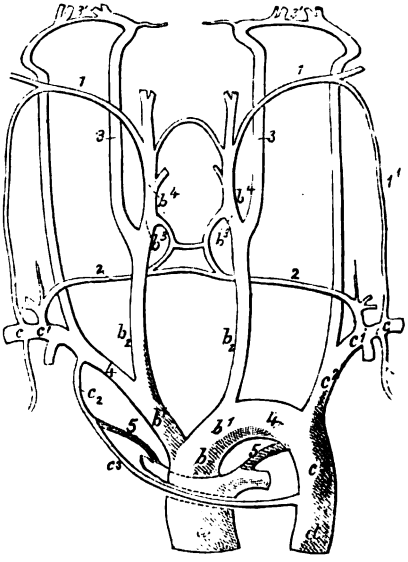

Fig. 6. Diagram of the five vascular neck arches in the ovum of the dog, as described by Von Baer. *a*. Heart. *b*. Primitive ascending trunk ending in the bulbus aortæ. *c*. External union of the five arches forming right and left aorta roots. *d*. Descending aorta.

Fig. 7. Diagram of the developmental changes of the vascular neck arches in the human subject. 1, 2, 3, 4, 5. Permanent results of development of the five arches. 1. Occipito-cervical. 2. Thyroid. 3. Carotido-vertebral. 4. Homological portions of the aortic arch and right subclavian artery. 5. On the left side —Ductus arteriosus, on right side the same obliterated. *a*. Pulmonary trunk. *b*. Ascending aorta. *b* 1 *b* 1. Corresponding homologues of aortic arch and innominate artery. *b* 2 *b* 2. Common carotids. *b* 3 *b* 3. External carotids. *c*, *c* 1, *c* 2. Portions of subclavian artery, the permanent condition of the external trunk of union of the three first arches. *c* 3. Lower portion of the aorta roots forming on the left side the vertical part of the subclavian artery and the beginning of the descending aorta, obliterated on the right side in normal development.

In the Fig. the primitive trunk is represented cut to show the right aorta root passing behind it. The shaded portions at *5* and usually at *c* 2 are obliterated in adult life.

limbs arise from the aorta after the union of its branchial roots, showing clearly their homology with the intercostals.

On account of the extreme difficulty of following out the changes of development occurring in the two first pairs of vascular arches at so early a date, I can, as to them, support the scheme of development offered in Fig. 7, by probabilities only,—derived from the peculiar arrangement of the vessels of the head and neck in adult life.

In Fig. 7 the corresponding divisions of vessels on each

WOODCUT 8.

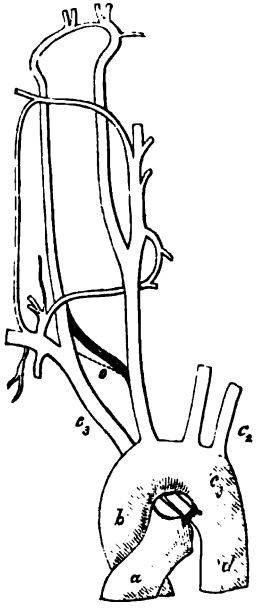

Fig. 8. Diagram of the two forms of abnormal right subclavian artery. *c3*. Persistent right aorta roots. *o*. Point of early obliteration, causing the abnormality. The shaded portion shows the variation in the origin of the vertebral artery.

side are marked by similar letters and figures. By the internal partition of the bulbus aortæ, we have the formation of the

ascending aorta (*b*) and trunk of the pulmonary arteries (*a*). From the lower part of the bulbus,—and becoming afterwards connected with its pulmonary compartment,—spring the fifth pair of arches (5), joining respectively the right and left aorta roots. The right one becomes obliterated at the outer end, and the left forms the ductus arteriosus—after giving off the pulmonary branch. The four upper arches, originally springing from the bulb separately, yet close to one another, become, by outgrowth from the bulb, associated on their respective sides, forming the first part of the aortic arch on the left—and the innominate on the right side (b^1 b^1). The fourth arch on the left, forms the central portion of the aortic arch, and on the right, the cardiac half of the subclavian (4). The three upper arches (still continuing coalesced) become elongated, and form the common carotid (b^2). The third arch, lying in the third interval between the branchial clefts, becomes the internal carotid (3). At its outer extremity it is involved in the development of the bones of the head, and becomes prolonged upward with the cranium. In the cranial cavity, we find it continuous with the vertebral (united in the basilar) through the posterior communicating arteries (3^1). The latter arteries thus represent the centre of the loop,—and the basilar and vertebral its posterior half (3^1), as far as to its connection with the aorta root (a^2). A very early union between the intracranial carotid and vertebral has been seen by Rathkè. Thus we account for the peculiar relative position and connection of the two main arteries of the brain.

The first two pairs of arches, continuing coalesced, pass upwards for a short distance as the external carotid artery (b^3). The second pair we find in the anastomosing loop of the superior and inferior thyroïd arteries (2). The peculiar and significant course of the inferior thyroïd, crossing in front of the vertebral and behind the carotid artery,—and closely applied to the pharynx and larynx, and directly uniting with the superior thyroïd anteriorly,—can be easily explained on no other supposition than that of its being the permanent form of the second vascular arch. Its apparent disappearance at an early period can be readily accounted for by its deep position, its comparatively small size, and the overlapping of the carotid trunk prolonged more rapidly and

extensively upward by the development of the head. The thyroïd axis thus is formed by branches given off to the neck and shoulder at the outer end of this arch.

In accounting for the first pair of arches, we meet also with an explanation of the apparently eccentric course of another and higher branch of the external carotid — also small and deep-seated,—*viz.*, the occipital. This artery forms an arch from the anterior to the posterior part of the neck, crossing the carotido-vertebral or third arch, in its course to the head,—just as the second arch does (1). Under the complexus and other muscles of the back and side of the neck, it forms by its *princeps cervicis* branch a free communication with the cervicalis profunda branch of the subclavian, which makes up the outer half of the loop (1^1)

Thus, the outer ends of the three first arches are united by the subclavian to the aorta root in the order of their number from without inwards (c, c^1, c^2). Occasionally they are so coalesced, that the vertebral or cervicalis profunda may arise from the thyroïd axis,—or the inferior thyroïd from the vertebral. Always, the two posterior arteries communicate very freely between the transverse processes with the cervicalis ascendens branch of the thyroïd axis. The superior intercostal branch must be looked upon as homologous with the transverse and ascending branches of the thyroïd axis.

In this plan, that part only of the subclavian which is external to the scalenus anticus muscle is the real artery of the limb. The middle part of the artery, where its branches are given off close together, will be seen to represent, on both sides, the upper part of the lateral aorta roots of early fœtal life. The lower part of the aorta root on the left side is persistent in the vertical portion of the subclavian (c^2), taken with the latter third of the aortic arch (c^3). They thus appear as the homologues of the abnormal right subclavian. On the right side, the lower and greater portion of the aorta root is obliterated, or represented by a small twig only. The first part of the right subclavian between the vertebral and the innominate is seen to be formed together with the latter named artery, by the transformation of the right fourth vascular arch.

A few practical hints may be derived from this arrangement concerning the collateral circulation after deligation of the common carotid. Mr. JOHN WOOD, *17th of May*, 1859.

IV. DISEASES, ETC., OF THE DIGESTIVE ORGANS.

1. PHARYNX, ŒSOPHAGUS, STOMACH, AND INTESTINES.

1. *Right Inguinal Hernia developed in Childhood; Testis over the External Abdominal Ring; Reduction of the Hernia, Adhesion and Perforation by Ulceration of the Walls of the Intestine at the seat of Stricture. Death six months after from acute Peritonitis.*

A man, æt. 58, was admitted into Guy's Hospital, on the 25th of May, 1858, suffering from acute peritonitis. He stated that he was the subject of right inguinal hernia which, some months before, had nearly caused his death. Mr. Birkett made an exploration of the right inguinal canal, but there was no hernia. The attack commenced twenty-one hours before admission with sudden violent pain, from which moment he gradually became worse, and he died thirty-hours afterwards.

Post-mortem examination.—A dissection of the abdominal walls was made from without, but there was no hernia of any viscus at the internal rings. Close to the abdominal margin of the right internal ring a coil of small intestine was adherent which was lying parallel with Poupart's ligament, and obscured the view of the viscera beneath it. This was attached to the abdominal walls by recent adhesions. When this was carefully removed, another coil of intestine was seen attached by old adhesions just inside the posterior margins of the internal abdominal ring. Between this and another coil there was a communication which led directly from the one into the other. Near to this the small intestine was narrowly constricted. The portion of the intestinal canal thus conjoined and perforated was jejunum, about eighteen inches from the duodenum.

Effusion of the contents of the alimentary canal had taken

place by the breaking down of a part of the old adhesion, or perhaps by recent inflammation and ulceration. General peritonitis and effusion of plastic lymph existed throughout the abdominal cavity.

After inquiry of Mr. Smith, of Blackheath, whose patient this man had been, I learned that about six months before this fatal

WOODCUT 9.

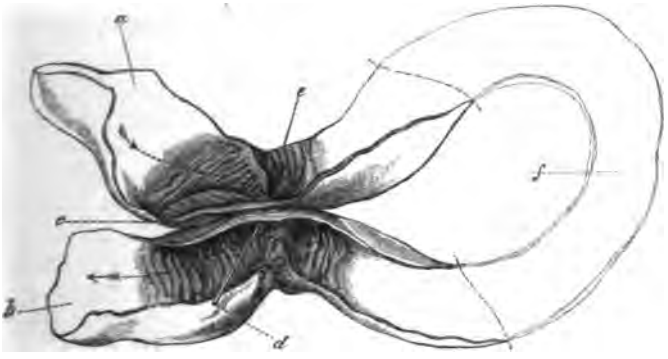

Represents the portion of small intestine, jejunum, which formed the hernia, cut open by a longitudinal incision.

a. The upper end of the coil.

b. The lower end.

c. The firm adhesions formed between the peritoneal surfaces of the bowel.

d. A piece of glass rod passed through the opening (*e*), which was formed in the coats of the two pieces of bowel lying side by side.

f. The portion of bowel to complete the coil which formed the hernia. In the preparation, the part of the coil between the dotted lines has been cut off.

The dotted line and the arrows indicate the course of the contents of the small intestine for six months previous to the death of the patient.

disease he was the subject of strangulated hernia for thirteen days, and his life was despaired of. Suddenly, however, the rupture went up, and he recovered.

The remarkable feature of this case, which was only revealed

after death, is the union and communication which was established between two coils of intestine, as the result of long continued strangulation of the bowel, and return of the hernia into the peritoneal cavity. This must be a rare example of a patient surviving such an accident for a period of six months. It is also a natural illustration of the method adopted by Dupuytren to cure an artificial anus by inducing adhesion between the two coils of intestine, and subsequent ulceration of their coats, in order to establish the continuity of the alimentary canal.

Mr. Birkett, 19*th of October*, 1858.

---

2. *Epithelial Cancer of the Œsophagus, opening into the Trachea.*

L. L., a cachectic looking woman, æt. 49, came under my care at the St. George's and St. James's Dispensary in July, 1858, having suffered for six months from difficulty and pain in swallowing. On passing a bougie, a stricture of the œsophagus was discovered just below the larynx, through which no instrument could be passed after several careful trials of the smallest size.

On the 2nd of August she applied (after an absence of some days), suffering from a cough which came on as soon as food was put in the mouth, and which almost precluded her from swallowing at all. She died two days after.

On *post-mortem examination*, an exceedingly tight stricture of the œsophagus at its upper part was discovered, and below this a large ulcerated surface, through the centre of which was an opening half-an-inch in length communicating with the trachea through its posterior surface. This opening was clearly produced by ulceration, and moreover, owing to the stricture above it was impossible that an instrument could have been forced through the parts.

The microscopic appearances corresponded very exactly to those of a specimen of epithelial cancer described and figured by Dr. Andrew Clark in Vol. IX. of Path. Soc. Trans.

Mr. Christopher Heath, 2*nd of November*, 1858.

---

3. *Sac of a Strangulated Umbilical Hernia with adherent Omentum, successfully removed.*

This was the sac of an umbilical hernia the size of the fist, in a woman, æt. 55, a patient of Mr. Christopher Heath's, at the St. Georges's and St. James's Dispensary. The hernia had existed for twenty years, but an extra protrusion had taken place and became strangulated two days before she was seen.

An operation having been found necessary, Mr. Heath opened the sac, and having relieved the stricture and returned a large knuckle of bowel, dissected the sac out from its attachments, and having passed a ligature through its base and the omentum, cut them off. The omentum was very much thickened and altered, and was adherent to a large portion of the sac. The patient made a good recovery, and was radically cured of the hernial protrusion.

Mr. Christopher Heath, *2nd of November*, 1858.

---

4. *Communication between the Sigmoïd Flexure and the Bladder, the result of Ulceration of a False Diverticulum.*

The specimen exhibited was taken from a gentleman, æt. 64. About the commencement of last January the patient first began to pass fæces in his urine, notice being directed to it by the passage through the urethra of straw-like bodies. These were examined microscopically, and a diagnosis come to that there was a communication between the bowel and bladder. The patient continued to pass fæces in his urine till his death, which occurred at the end of October, nearly ten months from the commencement of his symptoms. More fæces passed from his urethra, as might have been expected, when his bowels were relaxed than when they were costive. One of his most unpleasant symptoms was the passage of flatus along the urethra. He was frequently subject to attacks of difficulty of micturition in consequence of fæculent matter getting impacted in his urethra. Of late these attacks became more frequent, which can be explained by the presence of a small calculus in the bladder, as was found after death. About ten days before death he began to

complain of pain at the lower part of the belly, and had great constitutional irritation. Extravasation soon extended to the scrotum, penis, and lower part of the abdomen, from which the patient rapidly sank.

Post-mortem examination.—About three inches of the sigmoïd flexure were found somewhat contracted, and its mucous membrane thrown into a number of transverse folds. Among these folds were a large number of false diverticula of unequal length, the bottom of one of which had ulcerated and caused a communication between the bowel and bladder. In the bladder was a calculus about the size of a horse-bean, which consisted of fæcal matter, covered with lithate of ammonia, coated on the exterior by a layer of phosphates.

Remarks.—This case was interesting:—1. From the length of time the symptoms existed, *viz.*:—for nearly ten months. 2. As to the mode of origin of the mischief. 3. As to the cause of death, *viz.*:—the existence of the calculus in the bladder. Had not an impediment to the escape of urine from the bladder been caused by the pressure of this calculus, it is probable that the case would not have terminated so speedily. Probably fæcal matter had lodged at the bottom of one of the false diverticula, and had produced ulceration, owing to which an abscess was formed external to the bowel, which had eventually communicated with the bladder. This abscess, although circumscribed at first, had become latterly a diffused one, in consequence of the impediment to the flow of urine along the urethra.

SYDNEY JONES, M.B., *7th of December*, 1858.

---

5. *Enormous Hydatid Tumour of the Omentum, accompanied by nine small Hydatid Tumours.*

The large tumour was situated on the right side of the liver which it pushed to the left. It was adherent to the liver, the abdominal parietes and the diaphragm: and, at the time of death, was on the point of opening through the diaphragm, a little to the right of the trefoil tendon. It contained two hundred and ninety ounces of a puriform liquid of specific gravity 1023, besides

hydatid cysts, most of them broken and collapsed, which, when strained off, filled a quart vessel. Between the liver and stomach, and attached to both viscera, was an hydatid cyst, the size of a walnut; in the great omentum were five others, varying from the size of a large orange to that of a filbert; attached to the left colic omentum, three others.

The large tumour accompanied by the small ones might be likened to a hen with a brood of chickens..

The specimen was exhibited as evidence :—

1. That old hydatid tumours in other parts besides the liver, have a tendency to suppurate. 2. That a hydatid cyst in the mesentery, where it is not surrounded by a dense tissue, not only casts off secondary cysts from its inner surface—the so-called floating hydatids—which, after detachment, may grow to the size of an orange; but that it also casts off secondary cysts from its outer surface, to become independent hydatid tumours.

The patient was a lithographic printer, æt. 36, and the tumour in the right side, which subsequently attained such enormous dimensions was first noticed by him seven years before his death.

The last two years of his life when the tumour had grown very large, he was occasionally laid up for a few days by attacks of pain in the side, or a temporary jaundice: but, except at these times, was constantly able to do a day's work. In the beginning of November, 1858, in consequence, as he supposed, of exposure to cold, he was taken with shivering and violent pain in the right side; symptoms soon followed attended by a high degree of fever.

On the 26th of November, he was admitted into King's College Hospital, suffering much from shortness of breath and pain in the side and fever.

On the 2nd of December, two days before death, the tumour was tapped, but whether from want of elasticity in the sac, or from the end of the canula getting obstructed by a floating hydatid, no fluid escaped.

Dr. Budd, 21*st of December*, 1858.

---

6. *Two specimens of Perforating Ulcer of the Small Intestine in Typhoïd Fever.*

The first specimen was obtained from the body of a male patient, æt. 19, who died under my care in the London Fever Hospital, on the 29th of August, 1858, on the twentieth day of the fever, and on the tenth of his sojourn in the Hospital. He had all the symptoms of typhoïd fever well marked, including an eruption of successive crops of rose-coloured papulæ, dry red tongue, ultimately becoming brown, abdominal pain, and urgent diarrhœa. He had also from the date of his admission, especially at night, much noisy delirium and restlessness. For two days before death, he passed a large quantity of liquid blood per rectum; but the case was remarkable, inasmuch as there were no symptoms to indicate that perforation had taken place. There was no sudden aggravation of the symptoms, no increase of the abdominal pain or tympanites, and there had been no vomiting throughout. There was also no increase in the rapidity of the pulse, which, however, had been 130 on admission.

On opening the abdomen after death, there were found all the signs of recent peritonitis. There was fine punctiform injection of the whole of the peritoneal surface of the abdominal parietes and the small intestines, and the coils of the latter were loosely adherent by flaky lymph. In the pelvic cavity there was half-a-pint of a dirty yellow fluid having a fæcal odour, and evidently escaped from the bowel. Twelve inches from the ileo-colic valve there was a perforation of the ileum. This perforation was of a crescentic form, about one-eighth of an inch in its long diameter, and formed one margin of an opaque-yellow sphacelated patch of the coats of the bowel, measuring one-third of an inch in diameter. The margins of this sphacelated patch were pretty firmly adherent, except at the perforation, and the surrounding peritoneum was much congested, and of a bright-red colour. The perforation itself was partially blocked up by a small loose particle of slough, probably from the interior of the bowel. On opening the ileum, the lower four inches of it presented one mass of ulceration, and for twelve inches further up many of the solitary glands, and five or six of Peyer's patches

were ulcerated. In one of the latter, the perforation had taken place. The ulcers were covered with loosely adherent yellow sloughs, and their edges were raised, indurated, and irregular. The mesenteric glands were greatly enlarged, and there were a few of the solitary glands in the cæcum and ascending colon indurated and ulcerated.

The second specimen was taken from the body of a man, æt. 21, who died on the twenty-fifth day of the fever. The case furnished a good example of what not infrequently occurs, *viz*:—the supervention of perforation and fatal peritonitis in the course of what had previously been considered a mild attack of fever. Up to the twenty-third day, the symptoms were not such as to lead to any apprehension of danger. The patient slept well, had no delirium or restlessness, and was perfectly conscious. There was diarrhœa, but by no means urgent, and there was no tenderness even on firm pressure of the abdomen. The pulse seldom rose above 90, and the patient could get up without assistance. On the twenty-third day, forty-two hours before death, the pulse rose to 120, and he had a sudden attack of pain in the lower and right side of the abdomen, which gradually proceeded upwards. The abdomen was exquisitely tender. These symptoms were followed by urgent diarrhœa and vomiting, and shortly before death the vomited matters had a distinctly fæculent odour. Profound collapse ensued; but the patient continued perfectly sensible till within a few minutes of death.

After death, there were all the signs of recent peritonitis. There was about a pint and a-half of yellowish fluid with flakes of lymph, but with no fæcal odour, in the peritoneal cavity. The omentum was glued to the surface of the intestines, and the coils of these to each other, by soft lymph. The lower eight feet of the ileum were intensely congested, and of a bright-strawberry colour. There were numerous ulcers in the lower three feet and a-half of the ileum, but the sloughs had separated from the surface of all of them. Five inches and a-half from the ileo-colic valve was an ulcer, the size of a shilling, and at one part of this was a perforation, just large enough to admit a number one catheter. Its edges had been glued to an adjoining fold of the intestine, and

so the contents of the bowel had been prevented escaping in any quantity.

Perforation of the intestine, involving fatal peritonitis, is probably a more frequent mode of fatal termination in typhoïd fever, than is generally believed. Out of fifty-five cases examined by Louis after death, and recorded in his work, perforation was found in eight. Of fifteen cases examined by myself, it existed in three; and of sixty-three post-mortems of typhoïd fever mentioned in the Annual Reports of the London Fever Hospital, there was perforation in twelve. Putting all these together we have one hundred and thirty-three fatal cases, in twenty-three of which there was perforation, or a proportion of 1 in $5\frac{18}{23}$. Five of the eight cases recorded by Louis, resembled the second, which I have just brought under the notice of the Society, in the circumstance that the symptoms of the disease were very mild, or almost completely latent, up to the occurrence of the perforation. In five also of the eight cases, the perforation was ushered in by severe and well-marked symptoms; but in three, its advent was latent.

Dr. Murchison, 21*st of December*, 1858.

---

7. *Colloïd Cancer of the Sigmoïd Flexure of the Colon, causing Stricture and Obstruction, complicated with incarcerated Hernia.*

A. B., æt. 68, a man, of spare habit and nervous temperament, consulted me on the 21st of last October, for constipation and a feeling of general uneasiness and pain in the bowels; he said he had been suffering at occasional intervals from similar attacks for the last six months, which however, had passed off in a few days. I prescribed an ordinary purgative mixture, and saw him again on the 23rd,—his symptoms were unrelieved, and other aperient medicines were substituted for the mixture.

Late at night on the same day, he was seized with violent vomiting, and as he resided at some distance from Town, medical assistance was obtained near at hand.

The matter vomited was of a decidedly fæcal character, and was occasioned by a small strangulated inguinal hernia on the right side; it was soon reduced by taxis, and followed by an im-

mediate remission of the symptoms. The bowels were freely relieved for the three or four following days, and although complaining of general lassitude, he continued to progress favourably until the 12th of November, on the evening of which day vomiting recurred, but this time it was not of a fæcal nature; the bowels had become more sluggish for two or three days previous to this occurrence. On the 17th I was called to see him, in conjunction with the gentleman who had been in attendance. The bowels had remained obstinately costive since the renewed attack, and vomiting was frequent, especially after nutriment however cautiously given or slight in quantity. The abdomen was distended and tympanitic; the sickness was at times, preceded by severe attacks of pains which created much suffering.

On careful examination by percussion, a marked but limited extent of dulness was observable in the left pelvic region, but no great pain was occasioned by pressure on the abdomen; pulse natural; tongue slightly furred; countenance anxious; altogether his physical powers seemed less impaired than might have been anticipated under such a state of things. The hernia, which had been carefully replaced whenever it protruded since the recurrence of the attack, was not down, and the boundaries of the ring could be well defined.

I saw him again on the following day (18th), all the symptoms were altered for the worse, with the exception, that a very slight clay-coloured motion had been voided after an enema. As far as could be ascertained by examination of the rectum with the finger, no obstruction of the bowel existed. It was now quite obvious, that whatever its cause, the obstruction was of a serious nature, six days having elapsed without any satisfactory evacuation. The question of the possibility of relief by operation was now entertained, but the proposal was met by a peremptory refusal on the part of the patient and his friends.

Under these circumstances, it was resolved to abstain, as had been done for the most part for two or three days past, from purgative medicines of any kind. The after treatment consisted in the occasional exhibition of opiates, and the frequent use of enemata of various sorts, such as turpentine, castor oil, croton oil, &c., &c. O'Beirne's tube was employed, which on most occasions

could be passed to the extent of at least twenty inches, and without causing severe pain.

Small quantities of brandy-and-water, wine, beef-tea, milk, &c., &c., were given at frequent intervals by way of sustenance, but these were in most instances speedily rejected. No relief was obtained, the symptoms gradually increased in intensity, he became extremely emaciated, and latterly had occasional fits of delirium, the result apparently of inanition and exhaustion. He died the 1st of December, being nineteen days from the period of the second attack.

Post-mortem examination, seventy-four hours after death.

Body greatly emaciated, abdomen extremely distended. On exposing its cavity, the distention was seen to be occasioned by the colon, which was largely distended throughout its entire course. A small protrusion of the peritoneal coat, about the size of a large hazel-nut, was observed on the descending colon at its most projecting part; this was caused by rupture of the internal coats of the intestine, which, had the patient survived a short time longer, must have terminated in perforation.

The sigmoïd flexure was entirely overlapped and concealed by the descending colon, and was loaded with a considerable quantity of solid and semifluid fæces; it terminated abruptly in a large pouch, where a hardened mass was felt, below which the intestine was firmly constricted. The rectum was now divided low down, dissected upwards and removed together with a portion of the sigmoïd flexure, including the diseased mass which was of moderate size—the rectum was somewhat twisted below this point—the forefinger could be passed through the stricture, and on dividing it, the colloïd mass was exposed.

This case is interesting on account of the little cause that appeared to exist for suspecting the true nature of the intestinal obstruction, and its complication with hernial symptoms at the outset, by which the diagnosis was rendered more difficult. In its earlier aspect, I was inclined to regard the case as one in which the hernia had been returned "en masse." This opinion seemed to be borne out by the limited amount of dulness observable on percussion in the left iliac region, already described, a circumstance afterwards explained by the post-mortem appearances,

viz.:—the overlapping of the sigmoïd flexure, by the distended descending colon, from which only a clear tympanitic sound was elicited by percussion, thus masking the otherwise extensive dulness that must have arisen from the impacted fæces in the subjacent portion of the intestine.

I may also observe, that I had attended this patient throughout a period of twelve years, at various times, for attacks of illness, such as skin eczema, rheumatism, bronchitis, &c., but none of these were of a lasting or serious nature.

For the last two years, it was remarked by himself and friends, that he had never enjoyed better health, and he was exceedingly active for a man of his age.

It is also worthy of note, that in none of his former attacks, until the period mentioned (six months), had the bowels ever been costive, free and full evacuations having always been readily obtained by mild purgative medicines. The preceding adds another to the many instances already recorded, of the difficulty and obscurity of the diagnosis in cases of permanent intestinal obstruction.

The microscopic appearances were such as are usually described as characteristic of colloïd formations.

Mr. Oliver Chalk, 21*st of December*, 1858.

---

8. *Pharynx of a Child aged Two Years and a-half, affected with Scarlatinous Membranous Angina.*

The history of the case is as follows:—The child had no symptoms excepting slight headache and heat of the skin, until forty-eight hours before the occurrence of the fatal result. At that period, hoarseness was first noticed by the parents. During the two following days the hoarseness continued, but there was no marked dyspnœa or other alarming symptom. The child was lively, talked constantly, and could not be kept in bed. During the last day, there was some fœtid discharge from the fauces and nares. The next morning, his mother found him "catching for breath," and tossing about in bed, and in a few minutes he was dead.

The condition of the affected parts is as follows:—The whole

pharyngeal cavity is lined with a whitish false membrane of firm consistence and laminated which extends anteriorly to the commencement of the hard palate and anterior pillars of the fauces, and superiorly into the nares, while inferiorly its margin coincides with the commencement of the œsophagus and the margins of the epiglottis and aryteno-epiglottidean folds. The membrane is thickest on the tonsils, uvula, and velum, both sides of which are covered. In the pharyngeal cavity it is thinner, and appears here and there to be detached. At the commencement of the œsophagus, it ceases abruptly, by an irregular but continuous raised margin.

The laryngeal mucous membrane appears natural. The upper surface of the epiglottis, and the mucous membrane between that organ and the tongue, are covered with a thick layer, which extends across from one tonsil to the other. On detaching the false membrane, the subjacent mucous tissue is seen to be highly congested, and presents an appearance which reminds one of a blistered surface. When examined microscopically, the membrane is found to consist exclusively of fibrine.

The brother of this child was subsequently similarly affected, but with this difference, that the scarlatinous rash manifested itself distinctly. The treatment, which at first seemed successful, consisted in the administration of wine, beef-tea, and a mixture containing chlorate of potash; and the strong hydrochloric acid was applied to the fauces. I was prevented by illness from continuing the care of the case, but learnt afterwards, that this child died unexpectedly in the same manner as his brother.

The importance of the case lies in the fact, that while on the one hand the scarlatinal element was undoubtedly present, on the other, the affected parts exhibit all the characters of true pharyngeal diphtherite. Dr. SANDERSON, *4th of January*, 1859.

---

9. *Extensive Dilatation of the Œsophagus.*

B. C., æt. 60. First seen on the 12th of March, 1858, labouring under chronic bronchitis. She had for some time been losing flesh and strength. The cough and expectoration soon became much diminished, but the emaciation became greater, and the

weakness increased so that she was obliged to keep her bed. She had no pain, and made no complaint except of increasing weakness, and an entire loss of appetite. I could detect no sign of special disease in any organ.

She died on the 26th of May. On the evening before her death, she was more cheerful than usual; took some beef-tea at ten P.M.; was quiet during the night; had some refreshment at eight A.M.; suddenly became faint, and died in half-an-hour.

Post-mortem examination.—The lungs and heart were healthy. The pericardium was adherent. There was a considerable amount of thick fibroïd tissue around the ascending aorta and trunk of the pulmonary artery, embedded in which were numerous masses of softish cheesy tubercle. The bronchial glands were much enlarged, and loaded with yellow cheese-like tubercle; some were entirely occupied by this deposit; others consisted partly of this and partly of melanotic tissue, whilst others contained either a soft mortary material or distinct pus. The entire mass was about half as large as the fist; it was firmly adherent to the front of the œsophagus and to the trachea, and was continuous with the fibroïd tissue which surrounded the origins of the great vessels. On removing the right lung, and before disturbing the heart, a fluctuating ovoïd swelling, several inches long and capable of holding a swan's egg, was observed, connected with the posterior mediastinum and projecting into the right pleura. It was the œsophagus greatly dilated. The dilatation commenced about two inches below the rima glottidis; it increased gradually to the commencement of the lower third where it was five inches and a-half in circumference, and then diminished, so that at the cardia it was of natural size. The mucous membrane was not congested or ulcerated, but it presented numerous shallow circular pits, which appeared to have been produced merely by distention of the tube. The muscular coat was much thickened; but its fibres were quite healthy.

The stomach was quite healthy.

The abdomen contained a little puriform fluid in the dependent parts. The entire surface of the peritoneum was covered by soft, recently-deposited lymph, causing slight adhesions between contiguous parts. For the most part this formed a thin layer;

but between the liver and diaphragm, in the lumbar regions, and in the pelvis, it existed as a thick reticulated mass. Adhesions had formed between the lower surface of the liver, the stomach, and duodenum, so as to form a thin irregular cavity several inches square, containing pus.

In the duodenum were two small ulcers, of these one was cicatrized, but the other perforated the gut and communicated with the cavity just described. The remainder of the intestine was healthy.

The liver contained one mass of tubercle, similar to that in other parts, about the size of a horse-bean. The organ was large, but otherwise healthy.

Dr. Barker, *4th of January*, 1859.

---

10. *Carcinomatous Stricture of the Œsophagus.*

A man, æt. 61, was admitted into St. Thomas's Hospital on the 21st of October, 1858. He stated, that two months before he had slipped down in the street, and fell upon his chest, and that since that time he had had difficulty of swallowing, which had gradually increased, till, at the time of his admission, he was incapable of swallowing solid, and had great difficulty in taking liquid food. He felt that what he took passed down to near the lower end of the sternum, when it created great pain and generally returned. He was greatly emaciated; no tumour could be detected in any part of the abdomen. He was allowed milk, beef-tea, and brandy by the mouth, and a nutritive enema with wine, was directed to be administered every night and morning. At first, he succeeded in taking some liquid food, and improved; but after the 25th of November, he was incapable of swallowing anything; he, however, retained the enemata, when only two were given in the twenty-four hours. He died, excessively emaciated, on the 28th of December.

The body was examined by Dr. Bristowe, and excepting extensive atheromatous and earthy deposit in the coronary arteries, and that the spleen was small, dark coloured, and pulpy, disease was only found in the œsophagus. Immediately below the bifurcation of the trachea, that canal, for about an inch of its length, was very much constricted; its parietes were thick, nodulated, and infil-

trated with scirrhus, and its mucous surface was ulcerated. Above this, the tube was dilated; below, somewhat contracted.

The stomach was very small and contracted, but healthy. There were the elements of epithelial cancer, indistinctly marked about the œsophageal ulcer, and very abundant and distinct in two or three small, white, lymphatic glands in the neighbourhood.

Dr. PEACOCK, 18*th of January*, 1859.

---

11. *Ulcers of the Stomach.*

A female, æt. 21, was admitted into the Victoria Park Hospital for Diseases of the Chest, on the 12th of November, 1858. She stated, that she had been delicate for years, suffering from dyspeptic symptoms, uneasiness or pain after taking food, and occasionally sickness and vomiting. About twelve months before she had spat some blood, and the catamenia had been absent for six months.

When admitted into the Hospital her complexion was sallow, the pulse rapid and feeble, and the ankles œdematous. She did not complain of any pulmonary symptoms, but had pain at the pit of the stomach, and vomited almost all the food which she took and at times also dark-coloured fluid. The food was vomited about an hour after it had been taken. The heart's dulness was increased in extent, the sounds being noisy but without murmur; her face subsequently became puffy, and she died exhausted on the 25th.

Post-mortem examination.—The body was examined by Mr. Cousins, the House Surgeon. The lungs were œdematous, but entirely free from tubercle. The heart was enlarged, and there was considerable contraction of the left auriculo-ventricular aperture, with thickening of the mitral and tricuspid valves. The stomach, at its lesser curvature, displayed two small ulcers—one the size of the point of the forefinger, the other smaller. The edges of both were abrupt, and the largest was deeply excavated and surrounded by considerable thickening of the coats. There was also the cicatrix of a third ulcer within a short distance of the two still existing. Dr. PEACOCK, 18*th of January*, 1859.

---

12. *Stricture of the Œsophagus.*

A labouring man, æt. 56, who had for nine months suffered from difficulty of swallowing, and during the last six weeks of his life had been totally unable to pass the smallest drop of fluid into the stomach, died after the most severe suffering, and in the state of extreme emaciation. He had continually received treatment, both locally and by passing of bougies down the throat, but without receiving benefit; his pain had always been situated opposite the cartilages in the trachea.

On post-mortem examination, the œsophagus, near the cricoïd cartilage, was found contracted to such an extreme, that the ordinary dressing probe could only be passed, the surrounding tissue being hardened, and having the feel of schirrous structure; the mucous lining of the œsophagus at the stricture part, was abraded, and below the contraction ulcerated; the cartilages of the trachea had their lining membrane inflamed and swollen. This specimen was placed before a Committee for more careful examination.

Mr. Obré, 18*th of January*, 1859.

Report upon the above specimen of stricture of the œsophagus.—The stricture portion of the œsophagus is placed opposite the two or three upper rings of the trachea. The walls of the tube are hardened, thickened, and much altered in texture, the normal tissues being replaced by a dense fibrous mass very resistant to the scalpel. A similar tissue involves the posterior wall of the trachea, replacing the cartilaginous mass, and bulging into the tracheal tube. It forms a dense layer between the trachea and œsophagus, as well as around the common carotid artery, jugular vein, and pneumogastric nerve; the recurrent nerves on both sides are lost in the tumour. One lobe of the thyroïd is very hard; the disease is found mostly developed about the œsophagus, and on the posterior wall of the trachea. The mucous lining of the œsophagus is ulcerated on the anterior wall, below the strictured point, and consequently the ulceration has not been caused by the use of bougies or other instruments.

Under the microscope the abnormal tissue presents chiefly

compound cells containing several nucleolated nuclei, oval, round, and caudate in shape, packed together in a dense mass, and held by interspersed bands of laminated fibrous tissue.

The contraction of this growth around, and in the walls of the œsophagus, has given rise to the stricture.

We think the growth carcinomatous from its microscopic appearances, as well as from its manner of invasion, and replacement of the surrounding tissues. GRAILY HEWITT, M.D.

S. SIBLEY.

J. WOOD, 1*st of February*, 1859.

---

13. *Cancer of the Œsophagus, causing a large opening into the Trachea, just above the Bifurcation. Food passed from the Œsophagus into the Trachea, and rejected by Coughing.*

T. G., a man, æt. 45, was brought into the King's College Hospital, on the 29th of December, 1858, with stricture of the œsophagus, and greatly emaciated. He stated, that about fifteen months previously, he began to experience difficulty in swallowing solids, the food passing a few inches down the gullet, and then stopping for a time before passing onwards or returning.

Four months before he was brought to the Hospital, the malady had so increased, that he had great difficulty in swallowing food of any kind, whether solid or liquid. He then began to attend the Farringdon Dispensary, where an œsophagus bougie was passed three times a week. It was supposed, that he had two strictures in the œsophagus—one at the commencement of the œsophagus on a level with the thyroïd cartilage, the other some inches lower down. Three months before his admission to the Hospital he vomited blood and a week before admission he lost his voice.

After he was brought to the Hospital, no food of any kind passed into the stomach. Whatever he swallowed was regurgitated after a time, or passed into the windpipe and was rejected by coughing. In intervals of swallowing he had cough, and, in addition to portions of food, he rejected by coughing in twenty-four hours about twenty-four ounces of a glairy mucus. He complained of pain where the food stopped.

The œsophagus was explored by a small bougie, which passed with difficulty the supposed stricture at the commencement of the œsophagus, and was arrested lower down. The poor man grew gradually weaker, and died at one A.M. on the 5th of January.

On post-mortem examination there was found great cancerous thickening of the whole circumference of the œsophagus, forming a considerable tumour, for a length of two inches, extending upwards from the bifurcation of the trachea. The tumour extended a short distance along the left bronchus, and was grooved by the arch of the aorta. The anterior wall of the œsophagus and the posterior wall of the trachea just above the bifurcation, for the space of an inch, had ulcerated away, so as to form one large cavity common to both tubes. There was no organic stricture at the upper part of the œsophagus. The lungs were slightly adherent behind to the pleura costalis. The lower lobes were partially carnified and non-crepitant, and contained much frothy fluid. The upper lobes were crepitant and quite healthy. The body was extremely emaciated.

Dr. BUDD, 1*st of February*, 1859.

---

14. *Malignant Fibroïd Disease of the Stomach.*

This specimen is one which formerly would simply have received the designation cancer, but in reality, it holds an intermediate position between a purely innocent and malignant growth, resembling very closely the recurrent fibroïd tumours removed by the surgeon from the exterior of the body. There is little doubt, that this form of disease may attack the internal parts of the body, for already examples of recurrent fibroïd disease of the uterus and of the lung have been presented to the Society; as regards that of the uterus, the intermediate character of the growth or its semi-malignancy is well seen, both in the microscopic elements which form it, as well as in its mode of growth, for it usually springs from a large surface of the interior, and thus is distinguishable from an isolated polypus, or a cancer eating away the tissue. So the present specimen seems to hold a similar position in the scale of adventitious growths.

This preparation of stomach and ovaries (which are also conconverted into fibroïd tumours), came from a girl, æt. 18, who lately died under Dr. Addison in Guy's Hospital. When admitted, she had been suffering about four months with severe gastric symptoms; a tumour could be felt at the epigastrium, and two others at the lower part of the abdomen; she lived three months longer, so that the duration of the disease was about seven months.

The lungs and the liver were healthy, and indeed all parts of the body excepting the stomach and ovaries. The former occupied its usual site, but was seen to be converted into a tumour by immense thickening of the coats of the pyloric half, so that there was a distinct ridge or elevation at the line where the diseased met the healthy cardiac part. The whole organ was enlarged, and when removed and cut open, exhibited the peculiarity of the disease still better; the thickening of the walls commenced at the pylorus, and continued thus as far as the middle of the organ where it abruptly terminated, and the healthy remaining half began. The adventitious tissue was moderately firm, but could not be broken by any ordinary pressure with the finger, although it could be easily torn, by which its fibrous structure was displayed. It emitted on pressure only a little serum which by the microscope displayed small nuclei, and the tissue itself was found to consist of simple fibre and nucleated fibre. The disease had probably commenced in the submucous tissue as in scirrhous pylorus, and then proceeded onward until the middle of the stomach was reached; the coats were thus infiltrated and immensely thickened, but the disease was confined to them, for, although the mucous membrane was involved in the disease, yet nowhere was there any breach of surface or ulceration, and it was the same with the peritoneal surface which was everywhere intact; the diseased mass, however, protruded as a small nodule in the lesser curvature, and caused an adhesion of the pancreas. A section of the diseased mass showed the muscular coat occupying various positions, now nearer the inner, and now nearer the outer surface, just as the adventitious tissue was in greater quantity in the submucous coat or beneath the peritoneum. The whole mass of disease was of a white colour, and resembled more a thick slice cut

from a fibroïd tumour than a stomach. The ovaries were converted into fibrous tumours having the same structure as the stomach, each being about the size of an ordinary sized cocoa-nut.

The semi-malignant character of this disease, and its resemblance to recurrent fibroïd growths is perfect in every respect, both in regard to the nature of the tissue itself, as well as its mode of increase. Its malignant tendency is seen in its involving so large a part of the stomach, and in the ovaries being also affected, while its more innocent character is exhibited in its limitation to these parts, and the absence of disease both in the liver and lungs; and also in there being no destruction of tissue, and the boundaries of the disease being so well defined. The youth of the patient too may also be remembered.

It may be remarked, how the microscopic elements correspond to the whole character of the growth, and yet what a discrepancy of opinion would exist should the microscopist assert that nothing but a cell growth is malignant, and the ordinary observer maintain that a disease like this is cancer. It shows, also, that some other term referrible to the nature of the disease would be more desirable than recurrent, which applies only to a manifestation of its character under particular circumstances.

Dr. Wilks, 1*st of February*, 1859.

---

15. *Case of Enteritis.*

W. G., a painter, æt. 50, was admitted into St. Thomas's Hospital, on the evening of the 13th of September, 1858. No satisfactory history of the patient could be obtained; but it appeared that he had been for some time a great drinker; that he had been constipated for two or three days; and had been taken ill on the morning of admission with symptoms which were presumed to be those of lead colic. He had never previously suffered from poisoning by lead.

On admission he was labouring under severe abdominal pain, and the abdomen itself was very tympanitic. The resident officer who was called to him, regarded his case as one of lead colic; and ordered him five grains of calomel, one grain of opium, and half a grain of antimony at once, also a hot slipper bath, a mustard

poultice to the belly, and a dose of castor oil after four hours, if required.

The man was easier for a time after the bath, but the pain soon returned. It was necessary to give the castor oil, and it is stated that it operated; at all events, soon after its administration, he seemed to become easier, and was thought to sleep. But shortly afterwards, the nurse found him very pale and faint, and breathing only at long intervals. Before medical assistance could be rendered he was dead.

Post-mortem examination. — In good condition. Pericardium and heart healthy. The ventricles of the latter were contracted and empty. There were a few old pleural adhesions, but the lungs were healthy.

The abdomen was extremely distended, and on laying it open its distention was found to be due to enormous dilatation of the large intestines, and especially of the sigmoïd flexure; which latter, with its meso-colon, formed a crescentric mass extending from the sternum to the pelvis; and, almost concealing all the other abdominal viscera, reached over to the extreme right of the belly. The peritoneum contained about a quart of serum, but was entirely free from inflammatory exudation. The stomach was perfectly healthy. The small intestines were somewhat dilated, and in several places presented large subserous patches of intense congestion; but the mucous membrane was healthy throughout, and the contents were normal. The cæcum, and the ascending, transverse and descending portions of the colon were much dilated; especially the transvere portion, which measured between seven and eight inches in circumference. Their outer surface was generally healthy, but presented a few congested patches; their mucous membrane was healthy, without congestion or marked softening. The sigmoïd flexure measured a yard in length, and in the greater part of its course twelve inches in circumference. Its external surface was smooth, presented a slate-colour, was here and there deeply congested; and its appendices epiploicæ were small and highly injected. The mucous membrane was perfectly black and softened, yet whole and without any gangrenous odour. The blackening was not merely superficial, but occupied the whole of the mucous and submucous tissues, which measured

about a line in thickness, and were fleshy in consistence though lacerable. On close inspection, the blackness was found to have a reddish tinge, which was especially distinct on the surface adjoining the muscular coat; and it became quite clear, that the extraordinary appearance was due to intense congestion, with uniform extravasation of blood into the affected tissues. The diseased condition ceased abruptly at both the upper and lower terminations of the sigmoïd flexure. The muscular coat was thin and perfectly healthy in appearance. The rectum was of normal calibre and healthy throughout; and that portion continuous with the sigmoïd flexure was longitudinally folded as though it had been actively contracted before death. The diseased portion of bowel was almost completely filled by thick dark reddish-brown fluid, without any clot or other solid matter. A considerable quantity of similar fluid was observed also in the descending and transverse colon; but traces only in the contracted rectum. At first sight it seemed certain, from the enormous distention of the bowel, together with the increased thickness of its walls, that the process which had produced the diseased state must have been a chronic one; but when it was found that the increased thickness depended on the infiltration of the mucous coat with blood, and that the muscular coat was really thinned, it then seemed possible that the disease was, as the history indicated, entirely recent—that intense enteritis having occurred, accompanied by paralysis of the muscular coat, the bowel had become flaccid, and ultimately distended by the large amount of secretion accumulated in its interior. The mucous tissue was examined under the microscope, and found to be infiltrated with blood, a fact indicated by the abundance of blood corpuscles which concealed nearly everything else. The follicles appeared generally to contain healthy epithelium. The muscular coat of the diseased intestine presented healthy ultimate structure.

All the remaining abdominal viscera were healthy.

Dr. Bristowe, *15th of February*, 1859.

---

16. *The Ulceration of the Appendix Vermiformis.*

The subject of this case was a boy æt. 12, who had always enjoyed good health, and was strong and robust. During the latter part of last summer he occasionally complained of pain in the region of the cæcum, but it was generally of short duration. He was in the country, seventy miles from London, when he was seized, on the 10th of January, with pain in the lower part of the abdomen; hot fomentations were used, and aperient medicines given, but he had no medical advice until the 13th, when acute symptoms set in. Leeches were applied, and other means to combat inflammation were resorted to; the bowels could not be moved for three days, and from the commencement of the attack there was great constipation. The boy improved so much, that he was brought to London on the 21st, when he came under the care of Messrs. Skegg and Verdon, of Charing Cross, with whom I saw him. The abdomen was hard, and tender on pressure; the face was nipped up, and the food frequently rejected by regurgitation, without much effort. The bowels much constipated, and only moved by enemata and castor oil. For a few days the patient appeared to be improving, but the symptoms on the 1st of February assumed a more unfavourable aspect, and he died on the 5th. The abdomen was never tympanitic after his return to London; but over the navel, a few days before his death, was a small puffy circumscribed tumour.

Post-mortem examination.—A large amount of lymph, of a yellowish colour, and in some places a-quarter of an inch in thickness, was deposited on various parts of the intestines, which were so matted together as to prevent their peristaltic motion. In the peritoneal cavity, was a quantity of yellow, semi-purulent fluid, and a portion of the same kind of fluid was confined by adhesions under the navel, giving rise to the tumour before spoken of. On examining the appendix vermiformis, an opening was seen about half-an-inch from its extremity, which would admit a common sized goose-quill, and opposite to this was a smaller opening. The edges of both were rather ragged and of a dark colour; there was no thickening of the mucous membrane, and the only abnormal appearance when microscopically examined, was the presence of a few

injected vessels, having a stellate arrangement on the lining membrane of the cæcum and appendix. We omitted to make search for an extraneous body in the fluid found in the abdomen.

Remarks.—One feature I think of especial interest in this case is, the long duration of life after the perforation of the appendix. Although no foreign body was found, there can be but little doubt, judging from recorded cases, that ulceration was occasioned by extraneous matter; its circumscribed character, and the absence of surrounding disease, are, I think, especially indicative of this. In five cases which I had seen of this lesion, all the patients were males, and from this circumstance, I was induced to collect all the recorded examples of extraneous bodies in the appendix that I could find; they amount to thirty-two, and the subjoined is a summary:—*Sex.* 29 males; 3 females. *Age.* Under ten, 5; between ten and twenty, 13; between twenty and forty, 7; between forty and sixty, 7.

Nature of extraneous bodies.—In three cases, hairs or bristles; in two, bone; in two, a pin; and in the others, a human tooth, a cherry stone, the shell of a hazel-nut, fig seeds, and raisin seeds, 12.

Concretions of various kinds, 17.—Consisting of dry excrementitious matter; sometimes calculous and in other instances waxy, and varying in size from a pea to a plum stone. In three, the extraneous body was not looked for, although the probability of its existence was great. The comparative frequency of these bodies in males is very remarkable. I thought this had been first noticed by myself, but I found that Volz (*see Archiv. Gen. de Medecine*), 1844, had collected twenty cases, the subjects of three of which were women, and seventeen men; the table of cases is not given, nor is any explanation offered of the supposed cause. I am inclined to think that the greater and more extended motion of the right lower limb, in males, which to some extent must affect the contents of the cæcum, is the most probable cause.

Dr. Crisp, 15*th of February*, 1859.

---

17. *Fatal Obstruction, from Twisting of the Meso-colon.*

The case was that of a man, æt. 45, who was attacked on November 10th with diarrhœa, which ceased on the 12th. On the 13th he became occasionally sick, and complained of some pain deep in the vesical region, which became paroxysmal and progressively severe, the paroxysms intermitting every twelve or fifteen minutes until his death. The abdomen became generally painful and tympanitic, especially along the whole of the left side where an unusually hard and broad ridge was felt, extending from the region of the stomach to the bladder. He passed an abundance of urine; his pulse was rapid and feeble; his tongue clean; features anxious; and he was especially desirous to avoid the recumbent posture, or exposure to heat. A hot bath, which was ordered, embarrassed his respiration, so that after a very few minutes he was obliged to be removed from it for fear of asphyxia. On the 15th he died, almost suddenly, after complaining of severe oppression at the præcordia.

Post-mortem examination, twenty-four hours after death.—The body was muscular and well covered with fat. The peritoneum contained a considerable quantity of bloody serum. In the epigastric region was seen the transverse colon with the omentum stretched and adherent to the abdominal parietes on the left of the umbilicus. The convolutions of small intestine on the right side were healthy, but distended with flatus. The left side of the abdominal cavity was entirely occupied by the sigmoïd flexure, lying, as an enormous knuckle, obliquely from the diaphragm, which it had forced high up into the chest. Here the meso-colon, which was greatly thickened and elongated, had made a twist-and-a-half on itself, the intestine so accompanying its meso-colon, that the first portion of the flexure had wound itself around and firmly girthed the last portion. The whole of the gut was enormously distended by flatus and fluid fæcal matter, and was livid by reason of recent and all but complete strangulation of its vessels.

Remarks.—Mr. Gay thought the difficulty in recognizing this source of obstruction during life is not so great as in the case of

other forms, and detailed some cases, in order to show that the setting in of the final symptoms by diarrhœa, which does not always give way to complete obstruction, the slight vomiting, abundance of urine, the left abdominal ridge of distended and tympanitic bowel, and the use of O'Bierne's tube, are sufficient to indicate the disorder. Mr. Gay observed, during the post-mortem examination, that the tightness of the twist was in proportion to the distention of the bowel. If the bowel was partially untwisted, and then released, it would spring back forcibly to its abnormal position; but this tendency became less strongly marked as the bowel was at the same time evacuated of its contents, until at length it required but a little gentle manipulation to restore it, and that without any marked disposition again to become twisted. With a tube, per rectum, the bowel could, after some little trouble in passing it, be relieved of its contents; and then, by rolling the body over, the bowel righted itself. Mr. Gay thought, that by these means, during life, the obstruction in these cases might possibly be overcome. The application of cold, Mr. Gay thought, has an important advantage over heat in the treatment of most cases of intestinal obstruction. The latter, by rarifying the air in the bowels, tends generally to embarrass the respiratory functions as well as to aggravate the physical condition of the intestine upon which the obstruction depends.

Mr. Gay, *2nd of March*, 1859.

---

18. *Stricture of the Ileum, with accumulation of Plum-stones above the seat of Stricture. Malarious Symptoms.*

W. C., æt. 54, a coal-porter, residing in Bermondsey, was admitted into St. Thomas's Hospital on the 14th of May, 1858. He stated, that he had been poorly for twelve months, and was first seized with pinching pain in the stomach; in three months this pain became so severe that he was incapable of following his employment, and, about the same time he observed that the abdomen was swollen and he lost flesh rapidly. He had previously never had any serious illness, except typhus fever twelve years before. For some time before his admission into the Hospital he had attended as an out-patient. When admitted, he was very

anæmic, his face was puffy and pallid, his abdomen tumid, and the ankles and legs somewhat œdematous, but he was otherwise thin and emaciated. His pulse was quick but feeble; he had but little appetite, and the bowels were torpid. There was some bronchitic rhronchus audible in all parts of the chest, but on careful examination, no evidence of disease was detected in the lungs, heart, liver, or kidneys. He was directed to take mild alteratives and diuretics with the "tinctura ferri sesquichloridi" and a generous diet was ordered. On the 19th, in the evening, he was seized with pain extending across the abdomen, and was sick and vomited several times. On the 25th he asserted that, with more or less severity, every day, he had distinct aguish attacks, commencing with rigors and then going on to heat and some sweating. It appeared on inquiry, that he had had ague twenty-five years before, and had lived in Greenwich and Bermondsey ever since. The splenic dulness was increased in extent, but the gland could not be felt in the abdomen. Under the idea that his symptoms were referrible to malarious influence he was directed to take five grains of quinidine three times daily.

On the 1st of November, he stated, that the paroxsyms ceased after taking the quinidine, and he was free from them till the 30th, when they recurred, and he was extremely prostrated during the following day. The dose of quinidine was increased to ten grains.

On the 8th, he reported that he had no attack till the 6th, when he was again seized with rigors, sickness and vomiting, followed by heat, but without sweating. He was directed to have a morphia pill at night. On the 22nd, as the attacks continued to recur and still resembled imperfect aguish paroxysms, the quinidine was discontinued, and he was directed to have five minims of the "liq. potassæ arsenitis" three times daily. After taking the remedy for two days, he had so severe an attack of pain in the abdomen and sickness that it was suspended, and, as after an interval, the paroxysms still occurred, the quinidine was again given, but was discontinued on the 16th of December from the recurrence of the sickness. From this time he took only the morphia at night, and, when suffering from pain, during the day. He gradually sank; the attacks of rigors, sickness and

pain, though less violent, still occasionally occurred. He could take very little food, but the bowels were acted upon once or twice daily. He had a more frequent cough, and some little expectoration, but only of ordinary mucus; his breathing was also somewhat difficult. The dropsical symptoms had increased during the period of his residence in the Hospital, and latterly he was very anasarcous, and the abdomen, though tympanitic, also contained some fluid. The pulse was very feeble, but regular, and the heart's-sounds natural. The urine was repeatedly examined; it was of low specific gravity, but never contained albumen.

He died exhausted on the 21st of January, 1859.

Post-mortem examination.—Pericardium and heart healthy. The left pleura held about three pints of clear serum, and was unadherent. The left lung was much compressed, and crepitant in the upper half only. The right pleura contained half-a-pint of rather turbid fluid; there were a few old adhesions above, and a film of recent lymph over the middle lobe. The upper- and lowermost lobes of the lung were for the most part crepitant; but near the apex of the former was a small cavity in the midst of a fibrinous mass; and in the latter, a patch of consolidation as large as a pigeon's egg. The middle lobe was large and heavy; and on section was found to be solid, airless, very lacerable, infiltrated with pus, and in several places broken down into cavities. Bronchial tubes, trachea and larynx healthy. The stomach and duodenum were natural. The whole length of the jejunum, and the upper third or half of the ileum were much dilated, measuring from four to five inches in circumference. The parietes were at the same time thickened,—the muscular coat being much hypertrophied; the mucous coat, thick, tough, spotted with black discolorations, smooth on the surface and marked by very few, low, cord-like valvulæ conniventes. The enlargement increased somewhat from above downwards, and attained its highest degree about the junction of the upper and middle thirds of the ileum, immediately below which it ceased abruptly in a marked constriction accompanied by great thickening of the intestinal walls. The strictured portion was about an inch long and barely admitted the tip of the little finger. Immediately above the stricture the bowel formed an irregular pouch, the parietes of which were in

some places thinned almost to perforation, and in others crossed by cords or fræna of thickened mucous membrane, having the same relationship to the surface as the carneæ columnæ to the cardiac ventricles. In this pouch were accumulated thirty-three plum- and sixteen cherry-stones, all perfectly blackened, and half-a-dozen sound recently swallowed orange pips. There was on the right side an oblique inguinal hernial sac, which at the time of the post-mortem was empty, but into which it was evident from the position of parts that the strictured portion of the intestine had been in the habit of passing. The lower two-thirds of the ileum and the whole of the large intestine were healthy. The liver was large and rather fatty; the spleen small, pale and soft. The remaining viscera, with the peritoneum and the aorta, were in a normal condition.

Dr. Peacock,
Dr. Bristowe, *2nd of March*, 1859.

---

19. *Scirrhous and Colloïd Disease, causing complete obstruction of the Rectum, for which the Colon was Opened in the Left Loin.*

A man, æt. 56, a weaver, was admitted into the Physician's Ward of the London Hospital, January 20th, 1859, with his abdomen enlarged, tense and tympanitic, and tender throughout. The stomach rejected its contents. It appeared, that twenty-three years ago, he had been cut for stone by Mr. Aston Key; that during the last two or three years he had experienced difficulty in passing his fæces, but no pain, and they had become smaller in calibre and flattened. For a period of twelve months, he had suffered a dead pain in the lower lumbar region. A month previously, he was attacked with more than usual pain in the back, which extended to the legs, and rendered him unable to work. He applied for advice, and was given medicine, which purged him a good deal for about a week; but after this his bowels refused to act, notwithstanding the frequent administration of purgative medicine. There was a constant mucous discharge from the anus, and more or less sickness. He was ordered castor oil mixture and injections per anum. The latter returned. Castor oil and turpentine were rubbed over the abdomen, and galvanism was

applied to the same region. During the 21st, the abdomen increased in size and became painful, and his pulse advanced from 100 to 140. In the evening a grain of opium was given to him every four hours.

I was requested to see him on the the 22nd, two days after his admission. The vomiting continued; his countenance was drawn and anxious, and his pulse small and feeble. On digital examination, I detected an obstruction in the rectum, as high up as the finger would reach, through which I was unable to pass a small sized long tube. My colleagues, who were present, agreeing with me, that the only chance of saving life was the performance of an operation for artificial anus, the man was carried to the operating theatre, and I opened the descending colon in the left loin. The bowel was found very readily, and was opened external to the peritoneum, when a moderate quantity of gas and fæces escaped. Scarcely any blood was lost. The patient was removed to bed rather exhausted. He was ordered two grains of opium, and wine and beef-tea. The sickness continued; the tension and pain in the abdomen remained unrelieved; he gradually got weaker, and died twenty hours after the operation.

Post-mortem examination twenty-six hours after death.—Abdomen alone examined. The convolutions of the intestines were bound to each other, and to the parietal peritoneum by flakes of coagulable lymph, the quantity exuded being greatest in the pubic and right iliac regions. The adhesions were moderately firm. The ascending and tranverse colon were greatly distended. The descending colon below the point at which it had been opened behind, formed a double coil upon itself, and extended across the hypogastrium into the right iliac fossa, where it was bound down by firm white fibrous-looking adventitious tissue. From thence the intestine still dilated, turned backwards upon itself, and passed downwards into the pelvis, where it became contracted for about an inch, and connected to the bladder by a firm fibrous-looking tissue surrounding it. Below this point, the gut terminated in the usual way. The bowel was cut open, and its mucous membrane was found healthy, with the exception of occasional arboriform patches. Six inches below the artificial opening in the descending colon, the muscular coat of the bowel

was found to be about one-eighth of an inch in thickness, dense, firm, and semi-transparent, but still retaining its fibrous character. Four inches further down, the muscular coat measured one-third of an inch in thickness, and exhibited to the naked eye the characters of colloïd cancer. From this point the mucous membrane exhibited vascular patches, and was thrown into numerous deep and closely set transverse folds. The external coats appeared fused together into one hardened mass, which increased in thickness until it reached the bladder, to which it became connected by a similar looking-mass. Below the prostate, the coats of the gut presented their normal characters. The morbid product replacing the coats of the gut at the upper part, had the appearance of firm colloïd; but further down, the mass appeared to separate into two layers, the inner and thinner retaining the colloïd appearance: the outer and thicker exhibiting the characters of scirrhous. About two inches from the anus, the rectum, bladder, and prostate, were almost inseparably united to each other by a scirrhous mass.

The chief points of pathological interest in this case are—1. The circumstance of carcinomatous disease being developed in the coats of the rectum as well as external to it, to such an extent as to encroach upon and block up the passage without causing ulceration, or any serious disease of the mucous membrane; and—2. The development of the disease in parts which many years previously had been the seat of an important operation.

Mr. Curling, *15th of March*, 1859.

---

20. *Carcinoma of the Œsophagus.*

The specimen came from a patient of Dr. Wilks', who died in Guy's Hosptial, in March, 1859. He was 71 years of age, and had symptoms of constriction of the œsophagus for more than two years; this was found to be due, on post-mortem examination, to a circumscribed cancerous growth in the submucous tissue, consisting of nuclei and nucleated cells, and the neighbouring lymphatic glands were similarly affected. The interest of the specimen consisted in the fact of the composition of the deposit being ordinary cancer, and not epithelioma. Dr. Wilks observed

that he had never yet met with a case of simple stricture of œsophagus at all comparable with stricture of the urethra, but that the supposed simple cases nearly always turned out to be cancerous; and with reference to the death by pneumonia in this case, such was the mode of dissolution in by far the majority of instances, and might be attributed to three causes: to the extreme debility and low powers of the patients. whereby an inflammation is likely to be set up; to an extension of the disease of œsophagus into the root of the lung; or to an implication of the pneumogastric nerve in the cancer, whereby its nutritive influence is removed from the lung (as in Reid's experiments). The latter is a cause which has been long held to be an efficient one by Dr. Wilks' colleagues, and especially maintained by Dr. Gull; and in this instance apparently demonstrated to be the correct explanation, since the patient was walking about until he was seized with the pneumonia, and the disease of the œsophagus was not in contact with the lung; but the left pneumogastric nerve, on the same side as the pneumonia, was involved in the cancerous gland, and partly destroyed. The pneumonia in these cases, consists of a consolidation unequally diffused, and the lung giving out a dirty fluid on pressure, or even being in a state of purulent infiltration; a condition showing a very low form of inflammation.

Dr. Wilks, 15*th of March*, 1859.

---

21. *Portions of the Ileum, Cæcum, and Colon, discharged by Stool, in a case of Intus-susception. Recovery.*

The specimen presented to the Society, for which Dr. Quain was indebted to Mr. Hesilrige Buckby, of Sutton-on-Trent, consisted of about eight inches of the ileum, the cæcum with its appendix, and about four inches of the colon, which had been passed by stool. The bowels discharged presented the usual appearance of parts which had been the subject of this lesion. The tissues were dark-coloured, almost black, and smelt offensively. The edges, where separation had taken place, were irregularly rounded off by ulceration. The principal facts of the case, as supplied by Mr. Hesilrige Buckby, were as follows:—The patient was a boy, aged five years, who was taken ill four months

previously to the time at which he passed the mass of the bowel, without any evident cause. His symptoms at first were those of simple fever, and he received medicine from a druggist. When he came under Mr. Buckby's care he was suffering much distress; and with intermissions he continued to do so until the passage by the rectum of the specimen laid before the Society. The little boy complained of pain chiefly in the region of the bladder, and this was somewhat relieved by pressure: there was no tenderness. His urine was at times suppressed for as long as forty-eight hours, and was at other times free and copious, and occasionally passed with pain. His bowels were very much confined, not acting sometimes for fifty hours. He never passed blood. He had sickness, but the vomited matter was never stercoraceous. His tongue was dry and brown; at other times clean. His pulse was never under 100, more frequently it was 120. His appetite was sometimes voracious. The treatment was directed to the relief of the more urgent symptoms, and the sickness was checked by the internal use of chloroform; opium was given even in grain doses every four hours, without relief of the pain when it was severe. The discharge of the bowel was preceded and followed by diarrhœa. Subsequently, all distressing symptoms ceased, and the urine passed freely and without pain. The bowels acted regularly once in twenty-four hours. The appearance of the fæces was natural; and the little patient, at the end of six weeks, seemed in perfectly good health.

Dr. Quain, *5th of April*, 1859.

In reply to an inquiry, Mr. Buckby states that the boy has continued, and is now in excellent health. He had had an attack of diarrhœa brought on by eating unripe fruit, from which he soon recovered.—16th of August, 1859.

---

22. *Simple Stricture of the Sigmoïd Flexure; Constipation, forty-one Days, relieved by opening the Left Colon behind the Peritoneum. Death from Ulceration and Perforation immediately above the Seat of Stricture.*

A woman, æt. 39, was admitted to the Marylebone Infirmary, on

the 9th of March, 1859. I saw her first on the 11th of March, when she was brought into the surgical ward under my care, and the following notes taken:—

She is the mother of nine children, and is now pregnant about five months. Health usually good; habit rather constipated.

On Monday, the 31st of January, she had her last motion; is quite certain there has been none since. Two or three days before, she lifted a heavy weight and "felt something give way in her stomach."

Has had much purgative treatment during five or six weeks (croton oil, &c.); repeated during last week.

March the 11th.—Present state; countenance not anxious; walks about the ward. Lying down she does not raise the knees. Abdomen greatly distended, tense, tympanitic everywhere except region of left colon, and it is there dull. Marks of coil from small intestines, very distinct on surface; around them can be traced the colon, much distended. Tenderness generally slight, but considerable on deep pressure in left lumbar region. Much gurgling heard. Pain constant, but not severe except at times, and requiring frequent changes of posture; greatest in left iliac region.

The finger, introduced "per rectum," passes with difficulty from enormous distention of parts within abdomen. The gut is wide and flattened. Tube passes only six or seven inches. Injection of one pint returns immediately, more will not pass. Bladder very low in vagina; catheter passes perpendicularly into the bladder. Urine is scanty and high coloured. The fœtus is felt 'in utero' the womb itself is moveable.

She vomits every hour, or hour and half, some dark brown matter, which has an unpleasant smell, but is not stercoraceous. Stomach retains fluids about an hour. Tongue white, coated. Pulse 130, weak.

Ordered: half-a-grain of powdered opium every six hours, brandy and strong beef-tea.

On the 12th.—Vomiting diminished; has slept much better; has retained fluids. No alteration in physical signs.

March 13th.—Morning, weaker; pulse 140; vomiting in the night has now ceased. In the evening, there was no alteration, and I decided on opening the left colon.

10 P.M.—The operation was performed as follows, in the presence of Mr. Erichsen, Dr. Priestley, Dr. Randall, and others.

Placing the woman on her right side, I made an incision through the integuments in the left lumbar region, two fingers breadth above the crest of the ilium, behind its middle, midway between it and the last rib, commencing about six inches from the vertebral spines, and coming to within two inches and a-half of them; then carefully dissected in the same line through the muscles and fascia, when the colon appeared crossing the centre of the wound. I attached it to the external borders of the wound by three stitches, and opened it with the bistoury sufficiently to admit my forefinger. Fæcal matter issued in abundance.

On the 14th., 9 A.M.—About ten pints of semi-solid fæces have passed during the night. She is weak, but feels much relieved; has taken three eggs, beaten up with brandy. Pulse 136; no vomiting. Evening, tongue dry. Pulse 148. Fluid fæces pass in considerable quantity.

On the 15th., 9 A.M.—Miscarriage took place in the night; the fœtus and membranes expelled entire. She is very weak; no vomiting; takes stimulants only. Gradually sank and died at half-past two P.M.

On the 16th., 2 P.M.—*Post-mortem examination.*—On the abdomen, marks of general peritonitis were seen; intestines distended with flatus; very little fæcal matter. On drawing aside the small intestines, a portion of the colon forming the sigmoïd flexure was seen to be drawn across to the right side of the spinal column, and to be confined there by two or three bands of lymph (apparently recent) attaching it to the mesentery. The bowel at this point was evidently constricted, and just above it a little fluid matter was seen oozing through a minute aperture. On removing the colon from the body, and laying it open down to the seat of constriction, a number nine gum catheter was passed through the aperture, and appeared to fill it. Immediately above this, was an ulcerated opening in the bowel, corresponding with that from which the fæcal matter had been seen to escape. Above this, the colon had a natural aspect up to the opening formed by the operation, which was situated about twelve inches above the stricture; the wound was well placed behind the peritoneum. The strictured part itself, when divided, formed a thick, cord-like prominence, narrowing the bowel transversely and equally all round. It might be comprehended within half-an-inch of the gut, above and below which

the calibre was almost natural. There was no sign of malignant disease in or near it. Mr. H. THOMPSON, *5th of April*, 1859.

---

23. *Stricture of the Pylorus, resulting from the destructive action of Burnet's Disinfecting Fluid.*

The subject of this disease, a woman, æt. 40, accidentally swallowed about half a wine-glass full of Burnet's Fluid, a quantity containing about one hundred grains of chloride of zinc. She was immediately seized with pain at the stomach and vomiting, which she encouraged by drinking warm water. The vomiting continued for a day or two at intervals, and then ceased, so that she had, to appearance, entirely regained her usual health.

Three or four weeks afterwards, pain at the stomach and occasional vomiting returned, and at length became so urgent, that she entered into the St. Mary's Hospital under the care of Dr. Markham, about seven or eight weeks after the date of the swallowing of the poison. She was now very reduced and feeble; all kinds of food were rejected shortly after being taken, and generally mixed with a very acid secretion. Treatment was of no avail in arresting the vomiting and she sank about four weeks after her admission into the Hospital.

The diagnosis made during her life was, that some of the Burnet's Fluid, notwithstanding the vomiting, had been retained in the stomach, and had, somewhere at the pyloric end, produced sloughing, ulceration, and at length contraction of the part. This view was fully confirmed by the *post-mortem examination*. In the pyloric portion of the stomach, about one inch and a-half above the pyloric valve, the stomach was so constricted as only to permit the passage of a smallish bougie. The constriction clearly resulted from the formation of a cicatrix. A dense white hard band, about two lines broad, running along the lower border of the pylorus from the seat of stricture down to the valve, also evidenced the remains of an ulceration.

Dr. Markham believed that there was no exactly similar case on record, of injury resulting from the action of this poison.

Dr. MARKHAM, *5th of April*, 1859.

---

24. *Ulceration of the Œsophagus near its lower extremity, completely preventing the passage of food.*

The patient in this case was a gentleman, æt. 56, of short stature, but of strong frame and muscular, and of swarthy complexion. He resided in a healthy part of Surrey, but, being much engaged in commercial undertakings in various parts of England, led an active and harassing life. He was first seen by Dr. Baly in consultation with Mr. Hewer of Chobham, on the 17th of September, 1858. He then presented a somewhat anxious countenance with apparently commencing pallor, and he complained of a difficulty in retaining solid food, which, after passing, as it seemed to him, down to the level of the lower end of the sternum, was stopped there; uneasiness resulted, and, at length, the necessity to reject all that had been swallowed. This was not, as yet, a constant occurrence. Sometimes he was able to take and retain a full meal. Sometimes a portion of the food passed freely into the stomach before the obstruction occurred. At other times no part of the meal could be retained. Liquids passed without difficulty. There was no pain, and no other symptom elucidating further the nature of the case. All ordinary symptoms of dyspepsia, as flatulence, heart-burn, and acid secretions were absent.

The *history* of the affection was simply this:—A month previously, while at dinner, he felt that the solid food he had swallowed lodged opposite the lower part of the chest, and he was obliged to leave the table to reject it. After the lapse of a week the same thing happened again; and since then it had been repeated with increasing frequency. The food always returned unaltered by digestion, and rarely mixed with matters derived from the stomach.

The opinion formed with regard to the case, was that some disease, probably of malignant character, existed at the cardiac orifice of the stomach; but no fact in the family history distinctly pointed to carcinoma.

The patient was not seen again by Dr. Baly uutil the 30th of November. In the interval various opiate and other sedative remedies had been employed without any good effect. The difficulty of retaining food had gradually increased. Nothing solid had

been retained since the end of October; and now no liquid could be taken except a little wine and water in teaspoonfuls. It had, consequently, become necessary to administer enemata of beef-tea in order to support life. On the 30th of November, when Sir Henry Holland and Mr. Partridge were also called into consultation, the patient was thinner and paler than before, but in his movements presented no appearance of weakness. When he was asked to swallow a tablespoonful of beef-tea, he did so; but after the lapse of about a minute, he said he could not keep it down, and it was immediately regurgitated, mixed with a little mucus or salvia. At his own suggestion he then took a little sherry wine and water; but with the same result. An accurate examination of his abdomen and chest, both before and behind, detected no evidence of the existence of an aneurysm or other tumour. It was proposed, that the œsophagus should be cautiously explored by means of an œsophagus bougie, and he agreed to the proposal at the time; subsequently he declined to submit to the operation.

After this period, the symptoms immediately referrible to the local affection underwent no important change. Liquids wholly ceased to pass into the stomach. Small quantities of milk were sometimes retained for as long as two hours, but were ultimately rejected uncoagulated and mixed with mucus, which, though generally colourless, was occasionally tinged with blood. For a period of ten days the bladder became paralyzed, so that it was necessary to draw off the urine night and morning; this state, however, had passed off a fortnight before death, which occurred on the 26th of January. During the last three months of his life he had received no solid food into his stomach, and during the last two months no liquid food.

Post-mortem examination.—The œsophagus and stomach which were sent to London, presented the following appearances. The stomach was free from disease. The œsophagus, also, was healthy, except at its lower part, where there was a zone of ulceration two inches in breadth, which in the whole circumference of the tube had destroyed the mucous and the muscular coat. This ulcerated part was not narrower than the rest of the tube (after it had been some weeks in spirit it measured nearly two inches across when laid open). The surface of the ulcer was very irregular, with

large granulations or small fungoïd prominences and ragged excavations. Its edges were formed by thin undermined portions of mucous membrane. At one part the coats were entirely perforated, and the tube of the œsophagus communicated with an ulcerated cavity (capable in the recent state of containing nearly an ounce of fluid), which lay in the tissue of the posterior mediastinum in contact with the right lung. This lung was here adherent to the neighbouring parts, but its texture was healthy. There was no obvious deposit of new tissue in the coats of the œsophagus at or contiguous to the seat of ulceration. Two inches of the tube, in a healthy state, intervened between the disease and the cardiac orifice of the stomach. Only one enlarged indurated absorbent gland of the size of a horse-bean lay on the outside of the œsophagus at its ulcerated part.

No other disease was found elsewhere in the body. The gall-bladder was distended with nearly six ounces of rather thick bile. The emaciation of the body was not extreme.

Dr. W. Baly, *15th of February*, 1859.

Report on the above case.—The surface of the ulcer was ragged and sloughy-looking, and the subjacent tissues presented little trace of thickening, induration, or adventitious deposit; under the microscope, however, they were found to present all the elements characteristic of epithelial cancer—namely, epithelial scales of various sizes and shapes, thick-walled ovum-like cells and laminated epithelial capsules. A neighbouring lymphatic gland was somewhat enlarged, its capsule indurated, and its substance reduced to a kind of flaky pulp. This pulp consisted of an accumulation of similar elements to those found in connection with the ulcer itself.

There can be no doubt, therefore, that the disease in the œsophagus was really epithelial cancer; but, that the greater part of the adventitious growth had been removed by ulceration and sloughing.

J. S. Bristowe, M.D.
W. O. Markham, M.D., *5th of April*, 1859.

25. *Wounds of the Stomach, Jejunum, and Abdominal Aorta, from a Pistol-shot.*

A German gentleman, æt. 22, on the 24th of March, at a quarter past six, shortly after he had dined, committed suicide in a shooting-gallery, by putting a duelling pistol to his abdomen. He had inserted the muzzle of the weapon between his trousers and waistcoat, so that the shirt alone intervened between it and the skin. Scarcely any blood was lost from the wound. In a few minutes he was seen by a surgeon, who found him in a state of great collapse, for which he gave him a little brandy. He was then conveyed in a cab, a distance of half-a-mile, to the Middlesex Hospital. On his arrival, the pulse was scarcely perceptible, the heart acted feebly, the skin was cold and blanched, he tossed himself restlessly, preferred lying on his belly, and breathed with deep sighs, interrupted by hiccough and retching: on being questioned, he said that it was with his right hand he had fired; he was impatient of being offered any assistance. He died at half-past seven, being an hour and a-quarter from the time of his inflicting the wound.

Post-mortem examination, eighteen hours after death.—The wound in the abdominal parietes was two inches to the left side, and half-an-inch above the level of, the umbilicus. The ball had passed through the linea transversalis of the rectus muscle at that part. Blood, partly in clot and partly fluid, to the amount of twenty-six ounces, was found in the peritoneal cavity; the greater part collected in a space formed by itself between the small intestines and the contracted descending colon; the remainder, in small quantity, was lying under the liver, and in larger quantity within the pelvis. Having drawn down the transverse colon and stomach which were in the epigastrium, for inspection, it was unexpectedly found, that, notwithstanding the low situation of the external wound, the ball had perforated the stomach, and that at a point not distant from its centre; the orifice through the anterior wall was midway between the cardiac and pyloric orifices, and two inches and a-quarter above the greater curvature; the opening through the posterior wall was a little further from the greater curvature. The stomach was of average dimensions; it was

nearly full of partly digested food, most of which was semi-fluid. The orifices of both wounds, when looked on from without, were so much alike that it could not have been said which was that of entrance or of exit: they were irregularly circular, and the edges, though slightly jagged and shreddy, were, on the whole, defined. But this description applied only to the perforation of the serous and muscular coats; on the inside, the mucous coat was seen to have been detached all round the orifice, and the edges were torn and split into shreds, many of the rents radiating from the opening being nearly an inch in length. The appearance of the mucous membrane was so much the same in both wounds, that no difference could be observed between them. None of the contents of the stomach had escaped into the abdominal cavity. Continuing to trace the course of the ball, it was found to have perforated the root of the meso-colon; to have wounded the jejunum, four inches from its commencement on the left side; and then to have pierced the posterior parietal peritoneum over the spine. Between the peritoneum and the spine and abdominal muscles, a large quantity of blood had been extravasated; that which lay upon the bodies of the vertebræ was coagulated into a firm mass, like the compact fibrin of an old aneurysmal sac, and was an inch and a-half in thickness. When part of that was cleared away a large wound in the aorta was brought into view. The situation of the wound was two-thirds of an inch above the level of the inferior mesenteric artery; its length was equal to one-third of the circumference of the aorta; the direction was transverse; two-thirds of it were at the back, and one-third on the left side of the vessel; the cut edges were a quarter-of-an-inch apart; at the posterior end, the slit divided into two diverging fissures which included a loose angular portion between them. After some search, the bullet was found lodged in the body of the fourth lumbar vertebra; the difficulty of finding it having been caused by the fibres of the anterior longitudinal ligament, between which it had forced itself, having closed over the point of entrance and so concealed it.

Mr. Shaw confined his remarks on this case to two points. 1. It gave rise to some surprise, in making the post-mortem examination, that the pistol-ball, having entered the abdominal

cavity so low down as nearly on a level with the umbilicus, should have passed through the stomach, a little below its middle. The only way in which the fact can be accounted for, is by supposing that, before the patient put the weapon to his belly, he had doubled his body or curled himself up; and it is not improbable also, that when about to draw the trigger, he took a deep inspiration, which act would assist in propelling the stomach, enlarged from containing food, towards the lower part of the abdomen; so as to bring it into the course of the ball. 2. it was remarkable that, having a wound of the aorta of such large size as the specimen exhibited, the patient should have borne the motion of being conveyed from the Shooting-gallery to the Hospital, and survived for an hour and a-quarter. The explanation appeared to be, that from the wound having been chiefly at the back part of the vessel, opposite the body of the vertebra the blood would escape with difficulty from between the artery and the bone; again, owing to the aorta being covered over by the peritoneum, and the opening into that membrane made by the bullet being small, and situated obliquely in reference to the wound in the aorta, the blood, as it escaped, would be confined around the artery; it would thus be allowed to coagulate in front and on the sides of the vessel; by that means the thick, nearly solid mass of clot found on dissection would be formed, and that clot would act as a compress in closing the aorta, or at least, in retarding the flow of the blood from the wound.

Mr. SHAW, 19*th of April*, 1859.

---

26. *A Specimen of Inguinal Hernia of the right side; the Sac containing the Appendix Vermiformis.*

In this case, the appendix had become adherent to the neck of the sac by its base, so as nearly to obliterate the opening into the abdomen. The extremity of the appendix lay in the fundus of the sac. No other intestine or omentum was present in the sac.

This specimen was shown to illustrate the conditions which may prevent the descent of intestine into a hernial sac, and s. produce a radical cure. Mr. JOHN WOOD, 3*rd of May*, 1859.

---

27. *Case of Invagination of the Large Intestine in an Infant.*

A female child, seven months old, had had no ailment since birth. It was suckled by its mother, but also fed with bread and treacle and occasionally coffee. The bowels had been habitually regular, having needed no medicine for three months.

The child, when first seen by its medical attendant, Mr. Albert Buchanan, was in a state of collapse: pale, its hands and feet cold; breathing noisy; pulse scarcely perceptible; pupils small. It had been ill forty-eight hours; at first it seemed in pain, and its mother gave it a dose of castor oil, not that she had noticed its bowels to be confined, but that she thought it would do it good. This did not operate at once, and next day the child was still in pain, and had a very small motion of yellowish curdy matter and slime.

On being questioned, the mother said she did notice a little blood come from the anus when the child was first taken ill, before the castor oil was given; but she had seen no blood afterwards. Nothing had attracted her attention to the belly as the special seat of disease; and on the evening of the second day, she gave the child a teething powder, thinking it would soon be well. Next morning, the child was much about the same; but at two o'clock P.M. it vomited for the first time, and then fell into the condition in which she was seen. The vomited matters were only food and clear water; no stool this day. Another teething powder had been given for the sickness.

Of the intestinal obstruction surmised from this history, Mr. Buchanan could find scarcely any proof on physical examination. There was no swelling of the abdomen, nor any tympanites; no tumour could be felt in the left flank or elsewhere; and in the existing general condition of the patient no evidence of tenderness was elicited. No examination "per anum" was made.

In spite of attempts to revive it, the child died five hours and a-half after it was first seen, without presenting any further symptom.

On *post-mortem examination* the body was found well nourished; the thoracic viscera perfectly sound. A very trifling redness, but no lymph or fluid at all was observed at the junction of the coils

of the small intestine; this injection was found to increase towards the pelvis.

The stomach contained a little dirty-coloured mucus; the liver, spleen, and kidneys, were quite healthy.

On removing the intestine, the intus-susception was found situated in the intestine occupying the pelvis. The ileum and its attached mesentery appeared to end abruptly in the colon about the sigmoïd flexure, which was distended to a diameter of an inch and a-quarter, and was thrown into folds, one of which was so deep as itself to form a secondary intus-susception. The extremity of the volvulus reached to within half-an-inch of the anus. The sheath was readily extended to twice the length of the contained intestine, and on cutting it open, the invaginated portion was seen of a dark venous-red colour; and at its lower spot, where it approached the anus, was a hard thickened patch, whose mucous surface was formed into a soft yellow slough.

The entering tube of intestine was pulled out without much difficulty; the adjacent serous surfaces were injected, and slightly adherent by recent lymph. The small intestine did not pass into the ileo-cæcal valve, nor was it invested in any manner; but along with the end of the mesentery, the appendix and a part of the cæcum, it lay unchanged within the receiving tube of large intestine. The portion of the volvulus which had descended lowest, proved to be formed by the cæcum, about half-an-inch from the appendix, and here was the thickening and sloughing before described.

The very few symptoms present in this case, and its early termination, are points of interest. The anatomical lesion in children being almost certainly in the colon, and possibly within reach, Mr. Buchanan dwelt particularly upon the importance of an examination 'per anum' in cases of suspected intus-susception, as an aid to diagnosis, if not with a view to the means of cure.

Dr. G. Buchanan for Mr. A. Buchanan, *3rd of May*, 1859.

---

28. *The Stomach of an Infant the posterior wall of which was extensively destroyed by the Gastric Juice.*

This specimen was taken from an infant aged five months. The

mother was a charwoman, whose duties compelled her to be absent from her child during the day, when it was fed with pap, but was allowed to suck at her breast all night. It had constant green-stool diarrhœa, and was always fretful and crying. One morning it was found dead in bed.

On *post-mortem examination* of the body, the coats of the stomach were found to be thin, and there was a large ragged hole through the posterior wall of the greater end.

The specimen was exhibited to show the extreme degree of injury to the stomach by the gastric juice, which seems to be secreted as a reflex action during the excitation of the nerves of taste, which necessarily occurs during the act of sucking, but becomes excessive when an infant is permitted to suck for a long time without obtaing the food for which its system craves. Under these circumstances, the gastric juice is poured out in great abundance, and causes various degrees of injury to the coats of the stomach. The green stool diarrhœa of infants is the evidence of this process being in operation.

At page 185 of the 8th vol. of the Society's "Transactions," is described another case of destruction of the posterior wall of the stomach by the gastric juice; it is there recorded as an example of post-mortem solution—that being the usual explanation of the phenomenon, though most likely not the correct one—and it is recorded of that infant, that she never had diarrhœa, which was the parent's report at the time; but upon subsequent inquiry I have learnt that she had frequent green stools, though she was never ill enough to require medical treatment, and therefore in the parent's estimation she never had diarrhœa.

Mr. Ballard, 17*th of May*, 1859.

II.—LIVER AND ITS APPENDAGES.

29. *Primary Encephaloïd Disease of the Liver.*

A. B., æt. 53, admitted to the Infirmary of Marylebone on the 5th of November, 1858, and died on the 7th of January, 1859. She had long been a surgical nurse, and appeared to have poor health at all times. Since death, it was discovered that she

had been a confirmed opium eater for twenty years, taking latterly as much as a drachm of the crude drug daily.

At the *post-mortem* examination, the liver was found to be greatly enlarged, weighing six pounds, encroaching considerably on the right thoracic cavity, extending downwards to the right iliac fossa, and compressing the stomach as it occupied the left side.

Superficially, the entire surface was seen nodulated with whitish masses about the size of pearl-barley, very little liver-substance proper appearing between them. Section of the liver showed that similar nodules were disseminated throughout the entire organ. They were soft and creamy in consistence, and under the microscope, found to be made up of small nuclei, with strongly-marked contour, unaffected by acetic acid, and containing two or three small nucleoli. There were no masses larger than the size of a pea.

The mesenteric and bronchial glands were also largely infiltrated with a similar material. The disease evidently originated in the liver, and no other organ, the glands excepted, was thus affected.

Mr. H. Thompson, 1*st of February*, 1859.

---

30. *Association of Cystic Disease of the Liver and Kidneys.*

In the 7th vol. of the Society's "Transactions," I have recorded a case, in which a well marked cystic condition of the liver was associated with an equally well marked cystic state of the kidneys; and for reasons there stated, I was led at the time to assume that this association, remarkable as it was, was merely an accidental one. On a subsequent occasion, however, Dr. Wilks exhibited a similar series of specimens; and thus, considering the great rarity of cystic disease in the liver, and the fact that in two cases successively exhibited, such a condition of the hepatic organ was associated with a similar and very advanced affection of the kidneys, it was rendered probable that the view I had previously expressed was erroneous. The accompanying case furnishes a further example of this association; and confirms, therefore, the idea of there being a necessary connection between the two affections. It

fails, however, to indicate the cause of this connection; and I may add, that on this point I am at the present time quite unable to throw any light.

M. R., a married woman, with two children, was admitted on the 17th of February, 1859. She had had severe cough for five years, but no hæmoptysis; and had complained for some time of short breath, palpitation, emaciation, œdema of legs, dyspepsia, and constipation.

On admission, she seemed in the last stage of phthisis; her face was livid, her breath very short, her expectoration profuse and purulent. She was in a moribund condition, and died on the 19th.

Post-mortem examination.—Of ordinary stature, somewhat emaciated. The lower extremities were œdematous. The left foot had been amputated, and a healthy stump remained.

The pericardium and heart were healthy. A circumscribed empyema occupied the lower part of each pleura; and that on the right side, which was the larger, and contained about a pint of pus, communicated with the bronchial tubes. There was advanced emphysema of the anterior part of the left lung, and much collapse of the lower lobes of both, but otherwise they were tolerably healthy. The bronchial tubes were much congested, and loaded with muco-purulent fluid. Some of the bronchial glands were converted into large cretaceous masses. Several of the branches of the right division of the pulmonary artery were blocked up by adherent fibrinous clots. Larynx and trachea healthy.

Peritoneum healthy. The liver was of usual size, and for the most part healthy; but on close examination, was found to contain vast numbers of small cysts from the size of a tare downwards. The larger ones were filled with serous fluid, the smaller frequently with a dark reddish-brown inspissated material. Under the microscope, the liver was found to be somewhat fatty. The larger cysts were observed to be lined by a distinct layer of small, flat, coherent cells. The inspissated contents of the smaller ones consisted of a reddish-brown waxy material, which was amorphous, but presented irregular lines and other indications of

either fracture or involved cells. The cyst walls were made up of fibrous tissue, differing apparently in no respect from that of serous membrane.

The kidneys were large, and together weighed seventeen ounces and three-quarters. They were very thickly studded with cysts from the size of a pigeon's egg downwards. The cysts were thin walled, and generally contained serous fluid, but sometimes milky and sometimes inspissated contents. The kidney structure between them appeared healthy, and presented under the microscope a healthy condition. In the thin party-walls, between adjoining cysts, especially after the addition of acetic acid, remains of tubules loaded with granular matter and oily epithelium were observed. The remaining organs were all healthy.

Dr. Bristowe, *2nd of March*, 1859.

---

31. *Case of total Atrophy of the Gall-bladder.*

Here the only remains of the gall-bladder was a nodular mass of the size of a large pea. It contained a slight cavity, which communicated with the canal of the hepatic duct by a short cystic duct, and apparently formed part of the neck of the original gall-bladder.

The superjacent groove on the under surface of the liver was shallower than normal, and marked by an evident cicatrix which encroached somewhat on the lobulus quadratus, and contracted its dimensions. The common and proper hepatic ducts were both dilated to double the normal size, and were filled with viscid bile. There was no adhesion to the upper part of the duodenum. The cause of the obliteration was probably inflammatory, and originated in an abscess either in the gall-bladder itself, or on the neighbouring surface of the liver, possibly also from the irritation of gall-stones, though no vestige of these were seen. The pus might have found its way down the cystic and common ducts, which were quite pervious up to the nodular remains of the gall-bladder.

Mr. J. Wood, *15th of March*, 1859.

---

32. *Gall-stone impacted in the Common Duct of the Liver; Rupture of the Gall-bladder, and death from Hæmorrhage.*

A healthy man, æt. 22, was seized on the 1st of February, 1859, with severe spasmodic pain in the right hypochrondriac region; the pain was increased by pressure over the gall-bladder, and vomiting occurred. Mr. Conolly of Aldersgate Street, who was called to see him, ordered leeches to the side, and gave opium. Under this treatment, the patient almost recovered, although the pain returned at intervals. On the 5th of February he was slightly jaundiced, the fæces, which had been gradually losing colour, were now almost white — and a throbbing sensation in the right side of the abdomen was complained of. On the 7th of February, the pulse, which had been previously at 60, had risen to 120 in the minute. From this date to the 12th of February, his condition was daily becoming worse; the pain had lost its spasmodic character, but was more continuous and diffused. He was greatly exhausted, sweated profusely, and had latterly a constant desire to pass water, which was attended with a burning sensation. On the following morning (February 13th) he felt much better and the pain had almost disappeared; urine was passed without inconvenience; pulse under 100; but the right side of the abdomen was now observed to be dull on percussion, and the muscles of the part were contracted. In the afternoon a great change again occurred, the pulse was rapid and thread-like, the surface cold and clammy, and agonizing pains throughout the abdomen were complained of. At length, about ten hours from the change for the worse, he died.

The treatment may be briefly stated, as consisting chiefly of opium, stimulants and purgatives.

During the last eight or nine days of the patient's life, the fæces were carefully examined for gall-stones, but none were discovered. It is worth observing, that he had been subject to sudden attacks of abdominal pain and constipation since he had a fever a few years since.

Post-mortem examination, fourteen hours after death.—Body, that of a well-formed man, and not much wasted. The whole

right side of the abdomen very dull on percussion. Corresponding with this, the abdominal cavity was found stuffed with coagulated blood, which had displaced the viscera to some extent. The pelvic cavity was also full of coagula, but the left side of the abdomen was quite free from them. The quantity of blood effused appeared to be not less than two quarts.

The gall-bladder was found ruptured, and a considerable part of it, as well as a portion of the liver, to which it was adherent, had disappeared by sloughing. The gall-bladder had also been adherent to the stomach. The exposed liver-substance and portions of the gall-bladder were black and rugged-looking; no particular vessel could be fixed upon as the source of the hæmorrhage.

The liver in general was in a healthy condition. In the common bile duct, at an inch from its termination, a gall-stone, the size of a large pea, was discovered. The duct was dilated sufficiently to admit a cylinder, five-eighths of an inch in diameter to the point mentioned but beyond this only a probe could be passed.

In tracing the intestines, a recent intus-susception of the ileum was found, but there were no traces of recently effused fibrin.

Dr. Leared, *15th of March*, 1859.

---

33. *Colloïd Disease of the Liver.*

This was an old specimen from Guy's Museum, but brought to the Society to be exhibited because an opinion had been expressed as to the non-occurrence of colloïd in this organ. It was extremely rare, since he had never before met with a case. Rokitansky had only seen one, and Mr. Sibley could find no case on record.

Dr. Wilks, *5th of April*, 1859.

---

34. *Cancerous Tubercle of the Liver and Stomach; Gall-bladder filled with pus and a Calculus; Ascites; Enlarged Liver.*

J. S. T., æt. 57, an architect, complained of lumps in the epigastrium six months ago; these slowly enlarged, and formed a prominent abdominal tumour by the middle of February, which extended from the right to the left hypochondrium. As it continued to increase, it spread downwards to the lower third of the umbilical region, with a projecting nodulation distinctly felt at the lower margin of the right iliac region. In the latter situation, and indeed in other parts, distinct depressions were felt on the surface of the tumour, which were occupied by the fluid of ascites, which became co-existent during the last three or four months of life. Percussion was invariably dull in the different regions named; but below the tumour, a tympanitic sound was elicited, showing the bowels to be behind it. He had a little pain three or four days before death in the right hypochondrium; but for some twelve weeks or more, ingestion of food caused a prominence of the abdomen, with a feeling as if he was "puffed up, ready to burst." There was no cachexia, nor family history of cancer, nor was there any vomiting or special gastric symptoms; jaundice set in only four days before death, when the urine became loaded with bile. Previous to that it was febrile in character, that is to say, it was of a brick-red colour, with a copious lateritious sediment, sp. gr. 1023, albuminous, and scanty in quantity. This character is known to be common in serious organic affections of the liver, but especially in cancer, and the rapidity of its growth mainly lead to the diagnosis of its being the encephaloïd form of the disease, although there were no special hepatic symptoms beyond the dulness and febrile urine. The feet began to swell on the 27th of February; the ascites slowly increased; the right leg and thigh became œdematous; debility and prostration slowly gained upon him; the tongue and mouth were constantly parched; he had occasional spurious diarrhœa; jaundice set in, and he died on the 12th of April.

Post-mortem examination twenty-four hours after death, assisted by Mr. Henry A. Dodd and Dr. Logan.

The body, face, and limbs were in the most extreme state of emaciation; the right leg and thigh were swelled and œdematous: the left leg measured eleven inches and a-half, whilst the right leg was fifteen inches and a-quarter in circumference; the left thigh measured fourteen inches and a-half, whilst the right was eighteen inches. The circumference of the body, around the abdomen, was thirty-eight inches.

The abdomen contained four pints of an olive-coloured neutral fluid, sp. gr. 1017; it was loaded with bile, and contained a moderate quantity of albumen. The entire upper and anterior part of this cavity was occupied by the liver, so much enlarged as to compress and displace the stomach to the left of the spine, in front of the spleen and left kidney. The colon was pushed downwards, but the lower border of the liver was anterior to it, as well as all the small intestines. The liver weighed sixteen pounds less two ounces; its great bulk being formed by the right lobe, which possessed a diameter from behind forwards of fourteen inches; whilst the diameter of the entire organ, from right to left, was seventeen inches. All the lobes were equally enlarged, and contained on their surface and in their substance, numerous buff-coloured encephaloïd cancerous masses, varying in size from a Barcelona-nut to a large orange, assuming either a circular or an oval form, and apparently coalescing with one another in the substance of the organ, but each tubercle was distinct and separated from its neighbour by a fibro-cellular septum. On section, these masses exhibited a brain-like substance, with a yellow radiating fibrous stroma in their centre, yielding a milky juice, which was composed of numerous nuclei and indistinct cell-walls; but no nest or mother-cells were clearly discernible. The cells of the liver were normal, but contained numerous albuminous globules. The anterior border of the right lobe was irregularly nodulated in its extension downwards towards the right iliac region from these growths. This viscus was adherent slightly to the diaphragm and neighbouring viscera; its largest circumference was thirty-four inches. The quantity of albumen present in the liver was enormous, but not a trace of sugar could be detected. The gall-bladder was shrivelled up, its coats much thickened, and con-

tained a drachm of thick creamy fluid, of a fawn-colour, which consisted principally of pus cells, fat granules, in cells and free, a few epithelial scales, and an oval reddish-brown calculus, the size of a marble, weighing seventeen grains. The cystic duct was pervious as far as the gall-bladder, where it ended in a cæcal pouch. The ductus communis choledochus at its commencement, external to the duodenum, was surrounded by a mass of indurated glands, but it was not impervious. The stomach at its lesser curvature, was affected with a series of enlarged masses of encephaloïd cancer, in a state of congestion and ulceration, which projected inwardly; they did not encroach upon the pyloric or cardiac orifices of the organ. Externally, the veins of the lesser curvature, around the induration, were in a varicosed condition, the diameter of the largest measuring over two lines. The spleen was small but normal. The kidneys looked fatty, with a bilious tinge, but were healthy; as also were the supra-renal capsules. The large bowel was distended with gas, and the bladder was filled with urine. Pancreas healthy. The right pleura contained a pint of red-tinged fluid, sp. gr. 1024, which formed a jelly in a few hours; it contained much gelatine, but scarcely any albumen; under the microscope, blood corpuscles were seen with serrated edges, and well-defined crystals of phosphate of ammonia and magnesia, in the form of triangular prisms, with obliquely truncated extremities. The lungs were healthy, slightly emphysematous at their apices, with a preponderance of carbonaceous deposit. The heart was small but healthy; all its cavities were filled with yellow transparent gelatinous coagula, extending into the aorta and pulmonary artery. Deposits of atheroma existed in the thoracic aorta, but were not yet ulcerated. A few drachms of serum were present in the pericardium, tinged with bile. The tongue was large, dry, and fissured, and much congested posteriorly with all the papillæ enlarged, and very prominent. The epiglottis was widened from side to side, and measured above an inch.

It is extremely probable that the disease had been going on in the liver long before the tumours became prominent; and that the disease in the stomach was secondary to that in the liver, and of

very recent occurrence, because there was no vomiting nor other evidence of gastric irritation. It must be admitted, that when the cancer became active, it ran a very rapid course.

A case very similar to the present was brought before the Society at this period of last year (vol. IX., p. 234), by Dr. Van der Byl, in which the same form of scattered cancerous growths were present in the liver, weighing twelve pounds. The liver has been known to reach a weight of twenty pounds; but the present is, I believe, the largest (sixteen pounds), that has been brought before the Society.

This form of cancer of the liver, formerly known as "Farre's, Tubercle of the Liver," was well described by Dr. Farre in 1812, under the varieties of *tubera diffusa* and *tubera circumscripta;* the essential difference between the two mainly depending upon their relative consistence. I would urge the propriety of resuming such a distinctive appellation, with the addition of the nature of the tubercle, to distinguish it from scrofula; thus—*Farre's Cancerous Tubercle of the Liver.*

Dr. GIBB, 19*th of April*, 1859.

---

35. *Tubercles in the Liver, in connection with the question of so-called "Dilatation of the Gall-ducts," occurring in some cases of general Tuberculosis.*

Rokitansky, in his "Pathological Anatomy," after speaking of the true tuberculous *vomica* of the Liver, which he describes as being very rare, says, that it "requires to be the more carefully distinguished from morbid dilatation of the gall-ducts, as the the latter not only occurs frequently, or almost invariably in combination with hepatic tubercle, but is not infrequently co-existent with tubercular disease of other organs. In this case, small cavities of the size of a millet seed or a pea, filled with viscid muco-bilious, dirty green matter, with flaccid parietes, are found scattered through the liver, which, on close examination, are found not to be tubercular, but to be dilatations of capillary gall-ducts. * * * The conditions of their origin, and their connection with the constitutional disease, have not been as yet

ascertained; but we are warranted, by numerous observations, in stating, that they invariably indicate a high degree of the constitutional affection."

The specimens exhibited were portions of the liver of a youth, J. C. æt. 17, who was a patient at the University College Hospital, at first seen by Dr. Hare, and then admitted under Dr. Garrod. On admission he was evidently suffering from severe peritonitis, which dated from two days previously (26th of June, 1858); the acute character of the attack subsequently diminished, but the patient never gained much strength; on the other hand, he was emaciated: lung disease and pleurisy of low character, with effusion supervened, and he died on the 1st of September following.

The lungs were highly tuberculous, and the pleuræ were studded thickly with tubercles, as was also the peritoneum. The brain, spleen, pancreas, and one kidney were free from the disease; and the right kidney contained only three small tubercles.

The liver presented a condition, in connection with which the extract from Rokitansky's work, at the commencement of this paper, is made. Its peritoneal covering, as well as some false membranes attached to it, were studded with tubercles; and on section of the organ itself, various bodies which presented appearances exactly resembling those described in the paragraph quoted, were scattered throughout its substance: they varied in size from a millet seed to a small pea; at the outer part they were dense and somewhat resisting, but on section were found to contain a pultaceous, somewhat granular, and yellowish (bile-tinged) matter, which in some instances was semi-fluid, in others thicker; but it was generally thinner towards the centre than elsewhere: owing to the greater density of the outer portion of these bodies than of the surrounding liver-substance, they could be in many instances separated from it.

So well defined in some cases were these bodies, and so different in consistence were their outer portion from the central more fluid part, that they certainly presented very much the appearance of cysts, such as might be formed by the dilatation of gall-ducts; but, on careful examination, not only was there not found any instance in which a gall-duct *opened* into one of these bodies, but

they did not appear to be in any way *connected with* the gall-ducts. The "walls," too, of the so-called dilatations, were thicker and less smooth internally than they would have been had they originated from the gall-ducts; and, moreover, gradations in the different specimens presented, might be traced between what were evidently small tubercles, and these larger bodies which presented the cyst-like appearance. Dr. Hare, therefore, while admitting the accuracy of Rokitansky's description of the bodies in question, differed from him in his view of their nature, and considered them to be tubercles softened in the centre, and not dilatations of the gall-ducts.

Dr. Hare, *3rd of May*, 1859.

---

36. *Case of Fatal Obstruction of the Small Intestines by a Gall-stone.*

The patient, a lady, æt. 69, of small stature, and though fat, of delicate frame, consulted Dr. Baly on the 18th of December, 1858, on account of frequent micturition, which had been a source of discomfort for some years, and now seriously disturbed her rest at night. There were no other symptoms of disordered health. Before a plan of treatment was determined on, it seemed desirable that the condition of the urine should be ascertained. It was arranged, therefore, that the patient should be seen again on the 21st of December, and that in the meantine she should take two or three small doses of compound rhubarb pill, her bowels being sluggish, though never obstinately costive.

On the 21st, Dr. Baly was called to her early in the day, and then learned, that on the 19th she had felt uneasy at the epigastrium; that this feeling continued on the 20th, when she had one or two loose and copious, rather exhausting, evacuations from the bowels; that she nevertheless accompanied some members of her family to the theatre in the evening and while there, was seized with severe pain in the abdomen and nausea, so that she was taken home before the performances were concluded; that in the night the pain became intense, and of the character of colic, and was

attended with vomiting; to allay which fomentations were applied and an opiate administered by Mr. H. Nelson, of St. John's Wood.

When seen on the 21st, her countenance was anxious, and she complained of cutting pains in the lower half of the abdomen, which was full and tender on moderate pressure, and the abdominal muscles at the part were tense; her skin was rather hot and dry; her tongue dry down the middle and thinly furred; her pulse 108 and rather feeble as well as small; there was frequent vomiting. The bowels had not acted since the previous day, and no urine had been passed. From the character of the symptoms, and the history of the attack, it was suspected that mechanical obstruction of the intestines of some kind or other had occurred. A hernia was sought for, but none was found; a few leeches, therefore, were ordered to be applied to the painful part of the abdomen, and small doses of mercury and chalk with opium and effervescing saline draughts were prescribed. In the evening, the symptoms not having abated, Mr. Stanley was called into consultation, and he renewed the search for a hernia, but in vain.

During the next two days the pain and tenderness of the abdomen gradually subsided; the pulse fell first to 96 in the minute, and then to 84; the skin became cooler, but the vomiting continued, and no relief from the bowels was obtained, although small doses of sulphate of magnesia were given and purgative enemata and large enemata of water were administered with the aid of a long flexible tube. Afterwards opium was given in full doses. The vomiting gradually became urgent, and the matter vomited more constantly bilious in character. The patient's sense of distress increased, and the abdomen became more full in the umbilical region, although the epigastrium and the lumbar regions remained undistended.

From the 25th, symptoms of exhaustion began to appear. The countenance became more anxious, the eyes sunken, the skin of the extremities cool, the tongue more thickly furred and brown; while the matters vomited assumed a darker colour and more fæcal odour. On the 26th, they were exceedingly offensive, resembling in appearance and smell the fetid liquid stools passed in typhoïd

fever. Death took place on the 27th, six days after the first severe symptoms set in.

The opinion that the case was one of mechanical obstruction of the bowels had been confirmed by the persistence of the symptoms, and the powerlessness of all remedies to alter them in any important degree. Several features of the case, too, led to the inference, that the seat of the obstruction was some part of the small intestines. The features referred to were:—1. The form of the abdomen, which seemed to show that the large intestines were empty. 2. The possibility of injecting large quantities of fluid into the intestines 'per anum.' 3. The absence of all sense of need to relieve the bowels. 4. The greatly diminished secretion of urine, of which none was excreted during the first thirty hours after the commencement of the urgent symptoms, though this is probably only a secondary result of the next feature of the case. 5. The urgency of the vomiting from the very first. 6. The continued severity of the symptoms and rapidly produced exhaustion.

Post-mortem examination of the body was made by Mr. Stanley, Dr. Baly and Mr. Nelson also being present. Slight marks of peritoneal inflammation, vascular injection, and delicate shreds of fibrinous exudation, were found about the small intestines in the umbilical region. Near the junction of the upper with the middle third of the small intestines, their diameter suddenly became contracted, and at this point a foreign body was felt occupying the canal. An incision liberated a large gall-stone; this, as it were, plugged the tube which had become somewhat dilated above, while below the obstruction it had contracted. The gall-stone was barrel-shaped, that is, cylindrical, wider in the middle than at the ends which were truncated, and presented, each, a smooth facet. The circumference of the concretion at its thickest part measured three inches and three-eighths of an inch; its length one inch. The inner coat of the intestine was healthy. The gall-bladder was united by firm old adhesions to the surrounding parts. It contained a still larger biliary concretion, one end of which had a smooth facet, while the other, the larger end, was somewhat conical and rounded. The concretion was one inch and a-quarter in length. On placing the two to-

gether, it was apparent that a smaller one applied to the lower end of the barrel-shaped concretion found in the intestine, would have formed a complete cast of the interior of an elongated gall-bladder.

Remarks.—From the circumstances under which the examination was made, it was not possible to make a general or minute investigation of the state of the body, and unfortunately it was not ascertained whether the gall-ducts had been dilated, or whether the concretions had passed from the gall-bladder to the intestines through an ulcerated opening in their coats. It is most probable that the latter was the course taken by the concretions, not only from the size of the one which obstructed the intestines, but also from the close adhesions between the gall-bladder and the contiguous parts, and from the fact, that the patient had never been jaundiced. Fifteen months before her death, she had experienced a severe attack of spasmodic pain at the epigastrium accompanied by shivering fits and sickness, and previously she had had at long intervals a few attacks of pain attributed to indigestion, but she never had jaundice.

Dr. Baly, *4th of January*, 1859.

V.—DISEASES, ETC., OF THE GENITO-URINARY ORGANS.

1. *Ovarian Cyst removed sucessfully.*

This cyst was multilocular, but consisted principally of one large cyst, with outgrowths of pseudo-colloïd character from its wall. These outgrowths had been attached to the under surface of the liver. The largest cavity had contained thirty-six pints of fluid.

The cyst was removed by Mr. Spencer Wells in the Samaritan Hospital on the 11th of August, 1858, from a married woman, æt. 38. The peduncle was fixed outside the wound in the ab-

dominal parietes, and the woman was completely restored to robust health.

Mr. Spencer Wells, 19*th of October*, 1858.

---

2. *Specimen of Encephaloïd Cancer of the Kidney.*

This specimen was taken from the body of a lady, æt. 70, who had resided many years in India, and brought up a numerous family, two of whom had died of malignant disease, *viz.*: a daughter, æt. 40, of cancer of the tongue, and a son about the same age, after having suffered amputation of the leg for a malignant growth in it.

She had suffered during the last two years with frequently recurring attacks of hæmaturia. The urine was always pale, of low specific gravity and albuminous, usually clear, but on some occasions containing a large quantity of matter resembling the disharge from a scrofulous abscess which did not yield evidence of cancer, when microscopically examined by Dr. Handfield Jones.

A year before death, a tumour was detected in the left lumbar region which gradually increased, an arterial murmur was so distinctly heard in this, that the late Dr. Bright suggested the bare possibility of the case being one of aneurysm of the renal artery. Latterly the hæmaturia entirely subsided. The other symptoms were dull pain in the tumour, frequent micturition, and burning pain referred to the urethra. Her strength gradually failed, and she sank under the effects of the copious effusions into the pleura.

Post-mortem examination.—The cavity of the peritoneum contained a small quantity of fluid; on the left side the peritoneal surface was studded with masses of encephaloïd cancer, and the descending meso-colon was so occupied with the cancerous matter as to constitute the tumour distinctly felt during life; the descending colon was by this means fixed to the left kidney, which was enlarged to the size of a cocoa-nut, the interior being entirely occupied by cerebriform matter, except a narrow strip of cortical structure. The capsule could be easily separated, showing the cancerous matter in various conditions, *viz.*:—white and solid,

soft and pultaceous, and some portions highly vascular, like fungus hæmatodes.

The mucous membrane of the bladder was purple with congestion. The uterus contained in its posterial wall a fibroïd tumour the size of a nutmeg, which was easily enuncleated; the liver was healthy. The left pleural cavity contained about two pints of transparent serum tinged with blood; there were several patches of encephaloïd matter at the base of the left lung, and on the parietal pleura, and one mass about two inches in diameter, situated over the heads of the inferior ribs. The left lung was much shrunken; the right lung was healthy; the heart was remarkably small and flabby.*

Mr. T. Ballard, *2nd of November*, 1858.

---

3. *Ovarian Cyst which had contained seventy-two pints of Fluid.*

This was an enormous compound cyst, consisting of one very large cavity which had contained seventy-two pints of fluid, and of a number of smaller cysts. The patient, æt. 65, had suffered from the disease for twenty-six years, but had not been tapped until six months before her death, when thirty-six quarts of fluid were drawn off. Dr. Schulhof, who had attended the patient the last years of her life stated that "the first six months of the last year of her life she passed entirely in bed. Towards the close of that period defecation became more and more difficult. The girth of the abdomen was seventy-one inches." The cyst had been non-adherent, and the peduncle was long and narrow. Mr. Spencer Wells, *2nd of November*, 1858.

---

4. *Cyst of the Broad Ligament.*

This cyst Mr. Wells had found in a subject in the dissecting-room, lying between the uterus and the rectum. It was about the

* A case of encephaloid cancer of the kidney is recorded in the fourth Vol. of the Society's "Transactions," p. 191, by Mr. Obre, in which recurring hæmaturia with constant pain in the loin and hypogastric region, were the prominent symptoms.

size of an orange. It had been formed between the layers of the broad ligament, and was situated between the ovary and Fallopian tube. The fimbriæ of the tube were expanded over, and adherent to the cyst wall. It was a good specimen of what are termed cysts of the Wolffian body.

Mr. Spencer Wells, *2nd of November*, 1858.

---

5. *Case of Single Unsymmetrical Kidney.*

This kidney was taken from the body of a man æt. 45, who died of meningitis, in the London Fever Hospital, 28th of October, 1858. It occupied the usual site of the right kidney. In form and structure it presented nothing abnormal; but it was about twice the natural size, measuring five inches and three-quarters in length, by three inches and a-half in breadth, and weighing nine ounces and a-half. A single ureter passed from it downwards to the bladder, opening into this viscus at the usual spot. On the left side, not a trace of kidney or ureter could be detected; and in the mucous membrane of the bladder, there was nothing to indicate the opening of a left ureter.

Dr. Murchison, *2nd of November*, 1858.

---

6. *Abscess in the Right Lumbar Region, attached to the Kidney; Ulceration of the Bladder.*

W. T., æt. 60, a tailor, was admitted into the Somerset County Asylum, under the care of Dr. Boyd, in a state of melancholia. After treatment for two months, he was attacked with difficult micturition accompanied with pain, and distention of the hypogastric region; he was treated by warm fomentations to the abdomen; opiates were administered by the mouth, and introduced in the anus; the catheter was frequently used, and urine of a dark colour, and offensive to the smell, was drawn off. This treatment was continued for a month, when he died, having been in a comatose state for two days previously.

Post-mortem examination twenty-four hours after death.

Head: the dura mater adhered so firmly to the skull, that it was torn in separating, and numerous bloody specks were left on

its torn surface; the cerebral veins were congested with blood, and there was general congestion of the cerebral structure. The right hemisphere was one ounce and a-half heavier than the left: the entire brain weighed forty-four ounces and a-half.

Chest: Old pleuritic adhesions on both sides; some earthy matter in the apex of left lung. Heart small, weighing nine ounces.

Abdomen: The mucous membrane of the lower fourth of the ileum, of a dark-purple colour; the other portions of intestinal canal, natural; also stomach, liver, pancreas, and spleen. In the region of the right kidney, covered by peritoneum, was an elongated tumour, extending to the diaphragm, and laying on the convexity of the spine in that space; this when cut into, was found to be an extremely thick tissue, infiltrated with pus of a dark colour; smaller abscesses of the same colour were distributed through the kidneys, distending the tubular structure; the ureter on the right side was dark, and inflamed at the lower third, being covered with recent lymph; the tissues of the bladder were thickened, and the mucous lining at parts was destroyed by patches of ulceration. Mr. Obré, *2nd of November*, 1858.

---

7. *Strumous Disease of the Right Testicle in a Child aged Two Years and a-Half.*

H. M., a dark strumous child, æt. 2 years and a-half, was admitted into Guy's Hospital, upon the 13th of October, 1858, under my care. The disease had existed for six months, and had increased rapidly, in spite of all constitutional and local treatment. The testicle was about eight or ten times its natural size, and was perforated by a sinus, which had been discharging for four months, and which communicated with a large abscess in the interior of the organ. Upon the 26th of October, I removed the gland, and upon making a section of it, a large mass of grumous deposit, softening down, was seen to have been deposited in its centre, dilating the organ, which appeared as a mere shell, some healthy structure being visible around the mass. In the epididymis, were also three distinct masses of the same material.

The case is interesting owing to the early age of the patient,

the fact of the deposit occurring in the body of the testes, and the extent of the disease.

Mr. T. Bryant, *2nd of November*, 1858.

---

8. *Mass of Substance, of uncertain character, passed by the Vagina.*

This specimen was sent up to Dr. Ogle by Dr. Kennion, of Harrogate, who desired to have a report made upon it by the Pathological Society.

The substance was of a brownish-red colour, and about two inches and a-half long, and one inch and a-half broad, tapering at one extremity. It was flattened at one side and of rather firm consistency.

History of the case.—The substance was removed from the body of a woman, æt. 50, who had ceased to menstruate for three years. Eighteen months ago she began to have pain in the uterine region along with a discharge of blood: the pain during this time had varied in intensity, but the discharge had continued incessantly. Some months ago it was thought that high up, some uterine tumour could be detected through the abdominal walls, but none was discovered by vaginal examination until a week or two before the substance was rather suddenly passed, when a great deal of "forcing pain" was experienced along with frequent discharges of blood.

Dr. John W. Ogle *for* Dr. Kennion, 16*th of November*, 1858.

Report on the above case.—The substance, of questionable character, expelled from the vagina and transmitted by Dr. Kennion, is composed in a great measure of coagulated blood, and may pretty certainly be pronounced to have been formed within the cavity of the uterus. In submitting fragments of its outer layers to the microscope they were found to consist of fibrin, colouring matter, and an immense number of particles of columnar epithelium in various stages of disintegration. Besides these there were rounded nuclei, and much granular and molecular matter. The presence of the columnar epithelium leaves little doubt that the mass was

expelled from the uterus. On further examination, the same form of epithelial cells peculiar to the mucous membrane of the uterus, was found present throughout the coagulum to its very centre, and from this it may be inferred, that the blood was poured slowly into the uterine cavity, and thus became partially mixed up with the secretion on its mucous surface. No vestige of organized decidual structure was present, nor was there any trace of a pre-existing embryo. The anomalous feature of the substance is its shape, which bears no sort of resemblance to the uterine cavity. It has the form of a half cylinder flattened on one side, and might rather be supposed to be a mould of the vagina than of the uterus. The absence of scaly epithelium, however, is inconsistent with such a supposition.

W. O. Priestley, M.D.
John W. Ogle, M.D., *4th of January*, 1859.

Sequel to the above case.—About the latter part of January, 1859, the lady from whom the above uterine substance was expelled died with symptoms of peritonitis which supervened suddenly. Dr. Kennion caused a post-mortem examination to be made, and indications of recent peritoneal inflammation, evidently caused by extensive ulceration and consequent perforation of the fundus of the uterus, were found.

The uterus and its appendage were sent up by Dr. Kennion to Dr. Ogle, with the hopes that the same Committee who investigated the character of the substance above described, would report thereon. Consequently the Society requested them to examine the uterus, &c., and the following is the statement which they drew up respecting it:—

"The uterus is somewhat enlarged, and its tissues infiltrated everywhere with cancerous deposit.

"The cervix is in a less advanced condition of disease than the rest of the organ, but the posterior lip and neighbouring areolar tissue are indurated, and sections thereof yield a cancerous juice on pressure. In the upper part of the organ, however, the carcinomatous affection is further developed, the body and fundus being soft and lacerable, and having all the characters of encephaloïd disease as usually observed in the uterus. A large

irregular perforation into the peritoneal cavity exists in the posterior wall near the fundus uteri, and the morbid tissues around the aperture are soft and pulpy, and at some points even of a creamy consistence."

"*Microscopic examination* leaves no doubt as to the malignant character of the disease."

---

9. *Large Fibrous Tumour of the Uterus.*

The uterus and its contents were removed on the 27th of November from the body of a patient who had died on the previous day under the care of Mr. Hornby of York, to whom and to Dr. Swaine, Dr. Quain was indebted for the specimen and the notes of the case.

The growth of the tumour was supposed to have commenced shortly after the lady's last confinement which took place nine years ago. She was aged 40.

No other inconvenience arose from its presence than that resulting from its weight, and from occasional floodings. The nature of the tumour was not detected during life by examination per vaginam, the os uteri having presented nothing abnormal to the finger.

During the first five years the floodings were excessive, occuring at intervals of three or four months, but during later years they had been by no means so frequent or so profuse. The patient suffered, however, very severely from paroxysms of pain in the back and down the thighs. She died apparently of exhaustion, being extremely anæmic and emaciated.

Post-mortem examination.—On laying open the abdomen, the uterus was seen to have been covered only by integument, the muscular part of the abdominal walls having been entirely absorbed. The border of the liver was pushed upwards, rendering the gall-bladder visible.

Description of the specimen by Dr. Hill.—The uterus appeared as a firm unyielding mass, of ovoïd shape, and weighed eight pounds and a-half. It measured vertically from fundus to os, in diameter eight inches, in circumference twenty-three inches and a-half. Horizontally, it measured in diameter seven inches and a-half, in

circumference twenty-one inches. The ovaries were attached on either side a litle more than half way down.

On making a longitudinal incision through the front of the uterus, its walls were found to be considerably hypertrophied, being in some places at least half-an-inch thick; they enclosed a large, firm, somewhat elastic fibroïd tumour, of a yellowish-white colour. The upper half of the tumour was embedded in the muscular structure of the uterus, and the lower half was covered by a reflexion of the mucous membrane; hence it appeared that the tumour originated in the substance of the uterus immediately below the mucous membrane, at its upper and posterior aspect and rather more to the right than the left side, and that in the course of its growth it pushed down the portion of membrane covering it. This covering being in direct contact with the surface of the mucous membrane lining the rest of the cavity of the uterus had, no doubt, caused destruction of this membrane, for the opposing surfaces had become united throughout their whole extent by pretty firm adhesions, separable, however, by the fingers.

Microscopical examination of the substance of the uterus showed the anastomosing, branching, and curled yellow elastic fibres in great abundance, and also the smooth nucleated involuntary muscular fibre.

A thin section of the tumour had a very white appearance, and under the microscope was found to consist entirely of bands of white fibres, crossing each other in all directions, in which, after the addition of acetic acid, numerous elongated nuclei were seen.

There was a large quantity of fatty granular matter and oil globules in the tissue both of the uterus and the tumour, principally in the latter.

In the substance of the uterus, beneath the peritoneal covering, there were five small tumours, varying in size from a pea to a hazelnut, of the like character as the larger one, to the naked eye, as well as under the microscope, except that the nuclei of the fibres were larger and in greater quantity. One of these tumours had undergone calcareous degeneration. There was also on the abdominal surface a small and entirely calcareous tumour, an inch in length, hanging by a pedicle, which was attached close to the left ovary.

A portion of this calcareous matter, when submitted to the action of dilute sulphuric acid, was seen under the microscope, to dissolve with brisk effervescence, leaving in the fold a membranous-looking substance, and a large quantity of rosettes of acicular crystals, together with a great number of long needle-shaped and flattish crystals. The mineral matter was entirely dissolved by dilute hydrochloric acid. Dr. QUAIN, *7th of December*, 1858.

---

10. *Two Ovarian Cysts—Ruptured Spontaneously.*

1. One of these cysts was about the size of a new-born child's head. It had burst into the peritoneal cavity, which contained a large quantity of blood. The cyst was lined by layers of fibrine. There was no very distinct evidence to show whether the disease had been malignant, or whether an erectile tumour of the ovary had terminated in the whole ovary becoming a sanguineous cyst. There had been cancer in the breast. The patient was a widow, æt. 73, who had had several children. She ceased to menstruate at the age of 50, but two years before her death menstruation returned, and recurred regularly. On the later recurrences, the flow was excessive. Death took place very suddenly. The Fallopian tube was open, and there was a possibility that the uterine hæmorrhage had resulted from the cyst emptying itself through the Fallopian tube.

2. The other cyst was taken from a single woman, æt. 28. She had suffered about a year from ovarian disease, when Mr. Wells made an exploratory incision through the abdominal parietes preparatory to ovariotomy, but did not go on with the operation, as the tumour was situated behind several folds of intestine. The patient recovered from this, but died four months after from spontaneous rupture of a cyst into the peritoneal cavity. The tumour was a fine specimen of pseudo-colloïd ovarian disease, containing a large cyst and a great number of smaller ones, and alveolar cavities, filled with viscid, tenacious, semi-opaque matter.

Mr. SPENCER WELLS, *7th of December*, 1858.

---

11. *Pseudo-Colloïd Ovarian Tumour, successfully Removed.*

Sections of this tumour were shown, and a model of one half of it. It weighed, when removed, twenty-one pounds and had been surrounded by fifty-seven pints of ascitic fluid. It was covered externally by a firm fibrous capsule, in which large arteries and veins were seen. The section showed only one large cyst, which had contained from two to three pints of viscid fluid, but an immense number of imperfect cysts or alveolar cavities, from the size of a pea to that of a small apple. The walls of the cysts and alveoli were very vascular, and the contents consisted of a semi-opaque jelly-like substance, varying in colour, in different places, from white to dark coffee-colour, and in consistence, from that of firm jelly to that of white of egg. By a little pressure this matter was made to exude easily from the divided cavities. Thus the tumour may be described as a fibrous net-work, forming irregular cavities which contained a gelatinous matter. After squeezing out the contents, the septa were seen to form very imperfect separations between the cavities. Thus the skeleton of the growth was so far identical with that of colloïd or alveolar cancer. But *microscopical examination* of the viscid tenacious contents led to the belief that it was not true colloïd. A great deal of molecular matter was seen with free nuclei, and small oval or rounded cells of about the diameter of blood corpuscles; also, numerous large granular corpuscles, from two to three times the diameter of blood corpuscles, and an abundance of oil globules.

This tumour was removed by Mr. Wells on the 5th of November, 1858, from a married woman, æt. 33, who perfectly recovered, and there has been no sign of any tendency to reproduction in distant parts of the system, or to contaminate neighbouring parts. Mr. Spencer Wells, *7th of December*, 1858.

---

12. *A Kidney, containing very numerous and unusually large Calculi.*

The preparation will be best understood by the accompanying figure, which shows the whole cavity of the organ filled with im-

mense masses of stone, and the renal substance somewhat atrophied, but not to any very great extent. The ureter is seen to be healthy. The calculi proved on examination to be a mixture of the phosphates, in some places forming the friable calculus,

WOODCUT 10.

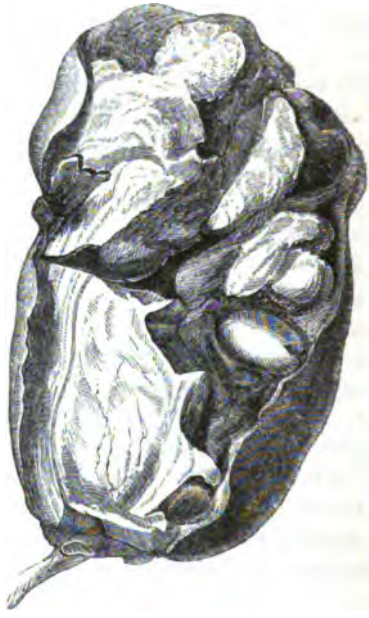

Represents one half of the kidney, with the contained calculus masses. (Half the size of nature.)

in others, with a preponderance of the phosphate of lime (Dr. Bence Jones). The preparation was taken from a patient who died of some perfectly different disease, and was not known to have ever exhibited any renal symptoms. The water had been tested during life, and found free from albumen. It was said, on examination a few days before death, to show superabundance of lithic acid. Mr. T. HOLMES, *7th of December*, 1858.

13. *Fibrous Tumour of the Ovary.*

The patient in whom this tumour was found after death had not suffered from its presence during life. She died of diseased heart and kidneys, at the age of 64. Mr. Spencer Wells had seen her occasionally with Mr. Swete, of Stockwell, who found the tumour, on vaginal examination, depressing the anterior wall of the vagina, lying behind the bladder, and pushing the uterus backwards.

On removal, it appeared of about the size of a large cocoa-nut. It was so hard that a saw was necessary to divide it. At first sight it was thought to be a calcified fibrous tumour of the uterus, but Mr. Swete, who made the examination, found the uterus and right ovary quite healthy, while the left ovary was replaced by the tumour.

A section of the tumour showed, on *microscopic examination*, that it was composed of fibrous tissue, the denser parts being calcified by a deposit of carbonate of lime. There was no tissue found in the least resembling true bone.

Mr. Spencer Wells, *4th of January*, 1859.

---

14. *Fatty and Atrophied Kidney.*

This specimen was removed from a subject in the dissecting-room of the Westminster Hospital, and presented externally the appearance of a mass of fat, occupying the position of the left kidney. On section, it was found to consist chiefly of adipose tissue, in which were apparently interspersed small portions of kidney substance. There were slight traces of pelvic structure present, and the microscope afforded evidence of the presence of Malpighian bodies in some portions of the mass. The opposite kidney was normal in size and appearance, and possessed two renal arteries, while the fatty one had no distinct artery at all from the aorta, although there was probably some supply from those of the neighbouring arteries, which was overlooked, owing to the body not being injected. Neither vein nor ureter could be traced from the diseased kidney.

This specimen must be looked upon as of morphological rather than pathological interest, the changes in it being evidently due rather to an arrest of development and deposit of fat, than to any morbid process going on in the system.

Mr. CHRISTOPHER HEATH, 18*th of January*, 1859.

---

15. *Uterus Unicornis.*

The specimen was taken from a subject, æt. 35, brought to the dissecting-rooms of the Middlesex Hospital, which presented other indications of arrest of development; namely, in the left upper extremity, and also in the right hand. The undeveloped half of the uterus was that belonging to the left side; the left ovary was present, but the left Fallopian tube wanting. The left round ligament was well marked. The cervix was long, retaining, in a great measure, its fœtal proportions and peculiarities. The vagina was virginal, partially closed by a hymen. The ovarian arteries and pelvic venous plexuses appeared normal. Although the Fallopian tube of the left side was undeveloped, its trumpet mouth was discernible, attached to the ovary by one of its fimbriæ. The left ovary itself was situated at the brim of the pelvis, not having assumed its normal position in the broad ligament; consequently, its ligament was longer than that of the right one. The specimen was brought before the Society as illustrating the question put before the Society by Mr. Nunn last session, as to whether the left ovary was not, in the majority of instances, at a greater distance from the uterus than the right one, and whether such greater distance was not due to the less perfect development of the left half of the body.

Mr. T. W. NUNN, 1*st of February*, 1859.

---

16. *Pseudo-Colloïd Ovarian Tumour, removed during life by Ovariotomy.*

This tumonr was removed by Mr. Wells from a single woman, æt. 39, on the 21st of January, 1859. She went on well for twenty-four hours, and then suddenly went off into collapse, and

died thirty-two hours after operation. The peduncle was secured outside the wound.

Post-mortem examination showed a large effusion of acrid serum into the peritoneal cavity, and superficial exudation of lymph. The peritoneal edge of the wound in the parietes had not been brought closely together. The hare-lip pins used had been passed close to the peritoneum, but had not transfixed it.

The tumour weighed ten pounds and a-half. It was a fine specimen of pseudo-colloïd ovarian tumour, closely resembling that described in a former case in which the operation was completely successful.

Mr. Spencer Wells, 1*st of February*, 1859.

---

17. *Case of Double Urethra, taken from a full grown well-developed man; also the subject of an Obliteration of the Aorta, see page* 97.

The true urethral tube (*i.e.*, that connected with the bladder), is *hypospadian;* its external orifice occupies the position of the "*frænum preputii,*" which is entirely absent.

The abnormal urethra is about one inch and a-half long, terminating in a "cul-de-sac." It lies above the canal just described, does not communicate with it, and occupies the position of the "*fossa navicularis,*" of which it is probably a backward development. A double fold of mucous membrane separates the two canals, apparently an over development of the slight ridge which normally marks the posterior boundary of the fossa. There was no stricture, nor does the formation appear to have given rise to any great inconvenience, or necessitated any surgical interference.

Mr. J. Wood, 1*st of February*, 1859.

---

18. *Case of an Ovarian Cyst containing Hair, Epithelial Cells, and Fat in abundance.*

The specimen was taken from the ovary of an elderly female. It was of the size of a small orange. The contained hairs were fine, light-coloured, and varied from half-an-inch to three inches long. They were arranged in concentric layers, coiled round and

round, and intersecting each other. They had no bulbs, but tapered off thin at both ends, as if by gradual atrophy and shedding from the bulbs from which they must have sprung. Intermixed with, and around the mass of hairs, was a considerable quantity of fat, containing the shrivelled débris of squamous epithelial cells. This fat was, no doubt, fluid during life, as it melted readily on being exposed to heat equal to that of the body.

Mr. J. Wood, 1*st of February*, 1859.

---

19. *Fibrous Tumours of the Uterus.*

M. W., æt. about 60, was brought into the Infirmary of Marylebone, dead, without history, and an inquest was held upon the body. Pleuro-pneumonia and destitution appeared to have been the cause of death.

Post-mortem examination.—On examining the uterus, a tumour was found pendant in the peritoneal cavity, attached to a very slender pedicle. The size of the tumour was about that of a walnut. Another, of smaller size, but connected by an equally small pedicle, was pendant in the cavity of the uterus. Several small tumours existed in the substance of the uterus; all were of the common or simple fibrous variety. A mass of calcareous matter was found in the interior of the first-named tumour.

Mr. Henry Thompson, 1*st of February*, 1859.

---

20. *Vesico-vaginal Fistula.*

E. F., æt. 36, was admitted into St. George's Hospital, originally in June, 1858, under Mr. Pollock's care, on account of vesico-vaginal fistula. She was said to have been married at the age of 14, but never to have had a child till twenty-two months before admission. She was in labour on that occasion for four days and nights, and ultimately delivered by ovariotomy. Ever since that time she had had complete incontinence of urine, and had suffered occasionally from attacks of inflammation of the bladder. She was, for some weeks after her admission, kept under treatment on this account and also from the loss of appetite and constitutional weakness under which she laboured; and when she was somewhat

improved in these respects, the first operation was performed on the 12th of August. The cleft having been exposed, was seen to be of a very large size, so as to allow the protrusion of a portion of the mucous membrane of the bladder as large as a walnut. It was situated at the anterior part of the base of the bladder, extending forward nearly to the urethra. The urethra itself was considerably constricted; but after some little difficulty, a full-sized catheter was forced into the bladder. The edges were then pared, and the cleft brought together in the usual way, with Bozeman's button, and six silver sutures, longitudinally. The operation was necessarily a protracted one, and she was kept under chloroform for an hour, but seemed to bare it tolerably well.

The cleft was examined for the last time on the 16th of September. It was then found to have united by the first intention in front to some extent, but an orifice remained behind, through which the mucous membrane of the bladder protruded.

She was sent out of the Hospital on the 17th of October, for the benefit of her health, and reädmitted in January, 1859. She then reported that her condition had not been improved by the operation, and that all the urine still ran away. On examining the opening, it was found much larger than after the operation, measuring about an inch and a-half in length, and rather more than that in breadth. The operation was repeated on the 13th of January; eight silver sutures being used, and the line of union made transverse. She was kept under chloroform for more than an hour.

On the 15th of January it was noted that she was low and weak, and had no appetite. She complained of no pain in the abdomen.

On the 24th of January she still remained in a low state, and drowsy and disinclined to answer questions. The tongue was dry and red. The urine copious, alkaline, containing some mucus, but no albumen. The plate was in position, and everything looking well about the wound. No cause was discovered for her symptoms.

On the 29th of January, she had rigors, and there was said to be a purulent discharge from the rectum; the urine was very fœtid and alkaline.

The catheter was removed, and the shield taken away. A

small part of the cleft was found ununited. She gradually sank into a half unconscious state, without any more prominent symptoms, and died, comatose, on the 4th of February.

On *post-mortem examination*, it was found that the peritoneal cavity was perfectly healthy. The fatal disease appeared to be situated in the kidneys, one of which was much atrophied, and the pelvis of the kidney on one side occupied by a number of renal calculi; one of these calculi had passed down into the bladder.

The parts concerned in the operation presented the following appearance:—The bladder was small and healthy in structure, except at the fundus. Here was a small cleft, above half-an-inch in length, which extended into the vagina, and on either side of which there was a transverse cicatrix, the trace of the second operation. No traces of the first operation were visible in the bladder. The bladder contained a small oval calculus, which might have easily passed through the cleft, and which, therefore, was supposed to have been in the bladder for no very long period. In the vagina the traces of the operation were more perceptible. Extending forwards longitudinally from the cleft to about a quarter of an inch from the urethra, was a linear cicatrix, about three-fourths of an inch in length, which was, in all probability, the result of the first operation. The line of union from the second operation was marked both by an irregular transverse scar, and by the presence of four of the silver sutures which had not been interfered with since the operation, and which remained in the mucous membrane of the vagina, without appearing to produce any irritation; at least there was no trace of ulceration around them, although the whole surface of the vagina for some distance around the cleft was covered with a leathery exudation, easily removed. One of the silver sutures had very nearly cut itself out, but the line of its ulceration had been closed as rapidly as it had been formed, and was quite imperceptible.

Mr. Holmes, *2nd of March*, 1859.

---

21. *Liquid Fat from a Piliferous Ovarian Cyst.*

J. K., æt. 52, was admitted into Guy's Hospital on the 4th of

January, 1859, for apoplexy, and shortly died. She was married, but had never borne any children.

On *post-mortem examination*, eight hours after death, the body was still warm; it had a considerable amount of integumental fat. There was an effusion of blood into the pons Varolii, which was the immediate cause of death. The left ovarium contained a cyst about the size of the closed fist, which, when opened, poured out a quantity of liquid fat like melted tallow, which soon consolidated into a hard cake; there was also much hair, but no teeth or bone.

This is the only case I know where the fat in these cysts has been proved to exist in a liquid state, although it has often been surmised. Thus Dr. Hare, in a former volume of these "Transactions," relates a case where solid fat was found after death in an ovarian cyst, but which gave all the evidence of having been a fluid one during life; and on applying heat to the substance, he found that it melted at a temperature of 85°, which is much below that of the body. He also alluded to a case where liquid fat had been drawn off during life, and which was supposed to come from a diseased ovarium. The fact of the fat existing in the fluid state, must disprove the theories advanced in explanation of the peculiar forms this substance occasionally puts on. For example, in Guy's Museum is a jar containing an immense quantity of small round balls of fat, and which were supposed to have been formed by some rotatory or churning action of the cyst; it is clear, however, that they are mere consolidations caused after death has taken place. The source of the fat appears to be the sebaceous follicles so thickly covering the interior of these cysts, and the hair is shed from the follicles amongst them. Dr. WILKS, *2nd of March*, 1859.

---

22. *Encephaloïd Cancer of the Testicle.*

The specimen was removed by operation on the 9th of February, 1859. The patient, Mr. C., æt. 28, a tradesman, a tall spare man, received a blow on the left testicle more than five years ago. Since that period, the organ had been gradually increasing in size, growth having advanced more rapidly within the last six months. He had been treated without benefit by different surgeons. He

had suffered no pain in the part, and the inguinal glands were free from enlargement. His general health was good, and after excision of the testicle, the wound healed in three weeks.

The diseased testicle was of an oval shape, flattened at the sides, and measured five inches from above downwards, four inches from before backwards, and about two inches and three-quarters from side to side. At the lower part, the surfaces of the tunica vaginalis were closely adherent. The upper third contained about an ounce and a-half of bloody serum. A narrow fungus, an inch in length, projected into the sac from the upper part of the tumour, the tunica albuginea having given way at this part. A section exhibited a central soft friable mass of an opaque yellow colour, forming nearly half the bulk of the tumour. External to this, the growth has a mottled appearance, yellow patches alternating with minute extravasations of blood and small nodules of soft whitish semi-transparent matter. At no part of the cut surface could any trace of the tubules of the testis be found.

Dr. Andrew Clark, after a careful and minute examination of the structural constituents of the tumour, inferred, that it was an example of encephaloïd cancer, in which, during life, the process of retrograde metamorphosis very nearly balanced that of growth: the growing part being confined to the circumference, and the dead part occupying the centre of the tumour.

The two points of special interest in relation to this specimen are:—1. The unusually slow progress of the medullary disease; and 2. the large amount of dead cancer tissue comprising the tumour. Mr. Curling, 15*th of March*, 1859.

---

23. *Case of Follicular Tumour of the Uterus.*

In this specimen the tumour grew from the fundus of the the womb, involving the mucous membrane and the subjacent structure. It is of the size of a small walnut, and has a broad base, without any constriction or neck as in ordinary polypus. It is soft and apparently very vascular. On section it is seen to contain numerous tubes or canals travelling through all its substance, and connecting by strong processes of fibrous tissue. They do not appear to contain fluid, at least in the present state of the

specimen, which is rather old. These are probably the hypertrophied follicles of the uterine mucous membrane. The tumour is considered by my friend Dr. Farre as an instance of that described by Oldham, under the name of the *channelled tumour* of the uterus. Mr. J. Wood, 15*th of March*, 1859.

---

24. *Two Specimens of Ovarian Disease.*

The *first* specimen was an example of compound cystic disease, accompanying a rare malformation of the uterus: namely, the almost complete isolation of the body of the uterus from its cervix, the slight connection that existed being formed by a narrow fibrous band. The body of the uterus was larger (about twice or thrice) and the cervix smaller (about one-third) than normal. The patient, æt. 26, from whom the specimen was taken, had undergone ovariotomy, by Mr. J. B. Brown (to whom Mr. Nunn was indebted for the opportunity of exhibiting the specimen). She had never menstruated; from ten years of age, an ovarian tumour had been suspected. The tumour itself was of the compound character, multilocular, the cysts containing hair, bone, cartilage, and fluids of different colours and densities. Perhaps by some it would be described as cysto-sarcomatous.

The *second* specimen was from a patient, æt. between 40 and 50, who made a favourable recovery after ovariotomy by Mr. J. B. Brown. The specimen consisted of a large warty growth, the size of three fists, connected with some small cysts, of the proliferous kind, of the right ovary, and of similarly compound cystic growths of the left ovary. The warty growth, in its original state, was of a most delicate pink hue. It was made up of innumerable clustered villous and cystic elements, such as are described in Mr. Paget's Lectures, Vol. II., pp. 63 and 511, as constituting the element of cystic disease of the chorion in the first instance, and of dendritic vegetations in the second. The small cysts also contained warty growths of the same nature; probably, therefore, the large warty mass originated *within* a cyst, which had been ruptured at some stage of the disease. Nevertheless, it is to be observed, that scattered warty growths

were found over the peritoneal surface of some of the cysts, and of the Fallopian tubes.

Mr. T. W. Nunn, 19*th of April*, 1859.

---

25. *Communication between the Bladder and the Sigmoïd Flexure of the Colon.*

There was an opening in the bladder at the lower end of the posterior wall, of the diameter of a goose-quill, evidently not of recent date. The bladder corresponding to this aperture was intimately united by old adhesions to that part of the circumference of the sigmoïd flexure of the colon that lies nearest it; this aperture communicated with the sigmoïd flexure opposite their point of union. Above the point of communication of these viscera, for the extent of about an inch, the canal of the sigmoïd flexure was somewhat constricted; but the constriction was apparently due to the adhesion and subsequent contraction of these viscera: as beyond the point where the adhesion existed, the calibre of the intestine appeared normal. Below the orifice of communication between the bladder and colon, the canal of the intestine was greatly constricted, to the extent of an inch and a-half in length; the stricture appeared to depend upon great condensation and subsequent cicatrization of the sub-mucous and muscular tissues of the bowel. The mucous membrane of the intestine above the seat of stricture presented, in many places, pouches, varying in size from a pea to a filbert, and formed by the protusion of this coat externally; opposite to the stricture it appeared to be in every respect quite healthy, but very densely convoluted. Below the seat of stricture, the bowel was considerably dilated, and had, during life, apparently acted the part of a second bladder, as from the symptoms described by the patient, the urine used to accumulate there in considerable quantities, being passed 'per anum.'

The kidneys were somewhat congested, but in other respects healthy in appearance. *There was no calculous matter in the bladder.*

This preparation was removed from a gentleman æt. 57, on whom Mr. Charles Hawkins operated for stone, by lithotrity, a

year previous to his death. The case is related in the *Medico-Chirurgical Transactions* for 1858. Vol. XLI., p. 441.

Mr. CHARLES HAWKINS, *3rd of May*, 1859.

---

26. *Obliteration of a Ureter. Abscess-like Dilatation of the Calices of the Kidney.*

The kidney presented to the Society was taken from a lad between 18 and 19 years of age, who had for several years been subject to a painful incontinence of urine; his sufferings had been intense, both in his urinary passages and in his loins. The urine from the commencement appeared to have been charged with pus, and was frequently bloody. At one time, he was under treatment for six months, with, however, no permanent benefit, as the malady returned upon him within a month of his discharge from the Bridgewater Infirmary. After death, the left kidney was found to have lost all its original structure, and to be converted into a number of sacs, containing a pus-like fluid, each cavity being lined with a distinct membrane, which, when separated, preserved the form of the abscess. These cavities seemed to have had no outlet. The ureter was atrophied and impervious, and with the vessels, was surrounded by a great quantity of fat. The right kidney was hypertrophied and pale, having a cavity at one of its extremities which contained pus; its ureter was considerably enlarged and embedded in fat, which also contained a great number of indurated lymphatic glands. The bladder was reduced greatly in size, its mucous membrane soft, thrown into rugæ, and bedewed with pus. The urethra was in a similar state. The colon was filled from one end to the other with impacted fæces, a great number of which he had passed from time to time during the whole period of his illness. Obstinate sickness and pain in the epigastrium were the prominent symptoms before death, added to increased dysuria and incontinence. His illness was attributed by his parents to his excessive fondness for bathing; up to his thirteenth year he was a fine healthy lad. It must be observed, nevertheless, that four or five years before his death, he fell on his back from a height of twenty or thirty feet; he, however, appeared only to have been

shaken, and he soon recovered. It is very probable that this accident caused the obliteration of the ureter, and that from this followed the disease of the kidney.

Dr. QUAIN, for Mr. ALFRED HAVILAND, 17*th of May*, 1859.

---

27. *Syphilitic Fibroïd Degeneration of the Testis.*

These specimens came from a man who died of phthisis, the sequel of syphilitic disease of the larynx and other organs. The testes were about half their natural size and hard; a section showed nearly all the secreting structure displaced by a tough fibrous tissue, which, no doubt, would in time have completely occupied the whole organ. I have observed this condition in numerous cases of persons who have died of syphilitic affections; and in some the testes have been completely changed, and instead of the fibrous tissue presenting a uniform surface, it has existed in the form of nodules as in this other specimen which I now exhibit. There can be no doubt whatever, that the testes undergo a fibroïd degeneration in syphilis; but I do not think that this is a sequel to any active inflammatory process, for in no case where I have found this condition after death, has there been any such history during life. Surgeons appear still divided in opinion as to the existence of a specific form of orchitis, but whatever is held in this respect, it has, I believe, no reference to the disease of which I speak, which is rather to be styled a degeneration.

Dr. WILKS, 17*th of May*, 1859.

---

28. *Case of Retention of Fœtal Bones in a Uterus affected with Cancer.*

C. M., æt. 49, had borne thirteen children, and sustained two miscarriages. Eleven months before her death, she began to suffer pains resembling labour; these were followed by a vaginal discharge, and, two months later, by a third miscarriage; the embryo, however, appearing to be scarcely formed. Subsequently, repeated and alarming hæmorrhage occurred; the disease was recognized as cancer of the uterus; she was admitted into the Middlesex Hospital on the 5th of April, and died on the 22nd.

Post-mortem examination.—The uterus was large, firm, and infiltrated with a white granular deposit. The cervix was completely destroyed by an extensive slough, from which a probe passed (laterally) into an artery of considerable diameter (the A. uterina sinistra), and (posteriorly) into the rectum. Within the cavity of the uterus were lying free the bones exhibited to the Society, belonging to the cranium, the thorax, and the extremities of a fœtus, aged (apparently), about ten weeks.

If, as seems certain, the bones belonged to the fœtus, whose abortion took place nine months previously, it seems most probable that the exclusion of the dead embryo was prevented by the presence of a cancerous slough in the cervix; a circumstance which would account for the supposition of the mother—that the child was scarcely formed. The soft parts may have undergone decomposition and escaped in a fluid state; the missing bones of the skeleton perhaps found an outlet through the rectum, after a communication had been formed with that viscus.

Dr. Cooke, 17*th of May*, 1859.

VI.—DISEASES, ETC., OF THE OSSEOUS SYSTEM.

1. *Dislocation of the Head of the Right Femur into the Obturator Fossa, in a Man deformed from Rickets.*

Mr. Shaw exhibited the right hip-joint of a man, æt. 28, a porter, who, on the 10th instant, in a fit of religious despondence, had thrown himself from the top of a house sixty feet high. He had no injury of importance in the head, chest, or abdomen; but in the right lower extremity, there was dislocation of the head of the femur into the obturator fossa; and in the left, comminuted fracture of the femur, with two wounds, one in the front and the other in the outside of the thigh, through which the ends of the fragments had protruded. From his general figure, and the bones of both legs being curved, it was apparent that in early life he had been affected with rickets; but the deformity was not considerable; and his muscles were well developed.

The signs of the dislocation of the right hip were:—1. Sinking inwards of the trochanter major, so great as to cause a visible depression of the hip, at the part. 2. Flexion and abduction of the thigh upon the pelvis, with the knee elevated, in a straddling position, much above the level of the body. 3. Resistance and excessive pain in attempting to adduct, invert, or depress the thigh. 4. A protuberance distinctly visible near the perineum, caused by the head of the femur lying in that part; and the rolling motion of the head, perceived when the limb was rotated.

The patient having been laid along the edge of a low bed, and put under the influence of chloroform, the reduction was effected, at one effort, by the following method:—A jack-towel, folded to the breadth of five inches, was carried along the inside of the right thigh to the flexure at the perineum, and made to bear upon the prominence caused by the displaced head of the femur; its end, twisted round the upper part of the thigh, was held by assistants placed at the right shoulder of the patient; other assistants on the left fixed the pelvis: Mr. Shaw, standing between the patient's thighs, and grasping the right knee, first drew the thigh down vertically from the pelvis; he then placed his own right knee against the side of the patient's perineum, to make it act, in addition to the jack-towel, as a fulcrum; and by drawing the limb inwards and downwards, and at the same time, pushing the head of the femur from him, by means of his knee, he succeeded in returning the bone to its socket, with an audible snap.

Notwithstanding the frequent and liberal supply of stimulants, the patient did not recover from the collapse produced by the general shock of the injury; and he died fifteen hours from the time of the accident. It did not appear that the administration of chloroform had any effect either in increasing or diminishing the collapse.

Post-mortem examination.—From the extent of laceration in the soft parts surrounding the fractured ends of the left femur, it was apparent that had the patient lived, the limb could not have been saved. In the dissection of the right hip, the following points were noted:—At the origin and the insertion of the gluteus

medius ecchymosis was found; the sacro-sciatic nerve was surrounded by extravasated blood, which also penetrated between its fibrils; a few fibres of the pyriform muscle were torn; at the anterior part, there was extensive ecchymosis of the superficial fascia; three inches from its origin, the gracilis was torn quite through; at a similar distance from their origins, the adductor longus and brevis were torn to three-quarters of their thickness; the obturator externus had some fibres bruised; the obturator nerve appeared as if it had been partially insulated by laceration of its connecting tissue. The capsular ligament of the hip-joint, at its inner and posterior attachment to the acetabulum, was extensively detached, so that the head of the femur easily protruded; the ileo-femoral ligament, also, at its outside, was partially separated from the neck of the femur, and a small rent extended from that point into the capsular ligament; the ligamentum teres had been torn from its pit in the head of the femur. In common with the general distortion from rickets, the pelvis was deformed; the principal change being a diminution of the antero-posterior diameter of the inlet.

Mr. Shaw remarked that dislocation of the head of the femur into the obturator fossa, being a comparatively rare form of that injury, it was interesting to connect with its occurrence in this case, the fact of the patient having been deformed from rickets. He had observed that, in the most common deformity of the pelvis, as found in the present case, *viz.*:—where the inlet is diminished in its antero-posterior diameter, the direction in which the acetabula face or look becomes changed. Instead of the axis of the cavity of each socket pointing, as in the normal form, outwardly as well as forwards, it is directed, in the rickety pelvis, either wholly forwards, or forwards with an inclination inwards. This turning inwards of the acetabula is obviously a consequence of the front segment of the pelvis, during the softened condition of the bones while the disease prevailed, having been compressed and flattened towards the sacrum; for as the bend in the ossa innominata which thus takes place, occurs behind the acetabula, it follows that these cavities must partake in the movement of the segment, and that their axes must be directed forwards and inwards. It is easy to perceive how greatly such a turning in of

the socket, in case of violence sufficient to produce dislocation, must dispose the head of the femur to slip inwards on the obturator fossa.

Another point connected with the deformity of this patient, Mr. Shaw considered to deserve attention. Whenever distortion from rickets exists in a skeleton, even to a slight degree, he has observed that the head and neck of the femur are depressed below their proper level, in relation to the shaft and trochanter major. That is obviously caused by the pressure of the superincumbent weight of the body, in the softened condition of the bones, being too great for the neck of the femur to sustain, and it then with the head sinks downwards. He considered that this depression, by increasing the inclination of the axis of the neck of the femur inwards, must add to the tendency of the bone to be dislocated on the obturator fossa, in case of injury.

These remarks were illustrated by reference to a skeleton, and a pelvis deformed from rickets, brought to the meeting.

Mr. Shaw, 19*th of October*, 1858.

---

2. *Acute Periostitis of the Tibia, with Necrosis of the entire shaft of the Bone, following Strumous Disease of the Ankle Joint.*

The patient is under the care of Dr. Cooper Rose, of Hampstead (to whose kindness I am indebted for the opportunity of showing the specimen). She is a pallid strumous looking child, æt. 13. The disease commenced about the 14th of September, 1858, with a dull aching pain in the instep and ankle of the right leg. There was no swelling, and she could not recollect having met with any injury. On the 16th, the ankle became puffy and very painful; subsequently, suppuration took place at both malleoli, but was freely relieved by incisions. About the 20th, the pain and swelling extended over the whole of the tibia; fluctuation was detected beneath the periosteum, and pus evacuated by free incisions. Fourteen days from the outset of the disease, the ankle joint appeared to be destroyed; the foot was twisted inwards, and greatly œdematous; the slightest movement gave rise to intense pain; pus was escaping freely from both sides of the joint, and from the opening in front of the tibia. This state

of things continuing with more or less aggravation of symptoms and constitutional depression, it was decided, after a consultation, to amputate the limb, which was accordingly done, at a short distance above the knee, and the patient is now doing exceedingly well.

On examination of the limb, the knee-joint was found to be perfectly healthy, and the upper articular surface of the tibia in sound condition. In the ankle-joint the articular surface of the astragalus was in great part of its extent bare and spongy, with only a thin rim of cartilage remaining all round. A similar condition existed in the articular end of the tibia: the bone being exposed and rough, a thin margin of healthy cartilage alone remained, lining the malleolar projection, and covering the posterior and part of the outer borders of the articular surface. The part of the fibula entering into the joint was covered with healthy-looking cartilage, except at two spots, which exhibited signs of commencing destruction. Otherwise there appeared to be no disease of the fibula or its periosteum.

The lower end of the tibia was in a softened, spongy state, deeply discoloured, and readily breaking down; this condition extended to about an inch from the joint, including part of the shaft, as well as the epiphysis, which was loosened, so as to be easily moved on the rest of the bone.

Round the head of the bone, the periosteum was not affected, and was firmly adherent, as it was also along a line of very irregular breadth, varying from half-an-inch to an inch and a-half, down the entire length of its anterior border; everywhere else it was completely separated, leaving the bone bare, smooth, and white. The membrane was throughout thickened, and vascular, and where not adherent to the bone its inner surface was covered by a thick coat of small, soft, flattened granulations bathed in pus, giving, when washed, a velvety appearance to the surface; numerous opaque yellow spots occurred among the granulations, giving the idea of commencing ossification; but when examined microscopically, they only showed clusters of oil globules lying among the fibro-cellular elements of which the granulations were composed.

This specimen was chiefly interesting in a pathological point of

view, as affording a good opportunity of observing the condition of the periosteum when so extensively separated from the bone; the granulations which had formed throughout on its inner surface, in a more vigorous state of constitution would probably have developed into new bone, though here they only exhibited a retrograde tendency, as evidenced by the deposition of fat among them. It is difficult to say whether the inflammation of the periosteum, or of the tibia itself took place first, as either might be consequent upon the disease in the ankle-joint, and might terminate in the condition which was found in the specimen; the result must have been the same, as the fact of the joint and lower articular end of the tibia being destroyed as well as the shaft, had rendered recovery of the limb almost an impossibility, even if the powers of the patient were sufficient to have made the attempt advisable.

Mr. W. H. Flower, 19*th of October*, 1858.

---

3. *Necrosis of the Intermaxillary Bones.*

M. M., a child æt. 3, was brought to me at Guy's Hospital upon the 19th of July, 1858, when convalescing from an attack of measles, which she had contracted two months previously. Ulceration of the gums followed this disease, and as the parts refused to heal, the parents brought the child to me.

Upon examination of the mouth, necrosed bone was detected in the median line of the upper jaw, and with a pair of dressing forceps, the intermaxillary bones were removed. Two weeks afterwards, a loose tooth showing itself at the part was easily taken away, and the child is now quite well.

The bones are the most perfect specimens of the kind I have ever seen (woodcut 11); their external, internal, and general appearances are well represented in the drawings. It may be observed that each bone appears to contain only half the socket of the middle incisor tooth, and as the tooth which has been removed would appear from its size to belong to the second set, we may hope that the other is still retained in its position in the maxillary bone, and may yet be preserved for the future use of the patient.

The connection between necrosis of the alveolar processes of

the maxillæ, and the eruptive fevers, has long been well known to surgeons, but its pathology has not been thoroughly described till Mr. Salter published his short memoir upon it in the last volume of the Guy's Hospital Report, and taking his experience as equal

WOODCUT 11.

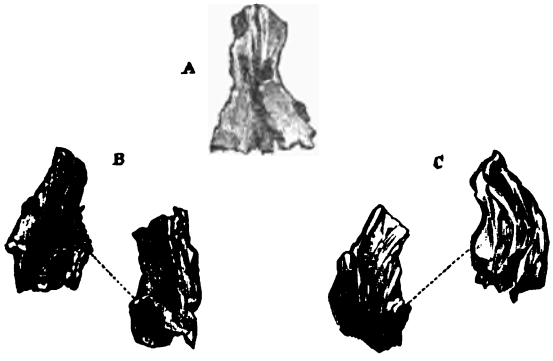

A, anteria; B, external; C, internal view of the intermaxillary bones.

to any other surgeon-dentist upon this subject, I find the case I have related presents many points of interest and singularity.

Mr. Salter tells us that he has never seen this disease in children younger than five years, and that it is always confined to molars and bicuspid teeth. In the present instance, the patient is but three years of age, and the disease is located in the intermaxillary bones. On the other hand, the disease has involved both the temporary and permanent teeth—is found in the female sex—and has followed an eruptive fever.

The chief interest in this case consists in the death of the whole bones, and the perfect condition of the specimens.

Mr. T. BRYANT, *2nd of November*, 1858.

---

4. *Disease of the Knee-joint supposed to be Strumous.*

The parts exhibited were removed from a limb amputated by Mr. Pollock, after the method introduced by Mr. Teale, on the 11th of November, 1858.

There was a considerable swelling over the lower end of the

femur formed partly of thickened synovial membrane, but principally of condensed cellular tissue external to the joint. There was also a swelling in front of the head of the fibula, near the tendon of the biceps, which communicated with the cavity of the joint, and was in connection with a rather deep excavation in the external tuberosity of the tibia, close to the head of the fibula, but not involving the tibio-fibular articulation. This swelling, as well as the cavity of the joint, was full of strumous-looking, curdy pus. There were several cavities, similar to the one above described, in the articular ends of the bones, the deepest being situated between the condyles of the femur. They contained pus similar to that above described, and a few spicula of dead bone. The cartilages were removed in several places, especially over the outer condyle of the femur. The ligaments were all healthy. The joint-ends of the bones were somewhat enlarged, and in one of two spots, quite removed from the articulation, were considerably more vascular than natural.

This disease was supposed at the time to be of a strumous nature, and to be caused either by unhealthy inflammation having its origin in that constitutional state, or by the softening of strumous tubercle, eating away cavities in the bones and bursting into the joint. This supposition rested on the observation of the case during life, when the symptoms were very obscure, and not marked by any well-defined inflammatory appearances; and was supported by the examination of the parts, which showed the joint filled with matter such as is usually seen in strumous cases, and a number of excavations, not containing any sequestra, but from which the bone had been gradually eaten away, leaving no trace except the presence of minute bony spicula. It was urged at the time of exhibition, that the mischief might have resulted from the exfoliation of a necrosed portion of the femur and its escape into the joint. No trace, however, of any such sequestrum was found—the cavities looked of pretty similar standing, and there seemed to be a lack of both the symptoms and appearances of acute disorganization of the joint, which might be expected to follow such an accident.

The original diagnosis was much strengthened by the progress of the case, in which the patient having recovered from the am-

putation, sank rapidly of phthisis. The preparation exhibits a form of disease rarely met with and little noticed in the books. It will be found in the Museum of St. George's Hospital.

Mr. T. Holmes, *7th of December*, 1858.

---

5. *Dislocation of the Spine in the Dorsi-Lumbar Region.*

This preparation was taken from the body of a man, æt. 19, who had been struck on the loins by a heavy piece of timber, and was admitted, under the care of Mr. Cæsar Hawkins, into St. George's Hospital, on the 30th of October, 1858. On examination a projection was found in the lower part of the dorsal region, the upper vertebræ being at least half-an-inch forwarder than the lower. He was completely paralyzed in the lower extremities and bladder. Gradual and steady extension was made by pulling on the feet and shoulders; and in about a minute the click of reduced dislocation was plainly heard, and the spinous processes returned to their right place; but the symptoms were not relieved, and he died on the 22nd of November with secondary deposits in both knee-joints.

The preparation, which is preserved in St. George's Museum, shows the last dorsal vertebra separated from the first lumbar, the intervertebral cartilage being torn through. The anterior common ligament was stripped off the body of the lumbar vertebra, and a few granules of bone torn away with it, but there was no fracture of the body. The articular processes of the two vertebræ were separated on both sides. The transverse processes of the lumbar vertebra were fractured, and small pieces of the left lamina, at the root of the transverse process, seemed chipped off; but there was no fracture which would have given rise to displacement. The vertebræ, at the time of the examination, were in perfect apposition, but they could be readily displaced, either backwards or forwards, by a little manipulation, and seemed to be held together only by some parts in the spinal canal, as the various external ligaments were torn across. There was a small quantity of pus about the seat of injury.

This is believed to be the only case of pure dislocation of the spine below the dorsal region which is yet on record. A case

indeed in the same part of the spine as the present is reported, in a child, in Sir C. Bell's work on *Injuries of the Spine and Thigh-bone*, but it is not minutely described, and it is stated in general terms, that there was fracture. The drawing, however, does not allow of any accurate opinion being formed as to the nature of this fracture, and the preparation appears to have been sent away from London. Mr. T. Holmes, *7th of December*, 1858.

---

6. *Right Lower Limb removed by Amputation through the Thigh, two Years and three Months after Excision of the Knee-Joint.*

On the 20th of July, 1856, I removed the right knee-joint of a little boy, æt. 9, for extensive disease of the articulation which had existed for more than four years.

At the time of the operation, the child was suffering severely. The case then appeared one well suited for excision. On opening the articulation, a considerable quantity of healthy pus escaped. The synovial membrane was of a purplish hue, much increased in substance, and gelatiniform in consistence; the lateral ligaments were considerably stretched, but the crucial apparently healthy; the inter-articular cartilages were quite destroyed; the cartilage from the head of the tibia was removed at various spots, and the internal condyle deeply ulcerated.

The form of incision was one long, anterior, semilunar flap. Care was taken in reflecting this flap, to avoid turning back any of the indurated and condensed cellular tissue. About three-quarters of an inch of the condyles were removed, and the cut surfaces, excepting that they were unusually soft and preternaturally vascular, remained, to all appearance, otherwise healthy.

During some months the little patient progressed tolerably well, but there appeared to be little endeavour on the part of nature to create any kind of osseous union between the cut surfaces of the tibia and femur. After a certain time, the formation of abscesses and their persistence seemed to indicate the implication of bone structures in the inflammatory mischief, and the patient was accordingly placed under chloroform, and a searching

examination made. Small carious portions were removed from the inner margin of the upper surface of the tibia. Sometime prior to this proceeding, and also subsequently, the little fellow—the parts being firmly supported by gutta percha slpints—was enabled to get about, but again, after the lapse of a few months, abscesses continuing to form, another diligent search was made, under chloroform, to detect carious or necrosed bones. Small fragments of diseased bone were also removed on this occasion. For a time the boy seemed benefitted, and was, with the aid of a stick or crutch, enabled to take exercise. Nearly two years after the removal of the joint, constitutional symptoms of advancing scrofula set in, and it became evident, that unless the sinuses about the wound healed up, and further consolidation between the bones of the thigh and leg took place, the health would be seriously involved. A further trial of three months was willingly afforded, and all the assistance that art could render administered. At the end of this time, the health materially suffering, chloroform was administered, and the parts involved in disease carefully examined. The implication seemed too extensive for any measure short of amputation being adopted with any chance of success. The soft tissues surrounding both the tibia and femur were perforated with sinuses, which were lined with a thick, pulpy, strumous-looking material. The tibia, at its upper and inner surface was included in a carious ulceration, while there appeared to be a total failure of any reproductive action having taken place between the extremities of the bones.

The patient, in a fortnight, made a quick and excellent recovery from the operation of amputation, and is now in perfect health.

An examination of the limb immediately after removal, and before the integuments were dissected, discovered the following interesting particulars. The lower limb was considerably wasted, and apparently had not undergone the same amount of nutrition and development as its fellow. The sinuses opening upon the integuments of the leg were found ramifying for a considerable distance among the muscles, and lined with a thickened membrane. The muscular covering of the lower end of the thigh-bone was also greatly degenerated, and riddled with sinuses. On

removing the skin from off the leg, the muscles of the calf were found in a state of fatty degeneration, while the cellular tissue, about the site of the original wound, was infiltrated with indurated lymph. The connection between the ends of the bones was principally derived from consolidation of surrounding tissues. On the anterior surface of the shafts of the bones, there, however, existed some ligamentous bands, which were attached to the periosteum, but were not constituted to afford any great amount of support.

The end of the femur had undergone very considerable absorption, so that its appearance much resembled the upper end of an adult fibula. Its posterior surface was worm-eaten, and its investing periosteum was easily torn away. The extremity of the tibia was not so much altered, but its inner margin was more diseased than I had anticipated. The shafts of the two cylindrical bones were thinner than in health, and on section, their medulla bore unmistakeable evidence of scrofulous implication.

From this interesting but unsuccessful case, I would draw the following conclusions:—

The operation of excising the knee-joint seemed to be unattended with success, owing to the condition of the ends of the bones, but at the time of the operation, I was unable to discover any pathological symptom contra-indicating the proceeding I adopted. The formation of abscesses at an early period would seem to point to the premature implication of bone by disease, but the most careful search failed to detect the inclusion of either extremity. The persistence of the formation of these abscesses indicated a thoroughly strumous constitution. The subsequent impairment of bone-structure likewise pointed more strongly to the existence of this special diathesis.

The total absence of any repair, bony or ligamentous, between the cut portions of the thigh and leg-bone was both unsatisfactory and unexpected. The chief mischief, however, which existed, was centred in the soft tissues, and had I been able successfully to combat with this generally intractable affection in scrofulous constitutions, I believe, notwithstanding the inclusion of the bones in ulceration, I should have been saved the disagreeable alterna-

tive of resorting to amputation. Consolidation of adequate amount would, I have but little doubt, have taken place, at a no very distant date. Mr. PRICE, *7th of December*, 1858.

---

7. *Portions of Bones, forming the Right Elbow-joint, removed by the Operation of Excision, on Account of extensive Disease of the Articulation.*

This specimen of diseased elbow-articulation was interesting as exhibiting that form of disease known as necrosis of the joint. The patient, a lady, when 47 years of age, met with a contusion of her right elbow, which was followed with swelling, pain, and considerable inflammation. During two years, the articulation was perfectly useless, and for the latter portion of this time, the inflammatory symptoms appeared to have increased, and the joint became most seriously involved. Considerable swelling, and constant pain of a harassing description, with failing health, from night-sweats and want of sleep, demanded the assistance of art; and an examination of the joint, under chloroform, having discovered that the articulation was irretrievably destroyed, the patient willingly submitted to an operation. As the disease of the bone appeared limited to the external condyle of the humerus, although the synovial membrane was thickened, pulpy, and gelatiniform in consistence, excision of the ends of the bones seemed the correct proceeding. The operation was performed much in the usual manner, and with but slight loss of blood. In the course of five days, however, she sank. Her death was ascribed to exhaustion, as there was no evidence of any secondary inflammation of a hurtful kind.

The specimen admirably exhibited, in its fresh state, the pathological changes which takes place during the separation of diseased portions of bone from surrounding healthy structure; and also the efforts nature had made in other parts to create repair after admitting so much destruction. From an examination of the specimen, and the history of the case, I am induced to believe that the bone was the structure primarily involved, and that consequent bordering inflammation subsequently involved and destroyed the joint. Mr. PRICE, *7th of December*, 1858.

---

8. *Dislocation of the Astragalus.*

The bone was displaced obliquely, downwards, forwards, and outwards, so that the head, neck, and more than the anterior third of the body, formed a prominent tumour on the upper, outer, and back part of the tarsus. It was rolled also on itself, so that its tibial surface looked upwards and inwards. The ligaments between it and the navicular bone, the anterior ligament of the ankle joint, the middle fasciculus of the external lateral ligament, and the interosseous ligament were ruptured. The foot formed in the leg an obtuse angle, which corresponded to the point at which the inner malleolus was found impinging on the small process of the calcaneum. The tendons of the peronæi were displaced about one-third of an inch internally, as also, but to a greater extent, were those of the extensor communis, proprius posticus, and tibialis anticus; the astragalus jutting out between the two series. The tendons of the tibialis posticus, flexor longus pollicis, and flexor communis digitorum were relaxed.

The patient, a plethoric man, æt. 60, had jumped out of his chaise, and alighted with full force on his right foot. On examination, the outer border of the foot was found resting on the ground, and the nature of the injury was detected by his medical attendants. Reduction could not be effected. In three weeks the head of the bone had ulcerated through the soft parts. Gangrene of the limb threatening, amputation was performed below the knee: and the patient lived about three weeks after the operation. Mr. N. Ward, *15th of February*, 1859.

---

9. *Disease of the upper surface of the Sphenoïd Bone. Ptosis of the upper Eyelid on both sides, and complete immobility of both Eyeballs. Dysphagia and difficulty in articulating words, opening the mouth, or protruding the tongue. Loss of Muscular power in the Arms. Death by Apnœa.*

History.—The patient, a man servant, æt. 36, was admitted into St. George's Hospital. He had always been of regular habits, having on the whole enjoyed tolerable good health in general, and not being aware of any cause of his illness. He had, however,

been the subject, about seven years previously, of very severe cold, to use his own expression, attended with much headache, and purulent discharge from both ears; on being closely questioned, it seemed that since the age of seventeen, he had been on two occasions subject to *double vision*. About six months before admission, he was attacked with a dimness of sight, and afterwards he found, that on stooping, he was subject to giddiness and double sight, which ever since had been frequently troublesome, and accompanied by considerable pain in the head, specially at the back part. "Dropping of the upper eyelid" had also come on, in the first instance on the left side, subsequently on the right, and finally on both sides. The special senses had apparently not been affected, and he did not confess to having noticed interference with any form of sensibility or motor power in any of the limbs, except that often on lying down, the head was wont to fall back suddenly. For three months he had had a slight cough, and for the same period also, some *difficulty in swallowing*.

Symptoms on admission.—The patient had a strange appearance, owing to a partial ptosis of both eyelids, especially on the left side, and complete loss of power in moving the eyeballs, whose axes were parallel. Moreover, when he attempted, he could not completely close the eyelids of either side; but the mouth or face were *not* drawn to one side. The pupils were equal and regular, and responded, each, to the influence of light. Excepting from the inconvenience attendant on the ptosis and the immobility of the eyeballs, the powers of vision were entire. There was also considerable difficulty in swallowing and articulating, and after attempting to talk for a season, he soon became very tired and unintelligible, until after he had rested. He could walk well, and there appeared to be no interference with the power of moving the legs; but there was a decided diminution of voluntary power in the arms, and he could not grasp any object very firmly with either hand. There was no loss of any of the forms of tactile sensibility in any part of the surface of the body, nor was there any deafness or want of smell or taste.

He complained of pain in various parts of the head, but had never had any vomiting.

The urinary organs appeared to be in a natural condition, but the bowels were generally very costive.

Course of the disease.—He went on getting very thin and low, owing, no doubt, partly to the increase of difficulty in swallowing. He often had the appearance of choking, owing to attacks of dysphagia and difficulty in removing the thick tenacious phlegm which formed in the air passages. Dyspnœa, with unusual rapidity of pulse, came on; and eventually the whole skin assumed a *dark-blue colour*, owing to want of due aëration of blood. The difficulty of swallowing got worse, and he became unable, in almost any degree, to open the mouth or protrude the tongue, which, however, was not diverted from the straight line. Eventually, the mouth was a little drawn to the right side. No anæsthesia came on. The pupils became very sluggish, and a constant frown appeared on the forehead. The bronchial tubes all over the chest were found, on auscultation, to be clogged with thick mucus; and he died from apnœa, retaining his intellectual powers until the last. At one time his pulse was 144, and the inspirations as many as 29, per minute.

The treatment consisted of gentle salivation by blue pill, and then liq: hyd: bichl: together with counter irritants, under the impression that some chronic inflammatory action, at the base of the cranium, was going on.

Post-mortem examination.— The various abdominal and thoracic viscera were found natural, excepting that an unusual amount of redness of the bronchial mucous lining existed throughout, along with very extensive accumulation of thick mucus in the tubes.

The integuments covering the skull, as well as all the facial and upper cranial bones, were quite healthy, as also the dura mater and other investing membranes of the brain generally. The brain was carefully examined throughout, and nothing unusual was found in connection with it, excepting that an increased amount of clear fluid existed in the lateral ventricles, and in the sub-arachnoïdean tissues. There was, however, a considerable amount of opacity and thickening of the arachnoïd membrane at the base of the brain, and especially at the central part; but

nothing like indications of recent inflammatory action. After removing the dura mater, which came off rather readily, from the bones forming the base of the cranium, there was found extensive, chiefly old-standing, disease of this part of the skull.

The upper surface of the body of the sphenoïd, continuous behind with the basilar surface of the occipital bone, and in front with the sella turcica, was very vascular, and much more porous and indurated than it should be; this was so especially in the neighbourhood of the posterior clinoïd processes. Here and there (see woodcut),

WOODCUT 12.

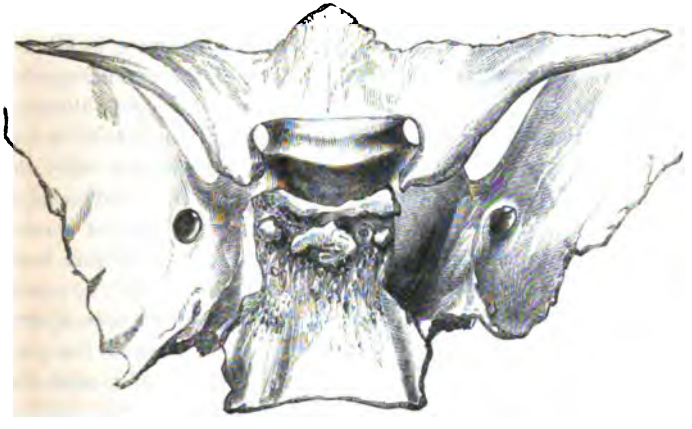

Shows the excessively porous condition of the anterior part of the square lamina of the body of the sphenoid bone; along with the hard nodules of new bone-substance, thrown out from the surface, behind the posterior clinoid processes.

small elevations or nodules of hard compact new bone existed in connection with this part of the base of the cranium.

Microscopical examination was carefully made of various parts of the brain, as also of the pneumo-gastric nerve in various parts of its course, of the locus niger and other parts of the crura cerebri, and of several of the nerves devoted to the movements of the eyeballs, but nothing worthy of remark was found in connection with them. The muscles of the eyeballs were, however, found to be almost entirely in a *fatty* condition.

Remarks.—In this case the following particulars arise as points of special interest. 1. As regards the symptoms: they are nearly all such as might be predicted under the supposition that some chronic inflammation of the cerebral membranes had been, from some cause or other, set up at the base of the brain, which had implicated in some way or other the various nerves there met with on their course to their destination. The ptosis of both upper eyelids pointed to some paralysis of the third nerve, as did the double vision, although the latter phenomenon being occasional, might, doubtless, have been owing to some spasm of the abductor muscles of the eye, by reason of irritation of the sixth.* Again, the dysphagia, the difficulty in articulating, and the dyspnœa, and other bronchitic symptoms were, in all probability, the result of some involvement of the pneumo-gastric nerves; whereas, the difficulty in protruding the tongue (although it could be moved freely about in the cavity of the mouth) would find an explanation in some inhibitory interference with the hypo-glossal nerve; and the partial paralysis of the facial muscles, in a similar interference with one of the seventh pair of nerves. As regards the difficulty in opening the mouth, that may have been owing to some spasm of the pterygoïd muscles, &c., by reason of irritation of some motor fibres of the fifth pair of nerves, or to some diminished power in the muscles, which depress the jaw. All these symptoms, conjoined with the absence of mental disturbance, the integrity of cutaneous sensibility, and the freedom from anything like hemiplegia, militated against the supposition that the central cerebral substance was itself materially involved. One symptom alone, and that is the diminished voluntary power of the muscles of the arms, was inexplicable, considering what were the changes observed on post-mortem examination. It is most likely that there existed a slight lesion of some portion of the track followed by motor fibres at the base of the brain, which in the examination, I overlooked; or again, that the condition of the cerebral arachnoïd which prevailed at the base of the brain, extended to some extent downwards into the spinal cavity, so as to compromise the motor root of some of the upper spinal nerves.

* In connection with the ptosis and the fixedness of the eyeballs, it must be remembered that the oculo-motor nerve has a special notch for its passage at the lateral border of the plate of the sphenoid bone, which was diseased.

I will take the present opportunity of stating, that medical men are, as it appears to me, in the habit of attributing implication of nerves, which often exists as a result of inflammatory processes, such as were present in this case, too exclusively to mere external *compression* by inflammatory exudation. That pressure is a very frequent, and perhaps the most common cause of inflammation of nerves found coursing along in the very neighbourhood of inflammatory action—I allow; but still I think that there can be no doubt, that surrounding inflammatory action frequently embarrasses the nerves by directly and substantially extending to them; thus they become more or less disintegrated, hardened or softened, losing all conducting power. Or, on the other hand, their action may be increased, especially in the first instance, and spasm of the muscles, to which they are delegated, excited. This *spasm or excess of action* during life is often confounded with supposed *loss or diminution of power* of the counterbalancing muscles.

2. The peculiar porous, hardened, and roughened conditions of the part of the sphenoïd bone affected, and upon which the chronic inflammatory condition of the adjacent arachnoïd membrane depended, is a subject of interest. This was not made out to be either of syphilitic or strumous origin; the details of the life, the history, &c., seem to point out that it was of rheumatic origin; and I am inclined to compare the roughened prominences of hard bone which existed at the affected part with such new formations of bone as are not infrequently met with in the neighbourhood of joints in other places in old rheumatic subjects. Dr. John W. Ogle, *2nd of March*, 1859.

---

10. *Old Disease of the Knee-joint repaired.*

This specimen was removed from a patient admitted into Guy's Hospital in a dying condition from some bronchial affection, and from whom no history could be obtained; after death, a complete transposition of all the viscera was seen, and the knee-joint was also observed to have been formerly diseased.

The leg was of equal length with the sound one, but the knee-joint appeared much smaller in every way; there was good flexion and extension of the diseased limb, and evident appearance of old suppuration.

Upon examining the joint, all signs of cartilage had disappeared, its place being supplied with a firm smooth fibrinous material; this covered the whole of the articulating surfaces of the bones, which had evidently been exposed and roughened from the loss of their articular lamellæ, and had been repaired by this new product; and on making a section of the bones they were in parts found to be denser than natural, as if from the organization of old inflammatory material. Upon a microscopical examination of the new fibrinous deposit within the joint, it was seen to be composed of fibre-tissue with nucleated fibres; in one spot some fibro-cartilage was seen. On the whole, the evidence of old disease, probably in childhood, was very clear; the development of the joint had been interfered with as shown by its small size, and the joint had been disorganized as indicated by the loss of the cartilages and appearances of the bone: this specimen, like the following, well displays the success with which nature repairs a diseased joint.

Mr. T. Bryant, 19*th of April*, 1859.

---

11. *Disease of the Hip-joint of fifty years' duration.*

A woman æt. 57, was admitted into Guy's Hospital under my care with strangulated umbilical hernia for which she was operated upon, and died. She had had hip disease upon the right side for fifty years, the joint suppurated and discharged for three years, when the sinus healed, leaving the leg shorter than the other; she, however, gradually regained the use of the limb, and although shorter it never caused her any subsequent inconvenience; there was good flexion and rotation, and it was purely by accident that the old disease was discovered.

Upon examining the joint, all signs of the head or neck of the femur had disappeared. The acetabulum was lost, and in its place much new bone had been deposited. The extremity of the femur was rounded off, and its inner surface was somewhat flattened, corresponding to a flattened surface upon the side of the acetabulum; the whole was firmly connected to the pelvis with firm fibrinous material, allowing good mobility. It was this firm fibrinous structure upon which the patient must have rested when standing upon the limb, and the specimen is an

admirable one, showing what nature can do in repairing disorganizing disease of an articulation.

Mr. T. BRYANT, 19*th of April*, 1859.

---

12. *Right Knee-joint removed by Excision on account of Deformity from old-standing disease.*

This specimen consisted of the bony structures forming the articulation of the right knee in a girl, æt. 13, who had been the subject of disease of the lower end of the femur for between five and six years. The deformity of the lower limb was such as to require some prompt interference. The tibia was dislocated behind the condyles of the femur, and rotated somewhat outwards. The patella had slipped between the condyles, and was firmly held in its new position. The ham-string tendons were contracted, but the chief band of retention appeared to be consolidated tissues, and contracted ligaments.

The lower end of the femur and the integuments, bore traces of former very extensive mischief, while there still remained evidences of existing disease. An attempt (the patient being under the influence of chloroform) was made to straighten the limb, but to no purpose. Divisions of all the ham-string tendons, and such parts as offered resistance, failed to allow any definite hope of the deformity being remedied without removal of the the joint. On removing a portion of the lower end of the femur, I found that reparation to a considerable extent had taken place. There existed a cavity about half-an-inch in circumference, and two inches in length, filled with a nucleated blastema in which vessels were already developed. The bone immediately circumscribing this cavity, was more compact and harder than the general structure. It is probable the cause of destruction arose from the development of an abscess in the cancellous tissue, which had discharged itself into the soft parts by perforating through the shaft of the bone. The remaining osseous structure both of the femur and tibia appeared perfectly healthy. The joint had undergone but slight alteration, the synovial membrane alone being somewhat modified in appearance. The specimens admirably illustrated one form of separation which ensues after

inflammation and destruction have invaded the open structure of cylindrical bones. Mr. PRICE, *19th of April*, 1859.

---

13. *Portions of Bones forming the Left Knee-joint removed by the operation of Excision on account of accident; also the False joint which resulted.*

This specimen consisted of the bony structures immediately forming the left knee articulation, and exhibited features of interest. A boy, æt. 8, in the month of August last, when alighting from a cart, slipped, and his foot becoming entangled between the spokes of one of the wheels he fell to the ground. The left knee was the part principally involved in the accident. On examination at Charing Cross Hospital, Mr Canton found that the lower end of the femur had been forcibly torn from the shaft in the line of the epiphysis. Considerable bruising of the soft tissues somewhat complicated the injury, but the parts were adequately adjusted in the hope that union would take place. In the course of a few days, suppuration, sloughing, and severe constitutional disturbance necessitated the adoption of some definite operation. Excision of the entire joint was preferred to amputation of the limb above the seat of mischief. This proceeding was followed with very considerable benefit, the parts rapidly healed, and the child recovered his usual health and spirits. The union of the soft tissues was perfect, but the junction between the cut surfaces of the tibia and femur was not of a nature to admit of any great degree of utility; the material was of a fibrinous character, and permitted very considerable motion of the new joint, so much so indeed, that the limb assumed a similitude to the free end of a flail.

The parents anxious that their son should without further delay resume his employment, desired removal of the limb, which was effected through the lower third.

The features of interest connected with the specimen are:—

1. The pecularity of the accident. 2. The nature of the union which resulted between the cut extremities of the bones. Bony junction in young children, especially when the ossifying surfaces have been removed, does not by any means, frequently

occur as an immediate result of excision of the joint. The union in this case, might probably have eventually served as a useful bond of junction, but time was not allowed for sufficient consolidation and adaptation of the parts to the office for which they were intended. Absorption to some considerable extent had altered the shape of the upper portion of each bone. The amount of tissue generated between the bones during so short a time, five months, showed the efforts nature had made to constitute efficient reparation. Mr. PRICE *for* Mr. CANTON, 19*th of April*, 1859.

---

14. *Large Cavity in the Head of the Tibia, not that of an Abscess. Query, Hydatid?*

A man, æt. 33, occupied as grocer's porter, applied in October, 1857, to Mr. Hearne of Southampton, with dull aching pain in the situation of the head of the right tibia. General health always rather delicate. There was no alteration in the external appearance of the limb and he was treated by mild mercurials and iodine.

After five or six months, a circumscribed swelling was seen about an inch below the tuberosity of the tibia, the size of half a hen's egg; it was fluctuating. A trocar was introduced, and a little straw-coloured serum, but no pus, came away. In July, 1858, a free opening was made, and serous fluid again issued; a probe now passed through the opening traversed the head of the bone to the popliteal space. Still there was no thickening of the surrounding tissues. However, inflammation and suppuration now ensued, and hæmorrhage took place from the interior of the bone two or three times during the next few days, with severe constitutional symptoms, so that in the course of about three weeks it was necessary to amputate the limb, which was done through the lower third of the femur. He made a good recovery.

Condition of the bone.—The part exhibited was the upper fifth of the right tibia. The head was completely hollow, the bone forming a thin case, in places no thicker than paper; nevertheless, there seemed to be no enlargement or dilatation of the bone.

Mr. HENRY THOMPSON *for*
Mr. E. HEARNE, *of Southampton*, 19*th of April*, 1859.

---

15. *Spontaneous Fracture of both Bones of the Leg, following extensive Ulceration from Epithelioma.*

Mr. S., æt. 69, had been subject to a chronic ulcer of the right leg for fifty years, which had been caused by injury in the first instance. During this time it had been alternately open and closed for months at a time; but the part was perfectly healed five years ago. Soon after this the wound opened again, and became so large and painful, that the patient was confined to his bed, where he had remained for the last two years and a-quarter.

On Sunday evening, the 5th of December, 1858, while seated in bed dressing the limb, which was extended (not resting on any support) before him, it suddenly snapped at the site of the ulcer, and the lower half, that is all below mid-leg, fell towards the bed, the bones having evidently given way. He immediately sent for Dr. Madge, who had seen him several months previously, but not lately, and who, after examining the limb, and believing amputation would be necessary, sent for me.

On ascertaining the state of the parts I advised amputation, immediately below the knee-joint, and performed it at once. From the ulceration of the skin extending very high, it was not possible to make any anterior flap, but a large posterior one was obtained from the calf, which amply covered the bones.

On examination afterwards, the tibia and fibula were found considerably necrosed; the latter bone had evidently been divided for some time, and portions of it had come away; the tibia only had given way at the time, being no longer able to support the weight of the foot when the limb was raised in a horizontal position. Under the microscope the soft parts exhibited the elements of epithelial deposit—numerous brood cells as well as large quantities of flattened and spheroïdal epithelium infiltrated the tissues implicated in the ulceration.

Mr. Henry Thompson, *7th of December*, 1858.

Continued history of the patient.—The wound slowly healed, and the patient appeared to be doing well during the eight or ten weeks subsequent to the operation. At one point of the cicatrix a sprouting granulation then appeared, which soon

increased, and became excessively painful, so that in April, it was quite clear that a return of the disease had occurred in the stump. Under these circumstances, I advised an amputation above the knee-joint, and performed it by the circular method to avoid near approach to the seat of disease, and the patient is now making an excellent recovery. There was no trace of glandular affection in the groin.

Examining the parts removed, the seat of the fresh outbreak of the disease was observed to be the head of the tibia, and this afforded abundance of the elements significant of epithelial deposit.—19*th of April*, 1859.

---

16. *Secondary Cancer of the Femur, followed by spontaneous Fracture.*

A. W., æt. 48, was admitted into the Middlesex Hospital, on the 28th of July, 1857, suffering from cancer of the right breast of three months' duration. The disease was removed by caustic, and she left on the 10th of November, 1857. She was reädmitted on the 1st of June, 1858, complaining of pain in the cicatrix, where there was an open sore; a few small hard subcutaneous nodules were found in the vicinity. The disease made no apparent progress, but early in April, 1859, sudden and unaccountable prostration set in, and on April 27th, she died, apparently from exhaustion. Two days before death, a swelling on the external aspect of the right thigh was noticed by the sister of the ward.

Post-mortem examination.—The swelling proved to be owing to a fracture of the femur in its upper third. There were no bruises or marks of injury on the integuments, but the surrounding muscles were lacerated and sloughing.

The vertical sections of the bone exhibited, illustrate three of the principal modes in which osseous structures are affected by cancer. At the point of fracture, the inner part of the shaft has been softened, absorbed, and replaced by cancerous growths, while the cortical shell remains unaffected; thus occasioning the peculiar brittleness which disposes to spontaneous fracture (osteopsathyrosis). Above, the cancellous structure of the head of the bone is simply infiltrated with a white creamy juice; below, about one

inch and a-half from the seat of fracture, a distinct growth one inch long by a-quarter of an inch thick, projects into the medullary cavity. This (growing doubtless from the endosteum) consists of a stroma partly osseous (formed of new bone with colossal Haversian canals), partly areolar, and containing innumerable nuclei with large distinct nucleoli, a few nucleated cells, many compound granulation corpuscles, and much free fat.

No cancerous growths were found in any part of the body, except in the before-mentioned subcutaneous nodules and in the ovaries. Dr. Coote, 17*th of May*, 1859.

VII.—DISEASES, ETC., OF THE ORGANS OF SPECIAL SENSE.

1. *Fracture of the Handle of the Malleus of the Ear.*

Fracture of the small bones of the ear appears to be extremely rare; I have not hitherto found any case of the kind on record, nor have I, previously to the present instance, met with a specimen in the course of my dissections.

In the preparation, the fracture was found to be just above the processus brevis (Woodcut 13), where the handle or processus longus joins the body of the bone, and where the tubular tensor tympani ligament is attached internally. This ligament, has also been split into an upper portion, which remains attached to the body of the bone, and a lower portion which is attached to the handle. The head of the bone is drawn inwards, and lies in contact with the inner wall of the tympanum, while the handle lies more externally, its upper fractured extremity being quite free. Upon examination, by means of a magnifying glass, the upper fractured extremity of the handle of the malleus was seen to be somewhat convex and perfectly smooth, having no appearance of being produced by a post-mortem injury; its posterior surface looked towards the body of the bone, on the anterior and outer part of which was seen a flattened surface against which the posterior part of the upper extremity of the handle seemed to have played during life. The possible mode in

which the malleus may be fractured is shown by a recent case at St. Mary's Hospital, where the wire of the pendulum of a clock

WOODCUT 13.

Represents the fractured malleus *in situ*. *a*. As seen magnified.

was forced into the ear with great violence, rupturing the membrana tympani, and striking against the malleus.

Mr. JOSEPH TOYNBEE, 19*th of April*, 1859.

VIII.—TUMOURS, CYSTS, INCLUDING HYDATIDS, ETC.

1. *Tumour of the Upper End of the Tibia, containing numerous Myeloïd Bodies.*

A. B., æt. 68, admitted into the Marylebone Infirmary on the 1st of June, 1858, with swelling apparently involving the left knee-joint or the part immediately below it.

Two years before this date, she first observed that this knee was a little stiff; but during the succeeding twelve months, not much alteration took place, the slight stiffness continuing.

About October, 1857, the stiffness increased a little, there was some pain, and she walked with a slight limp. She continued her active duties as nurse in the convalescent ward at the work-

house until Christmas last, at which time she first perceived some swelling near the knee.

In January, 1858, five months before admission, she first applied to a medical man, the resident officer, to see it; but it was not until the end of the month that the symptoms appeared to be sufficiently marked to require rest. Accordingly, she relinquished her nursing duties at this time.

During the past four months, it has been increasingly painful, and the swelling has become considerable.

In the beginning of June, I first saw her, on her admission to the Infirmary. A defined swelling occupied the situation of the head of the left tibia, and was most prominent on the outer side. The circumference here exceeded that of the sound limb by an inch and three-quarters. The movements of the knee-joint appeared to be limited only by the proximity of a tumour; there was no effusion into the joint itself, but intense pain was caused by any movement. The patient lost sleep from the severity of the pain. There was no alteration in the colour of the integuments.

On careful manipulation, I found two limited points at which fluctuation was evident, elsewhere the tumour appeared to be solid. Into each of these I introduced a small exploring trochar, and from one there issued three drachms of a straw-coloured fluid; from the other blood flowed very freely, and it was necessary to apply a bandage firmly to stop the bleeding from both openings. No glandular enlargement was discovered in the course of the lymphatics above the tumour.

Taking into consideration the rapidity of the growth, the pain, and the result of these punctures, I advised amputation, and performed it through the lower third of the femur, on the 26th of June.

During the first three days after the operation, she progressed well, and everything looked promising; she then became very weak, and died, apparently of exhaustion, soon afterwards.

Condition of the Leg.—On making section, the upper fourth of the tibia is seen to be replaced by a party-coloured and vascular tumour of very soft consistence. The tints are mainly buff or pale yellow, and deep red; the latter portions resemble blood

coagula in appearance, and some of these are limited by fibrous capsules, as if hæmorrhage had taken place into cysts previously formed. The periphery of the diseased mass is well defined by a fibrous envelope, which limits it in every direction. In this, a very thin layer of bone is found at the inner and outer aspect of the tumour; and over that part which borders upon the joint, a thin layer of cartilage, corresponding with the head of the tibia, only intervenes between articulation and the diseased structure. There is no sign of inflammatory action within the joint, although a small portion of cartilage has disappeared from the condyles of the femur.

Under the microscope, the soft yellowish masses which chiefly compose the growth, appear to consist mainly of small, slightly oval cells, varying between the $\frac{1}{2500}$ and $\frac{1}{2000}$th of an inch in diameter; each containing a very distinct nucleus. The greater part are free in the field, while clusters of others were enclosed in envelopes of ovoïd form, which presented objects having about the same size as small tesselated epithelium, each containing as many as thirty or forty closely-packed cells. There were also seen a few softish-looking fibres some of which were nucleated; in no part of the tumour did the fibres appear to predominate, but they were always found in much smaller proportion than the cell element. Besides the structures described, there were some granular matters, and some fatty-looking globules intermingled throughout. The red masses were composed chiefly of blood globules.

This is, I believe, the first case on record of a tumour of this description occurring at an advanced age, sixty-eight years. Generally, judging from data furnished by sixteen cases, they occur between eighteen and thirty-six years. The only exceptions to this rule observed prior to the case before us, are, one exhibited by Mr. Hutchinson to the Society last session, aged forty-three; and a case observed by Mr. Gray, referred to as exceptional in regard of age, in his well known paper on the subject in the *Medical and Chirurgical Transactions* for the year 1856, described as occurring in a female of middle age.

Mr. Henry Thompson, *2nd of November*, 1858.

---

2. *Cancerous Tumour of the Mediastinum involving and obstructing the Superior Vena Cava.*

F. S., æt. 20, a compositor, enjoyed good health up to the 24th of May, 1858, but on that day he went to row on the river Lee, exerted himself considerably, and got wet. A few day after this, he suffered from pain in his back, near the right shoulder blade, and also in front of the right nipple, which symptom lasted for a week, and then disappeared. On the 3rd of July, his face, neck, arms, and upper part of his chest began to swell; and he suffered from giddiness and lividity of the countenance upon making any exertion, these symptoms being sometimes accompanied by headache and great nausea. He also complained of a sensation of choking, as if his gullet was blocked up by some foreign substanc; this last symptom disappeared after three or four days. The swelling and other symptoms, however, continued to increase up to the date of his admission into King's College Hospital, on the 14th of July.

On his admission, there was observed to be considerable puffy swelling of the face, neck, arms, and upper part of the thorax. The abdomen and lower extremities were quite unaffected. The veins on the surface of the chest appeared enlarged and very tortuous, and the superficial epigastric veins were also enlarged, but straight. The superficial veins of the arms were also very prominent. He complained of numbness and coldness of the hands, which as well as the face, were of a livid hue. Careful auscultation and percussion of the lungs oft-times repeated, revealed nothing abnormal. The heart's-sounds were feeble, but no abnormal murmur could be heard over this organ, or in any part of the chest. Pulse 75; respirations 18; tongue clean; bowels regular; general appearance healthy; no emaciation.

It was obvious that there was some obstruction to the flow of blood through the descending vena cava; but doubts were entertained as to the precise nature of the obstructing body—whether this might be a small deep-seated aneurysm, a cancerous growth, or a cluster of enlarged glands. On the last supposition, the the patient was treated with large doses of iodide of potassium. He remained in the Hospital till the 7th of August; by this time, the swelling in the upper part of his body had almost completely

disappeared; and he felt himself better in every way, yet the superficial veins of the trunk appeared more prominent than before, and those on the thorax more tortuous.

On the 25th of September, he was reädmitted. The swelling had not returned, but the superficial veins had, if anything, increased in size. He now suffered from great dyspnœa, which prevented his assuming the recumbent posture. He had also a peculiar spasmodic cough coming on in paroxysms, and followed by frothy expectoration, and his voice was hoarse and husky—scarcely more than a whisper; physical examination of the chest now yielded marked indications of disease. In the right infra-clavicular region, over a space extending from the middle line of the sternum, three inches to the right, and from the clavicle nearly four inches downwards, there was marked dulness on percussion. There was no bulging over this space, nor was there any pulsation to be felt. On auscultation no bruit could be heard, but there was almost complete absence of vesicular breathing and great diminution of vocal thrill, coarse mucous râles were audible over the whole of the right lung, but not at all over the left; the heart's-sounds were normal; the pulse at either wrist was of equal force, and the pupils were equally dilated.

From this date the patient rapidly got worse. He had frequent and violent fits of dyspnœa attended with lividity of the face; his cough was very troublesome, and on one occasion some specks of blood were observed in the expectoration, which, however, was very scanty at all times; he also suffered from obstinate vomiting; he completely lost his voice; the dulness over the apex of the right lung was observed to extend, and during the last fortnight of life there was considerable emaciation. At six A.M. of the 23rd of October, an attack of dyspnœa came on, which continued till death, three hours and a-half later.

Post-mortem examination.—A tumour was found in the upper part of the right side of the chest, corresponding to the region of dulness which had been observed during life. It measured four inches from above downwards, two inches and a-half transversely, and three inches from before backwards. It presented an uneven nodulated surface, and was of very dense consistence. Its cut surface was of a greyish-white colour; and there exuded

from it a small quantity of milky juice. On microscopic examination, the juice exhibited numerous large, naked nuclei, and a few nucleated cells, similar to those ordinarily found in cancerous growths. The tumour was situated for the most part in the anterior mediastinum, immediately above the sternum and right costal cartilages, but it also encroached considerably into the substance of the right lung, with which it was inseparably united. The terminations of both the innominate veins, and the entire length of the superior vena cava, were involved in this mass. The last vessel was almost completely obstructed, barely allowing a crow-quill to pass along. The morbid deposit also extended along the coats of this vessel, and within the cavity of the pericardium, as far as the wall of the right auricle. The termination of the vena azygos was involved and lost in the tumour, and the trunk of this vessel was much enlarged, and so distended with a thick black coagulum of blood, as to resemble a rounded cord. The intercostal veins were in a similar condition. The tumour rested on the upper surface of the arch of the aorta; but the coats of this vessel were intact. The innominate artery, however, and the origin of the right carotid and subclavian, passed through the centre of the mass, as did likewise the right pneumogastric and both the recurrent nerves. The left pneumogastric nerve, and the left carotid and subclavian arteries, passed free to the left. The pulmonary veins were not involved; but the right pulmonary artery was surrounded on all sides by morbid deposit, and much constricted.

The right lung was universally and firmly adherent to the costal pleura. It was non-crepitant throughout, and its tissues were infiltrated with thick purulent fluid. Here and there were several small cavities, the size of peas or hazel-nuts, containing thick creamy pus. There did not appear to be any cancerous infiltration through the lung. The left lung was non-adherent and healthy. Two nodules of the tumour projected backwards into the air passages, forming prominences of about the size of French beans. One of these was situated at the lower end of the trachea, the other at the commencement of the right bronchus. The result was, that the passage through the bronchus was well-nigh obstructed. The rima glottidis was normal.

The pericardium contained several ounces of clear fluid. The heart was extremely small; its muscular substance and valves were healthy.

The inferior vena cava appeared to be much dilated, as were also all the veins of the abdomen, belonging to both the portal and the general circulation.

The abdominal organs generally were much congested; but there was no cancerous deposit elsewhere than what has been above described. Dr. MURCHISON, *2nd of November*, 1858.

---

3. *Hydatid developed beneath the Fascia and short Head of the Biceps Femoris, removed entire.*

Removed from a female patient of Mr. Cock's in Guy's Hospital, æt. 24. The tumour had been growing for about two years, and when admitted into the Hospital it was of about the size of an adult fist; when the integument and fascia were divided, the hydatid rolled out; there were, however, several other small ones about the size of peas, but upon examining these no echinococci could be found. The patient rapidly recovered.

Mr. THOMAS BRYANT, *16th of November*, 1858.

---

4. *Erectile Tumour of the Leg.*

This specimen presented a flattened mass of erectile tissue, of a circular form, which at the time of its removal measured two inches and a-half in diameter, and was situated on the outer side of the leg, and at the lower end of the upper third of the tibia. The only peculiarity of this tumour is its having been fed entirely by the vessels of the cutis. With the view of removing the tumour by ligature, a conical incision was made, surrounding, however, a small portion of the skin about half-an-inch in diameter, in which enlarged veins were very superficial. When the flaps were dissected back, the tumour was found to be attached only by a little loose areolar tissue, and the knife was hardly required for its removal. Mr. BROOKE, *21st of December*, 1858.

---

5. *Myeloïd Tumour of the Fibula, with Secondary Growths in the Lungs.*

D. R., æt. 30, was first admitted under Mr. Cock into Guy's Hospital, in September, 1854. He was a farm-labourer, and had always enjoyed good health until seven months before, when he perceived a lump growing on the outside of the left knee. He had had no blow nor could he ascribe its occurrence to any cause. It gradually increased, and during the last three weeks, he had been unable to walk, from pain in the leg. On admission he appeared to be in perfect health, but on the outer side of the left knee and extending back into the popliteal space was a tumour; this was punctured, but nothing but blood was evacuated. On the 7th of October, the limb was amputated above the knee, and on a section being made the tumour was found to be a well-marked myeloïd one developed in the head of the fibula. It was round, measuring four inches and a-half in diameter, and consisted of a fibrous capsule continuous with the periosteum, which formed the bulk of its circumference; the cartilage completed it on the side of the knee-joint which was quite healthy, and at the lower part the fibula ended abruptly by a jagged edge in the midst of the tumour. The interior was of a dark-red colour resembling a spleen, was composed of a fibrous matrix, which contained within its meshes the peculiar red myeloïd matter, and which under the microscope, displayed the characteristic poly-nucleated branching cells. The stump healed, and the man left the Hospital perfectly well, to resume his agricultural employment.

On inquiries being made from time to time, it was learned that the man's health was excellent, when about two years afterwards, on the 20th of October, 1858, he again came to the Hospital, with some tumours on the stump. He stated that he was in perfect health, as he apppeared to be, but about a fortnight previously, he accidently discovered these lumps on his thigh. There was one about the size of the closed fist on the inner side, and two smaller ones on the outer side. The latter were removed by Mr. Cock, and found to resemble in every respect the original myeloïd tumour, except in the fibrous matrix; the colour was red and composed wholly of myeloïd matter; a part of the containing cyst was

ossifying. When the wound was healed, on the 23rd of November the large one was removed, and this, like the others, consisted of a thick-walled sac in part bony, and containing myeloïd matter, in the midst of which were a few sanguineous cysts. This tumour was close to the bone, but did not actually touch it. The man died three days afterwards of acute pleurisy, when, most unexpectedly, similar myeloïd tumours were found growing from the lungs. They, on section, presented the well-marked characteristic hue, and resembled the other tumours; each lung contained three or four, one being as large as the heart. Their mode of growth was peculiar in not infiltrating the texture like cancer, for they grew from the circumference of the lung, and were pendulous, and probably would have been pedunculated, if not developed in a confined space; their shape was also peculiar in being polygonal, having flat surfaces like the lung itself, and thus indeed they looked like supernumerary lobes. The surfaces of the organs contained a few very minute deposits of the same. All the other organs were healthy, and the lymphatic glands were quite unaffected.

As the various forms of tumours are not yet accurately defined, and opinions vary as to what constitutes a myeloïd tumour, so the interest attaching to this case will vary. If the mere discovery of some myeloïd cells by the microscope be not sufficient to give this distinctive name to a new growth, but a peculiar mode of formation as a gradual increase from the centre of a bone and not a mere out-growth, and having certain naked eye appearances which liken it to a spleen, and render it at once recognizable, then probably this is the first case recorded of a pure and simple myeloïd tumour that has recurred after removal.

Dr. Wilks, 21*st of December*, 1858.

---

6. *Lobular Fibrous Tumour of the Scrotum.*

This tumour was removed from the scrotum of a gentleman, æt. 51. It had formed very slowly, having been first observed about twenty-four years ago. In 1835, the patient consulted Mr. Aston Key. At that time the tumour was very small, and Mr. Key called the swelling a varicocele, and regarded it as of no

consequence. The tumour was very prominent in front of the left spermatic cord, just above the testicle, which was somewhat depressed. The surface of the tumour was very irregular and uneven, and it had the firmness and density of cartilage. It was connected with the spermatic cord, but was quite distinct from the testicle. It was the seat of very little tenderness or pain.

The tumour, with a portion of the skin closely investing it in front, was excised on the 9th of January. Its back part was attached to the sheath of the spermatic cord, but none of the structures of this part were exposed in the operation. Care was taken to excise every lobule, and portion of the tumour. The patient recovered favourably from the operation.

The tumour was of about the size of a small orange, but of an oval shape. It was composed of a large number of small lobules of various sizes, each lobule having a distinct capsule. The lobules were somewhat loosely connected by fibro-cellular tissue.

Dr. Andrew Clark examined a portion microscopically, and reported that it consisted of white fibrous and fibroïd tissue, blood-vessels of recent formation, and elongated nuclei interspersed with much moleculo-granular matter, and infiltrated with albumen and fat. He also observed a stroma, resembling the matrix in which cartilage is formed.

Mr. Curling, 18*th of January*, 1859.

---

7. *Fibro-Plastic and Myeloïd Tumour of the Femur.*

The specimen consisted of a tumour involving the lower end of the femur. Amputation had been performed by Mr. Simon, at St. Thomas's Hospital, on Saturday, the 8th of January. The patient was a girl, æt. 17. She had been to the West Indies, and attributed the disease to frequent blows received during the voyage from the rolling of the vessel. Her symptoms commenced about the beginning of last May. At first she felt only stiffness of the knee-joint on rising in the morning, which stiffness subsided during the day; soon, however, this stiffness increased, and was accompanied with pain. An increase of size was first noticed in June; this rapidly advanced, and she was occasionally

subject to attacks of severe pain, extending down the leg. The circumference of the lower end of the femur at the time of operation, was between two and three times its natural size. On examination of the tumour after removal, the surface was somewhat nodulated; as a rule, its structure was very dense, but occasional fluctuating points might be detected. The dense portions had an opaque white colour, and, to the naked eye somewhat resembled cartilage; the fluctuating points were mottled, and when cut into, showed a number of cysts of variable size, the contents of which were a dark-coloured, bloody-looking fluid. On a vertical section being made of the femur and tibia, it was seen that the former was involved in a large tumour, which extended five or six inches above the condyles. The synovial cavity was also entirely occupied by the growth which filled the space between the articulating surfaces of the femur and tibia. The latter bone, however, was not in the least involved, the cartilages covering its head as well as the semilunar cartilages remaining intact. The cartilage of the femur was also perfect. The growth evidently commenced in the cancellated structure of the condyles, and having burst through the cortex, extended upwards and downwards on the exterior of the shaft. In the section were seen a soft pultaceous material, numerous cysts, an abundance of bony structure, and a rather dense fibrous-looking substance. The soft pultaceous material and the tissue in the neighbourhood of the cysts showed an abundance of myeloïd cells; the fibrous-looking substance was made up specially of fibro-plastic, with occasional myeloïd, cells. The tumour was a compound one, combining the characters of myeloïd and fibro-plastic.

SYDNEY JONES, M.B., 18*th of January*, 1859.

---

8. *Sequel to a Case of Myeloïd Disease of the Humerus.*

An account of this case has already been given by Dr. Bristowe, in the ninth volume of the "Pathological Society's Transactions." Amputation at the shoulder-joint, by Mr. Simon, was performed on the 25th of June, 1853, and the patient died of phthisis, on the 11th of June, 1858. The stump was quite healthy. On *post-mortem examination*, the lungs were found

studded throughout with tubercle; a cavity existed in the apex of each lung—large in the left, and capable of holding a small orange; smaller in the right, and capable of holding a walnut. Besides these, there were several smaller cavities, varying in size from that of a pea to that of a filbert. There was very little crepitant tissue; that intervening between the masses of tubercle being solidified by pneumonic and tubercular infiltration. Under the microscope, the tubercle was found made up of an amorphous granular material, such as ordinarily composes yellow tubercle. Nothing at all resembling myeloïd structure was found. The liver, spleen, kidneys, and supra-renal capsules were waxy. On examination of the intestines, small white spots were seen studding the lining membrane, each of about the size of a pin's-head; they consisted of the solitary glands infiltrated with tubercle; at some points ulceration of these glands had occurred, causing a small shallow ulcer, varying in diameter from two to six lines. The other organs were perfectly healthy.

SYDNEY JONES, M.B., 18*th of January*, 1859.

---

9. *Mass of Hypertrophied Lymphatic Glands, removed from the Axillary Space.*

The specimen was removed by operation from the right axillary space, of an otherwise healthy-looking boy, between three and four years of age.

Before its removal, the mass presented, on manipulation, a slightly irregular, softish, rather elastic, tolerably moveable, prominent swelling, filling the axillary space, and extending forwards under the pectoral muscle, and backwards under the latissimus dorsi muscle, covered by a considerable quantity of sub-cutaneous adipose tissue; there was no appearance of inflammatory action, past or present, about the swelling, and the skin over it was healthy.

After its excision, it was found to consist of an aggregation of lymphatic glands, about twenty in number, varying in size from that of a pea to that of a walnut, somewhat loosely connected together by areolar tissue, blood-vessels, and lymphatic vessels; on section, each gland presented an homogeneous surface, of a pinkish-yellow

colour, of uniform, moderately firm consistence, without any appearance of tuberculous deposit.

Mr. Hillman considered the case interesting.

1. On account of the difficulty of ascertaining the exact nature of the tumour before its removal.

2. As affording an opportunity of examining in the recent state, the condition of the glands usually described as "strumous."

3. As showing that such a mass may be removed by operation with a satisfactory result.

Mr. HILLMAN, 1*st of February*, 1859.

---

10. *Malignant Tumour of the Humerus.*

The patient was a man æt. 31, who was admitted on the 16th of February, 1859, under the care of Mr. Henry Charles Johnson, into St. George's Hospital, on account of a tumour of the right arm, which had been preceded by a fracture in the same spot, from muscular effort, in aiming a blow with a stick, which missed its aim. The fracture had been preceded, for about three weeks, by rheumatic pain in the part. The tumour appeared about two months afterwards, and grew gradually. On his admission it was of an oval shape, about as large as a good-sized melon, extending from the junction of the upper and middle third of the arm to within two inches of the elbow-joint. The bone above it appeared enlarged and hardened. He had been losing flesh and strength of late. The tumour was judged to be malignant, and the limb amputated at the shoulder joint. The patient made a good recovery, and left the Hospital much improved in health, in about six weeks.

The specimen exhibited was a longitudinal section of the diseased bone. It had given way, in the sawing, just below the tumour.

The latter was of large size, round, with a cyst of some size in the middle. It was sessile on the outer surface of the bone; the medullary cavity of which was closed by a soft deposit for some distance above it. The compact tissue was much thickened above, but below the tumour, where it had given way, it was very thin. The tumour showed in many places well-marked cancer-cells;

in others, it had undergone a process of fatty degeneration. In the deposit which occupied the shaft, only fibrous elements were discovered.

The specimen was exhibited principally with a view to record the progress of the case, should the disease unfortunately recur, and the patient (as would most likely be the case) be still under observation. Mr. T. Holmes, *2nd of March*, 1859.

---

11. *Cartilaginous Tumour of the Skull and Face.*

This preparation was taken from the body of a young woman, E. L., æt. 28, at the time of her death. She had been for the greater part of two years in St. George's Hospital, as a patient of Mr. Cæsar Hawkins, and was originally admitted on the 23rd of August, 1848. She was a domestic servant, and was said to have enjoyed good health: she was fair, delicate, and thin. At that time, both eyes were pushed forwards and outwards by soft elastic tumours in the orbits, which were visible on the inside of each eye, and could hardly be felt, except at the inner half of the orbit. The disease had commenced in the right orbit about two years and a-half, and in the left about one year, before admission. The tumours consisted of several small portions attached to, and elevating the skin, and of a whitish colour; one at the inner canthus of the right eye was ulcerated. The nose was not altered in shape externally, but there was some pain referred to the bridge of the nose; and the right nostril had bled and discharged occasionally. The probe did not pass along it so readily as on the other side; there was no sense of smell in either nostril. The right maxillary bone was fuller below the orbit than the left, and the right half of the bony palate was larger and more depressed than the other, but in neither of these parts was there any softening. There was pain and numbness of the right cheek and lip, and a little pain on either side of the forehead. There was epiphora of both eyes. Vision was weak; but single, and otherwise perfect. The motion of the eyeballs were perfect, and the pupils natural. There was no giddiness or headache. On the 11th of September, however, she complained for the first time of occasional attacks of giddiness, and said that she lost the sight of both eyes for

a few minutes every day. The tumour was seen to be increasing slowly in size, and a small abscess formed over it on the left side. She improved somewhat in health under the use of sarsaparilla and iodide of potassium, but during the month of November complained much of pain in the head and intolerance of light and sound; and on the 15th of December, had a slight convulsive attack. She remained in the Hospital without any particular alteration for several months, but in March, 1849, the sight of the left eye began to be much affected; and the right soon participated. The affection increased now with such rapidity, that in May she was quite blind. She left the Hospital for a short time in July. At that time it is noted that the protrusion of the eyes was greater, and there was occasional conjunctival inflammation from want of closure of the eyelids, with œdema where the edges of the tumour pressed upon the conjunctiva. The appearance of the eyes was not otherwise changed. There was a harder and more prominent growth in the right orbit, chiefly its inner half, and a discharge of pus from the right nostril. The fulness of the infra-maxillary region was greater, and she complained of feeling the whole cheek pushed up, from the palate yielding, when she masticated—though there had been no apparent change in this of late. There were occasional pains in the head, chiefly in the forehead, and some appearance of prominence of the forehead on the right side, though this was doubtful. There was no redness anywhere, except two round prominences, of a pinkish colour in each inner canthus, probably the lachrymal sacs filled with soft substance. Her health was little disturbed; she was calm and composed, without any cancerous cachexia. She returned to the Hospital in the following month (August, 1849, a year after her first admission), complaining of intense pain in the head and face, vomiting after food, and loss of sleep. These symptoms were allayed by morphia, salines with hydrocyanic acid, and the local use of chloroform—but recurred frequently. In November it was noticed, that the left eye was becoming much more prominent, and that the solid mass had increased equally, so that more was felt at the lower part of the orbit as well as the upper. The upper eyelid could still cover the eyeball, though with difficulty and straining. Notwithstanding the frequent attacks of

cerebral disturbance, she had not lost much flesh, and was calm and resigned. In December she had an attack of erysipelas of the face and eyelids, and suffered for some months afterwards from occasional abscesses of the face, eyelids, and forehead. In February, 1850, it was noticed that the superior maxillary bones projected nearly an inch beyond the inferior, so that she had some difficulty in masticating. The tumour continued to make slow progress during the rest of her stay in the Hospital. During the summer (July to September) she suffered from an aggravation of the symptoms described above; but recovered her usual condition before October, 1850, when she finally left the Hospital.

The patient survived her discharge from the Hospital about three years, and then sank very gradually. She was sensible up to, at any rate, the day before her decease, and is believed to have had no paralysis.

The preparation, represented by the figure on Plate VI., shows a large tumour projecting into the cranium, the orbits, the antra, the nasal zygomatic and pterygo-maxillary fossæ, and appearing in large masses on the cheek. It occupies the base of the skull from the front, where it touches the perpendicular plate of the frontal bone, to the back, where it encroaches somewhat on the pituitary fossa of the sphenoïd, and laterally involves almost the whole of the orbital plates. It trenches slightly on the middle fossa on the left side, and on the right there is a distinct process which is attached to the bones of the middle fossa, nearly as far back as the section reaches. The part in the anterior fossa is nearly two inches in height, in some parts, and must have reached nearly to the vault of the skull. The dura mater is seen covering the lateral portions of the tumour. On the right side the optic and third and fourth nerves are seen raised and flattened by the tumour; on the left, the three branches of the fifth nerve are seen, the two first of which seem involved in the growth. Both orbits are completely filled by the growth, which projects out of them in large masses on to the cheeks. The shrunken remains of the globes of the eyes may be seen pressed outwards and backwards, and resting on the tumour. All the above-mentioned fossæ are seen to be quite filled up, and the bones of the face and orbits are extensively absorbed. The hard

DESCRIPTION OF PLATE VI.

The Figure illustrates Mr. T. Holmes's case of Enchondromatous Tumour arising within the Skull, p. 252.

The tumour is represented from the front, as displayed by dissection. By removal of the calvarium, the extent of its upward growth is shown, though imperfectly.

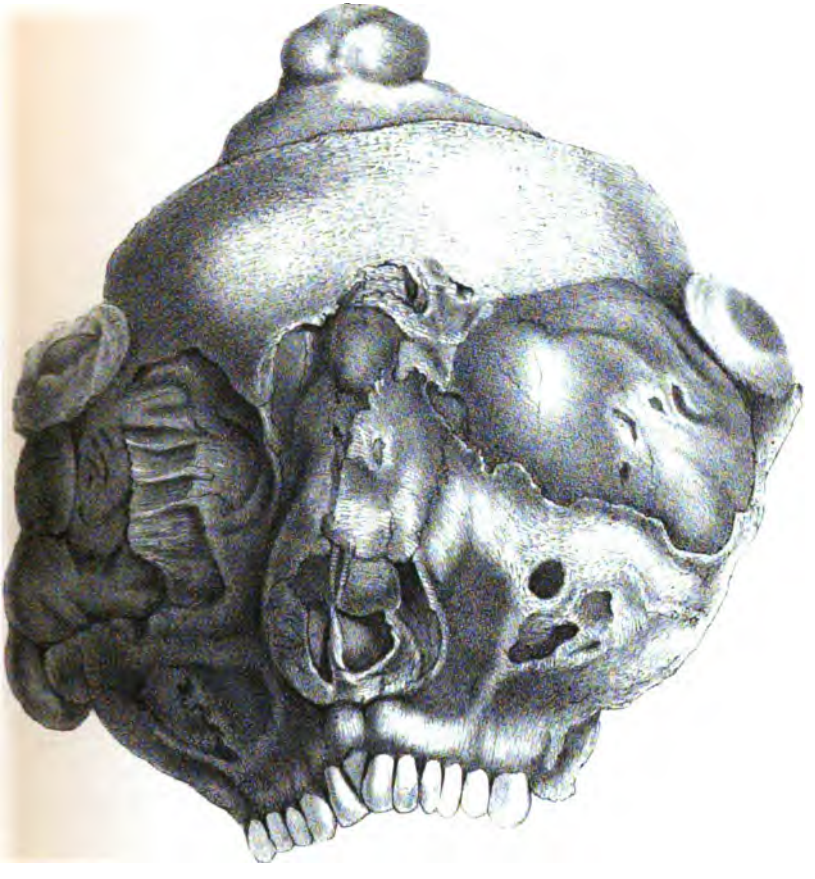

C. Chereval del. Tuffen West lith

W. West imp.

palate is pressed downwards, so that the teeth on the two sides deviate from their natural line, and the left central incisor crosses that of the right side. The distance between the glenoïd cavity and the last molar tooth is much greater than natural.

Microscopical examination of the tumour shows it to consist principally of cartilage.

The tumour with the bones weighs one pound fourteen ounces; the average weight of the base of skull being from nine to ten ounces. Mr. T. Holmes, *2nd of March*, 1859.

---

12. *Epithelial Cancer occurring in the Cicatrix of a Burn on the Arm.*

E. R., a needlewoman, æt. 27, fair, extremely anæmic, of moderate stature. Father and mother both dead; no history of cancer could be traced in any of the family. Health said to be generally good; but she has lived badly. Catamenia not very regular, and absent for the last three months. When nine years old, she fell accidentally into the fire, and was severely burnt.

On the 10th of March, 1859, she applied at the Middlesex Hospital, on account of a sore on the arm. On examination, extensive cicatrices of burns were found over the right arm, shoulder, back, chest, and neck. On the inside of the arm was an open sore, with elevated thickened edges, emitting a very offensive odour, and bearing all the characters of epithelial cancer. It extended from about two inches above the elbow, almost to the axilla; and in breadth occupied nearly one-third of the circumference of the limb. In the axilla was a mass of enlarged glands, over the most prominent part of which there was an opening of about the size of a sixpence, with prominent edges, and leading into a deep cavity, from which a thin purulent fluid exuded. There were no enlarged glands to be felt above the clavicle, with the exception of one, of about the size of a small horse-bean, which was not tender. The corresponding gland on the other side of the neck not enlarged.

The *history* she gave was, that four months ago she observed a small pimple in the dense cicatricial tissue on the inner side of the arm; she poulticed it, ulceration took place, and the disease

gradually extended to its present condition. The glands in the axilla began to enlarge about a month ago, and for a fortnight have been discharging. She continued her needlework until the condition of the axilla prevented her using her arm; and she has had no treatment beyond poultices, not having applied anywhere for medical assistance till she came to the Hospital. As the disease was advancing rapidly, there was no choice between removing the arm at the shoulder-joint, and dissecting out the affected glands, or leaving her to a certain and painful death. Accordingly, on the 14th, the operation was performed, a large flap being first cut from the outer side of the arm; the incisions were made from without inwards, to secure a greater substance of the muscle; the bone was dis-articulated in the usual way, and after the separation of the limb, the whole of the diseased mass in the axilla removed, including every visible portion of cancerous structure. An excellent stump remained, and has now (April 27th), almost entirely healed, the patient having progressed in every way favourably, with the exception of an attack of secondary hæmorrhage, on the 16th day, from the effects of which she speedily recovered.

The edges of the ulcer when examined by the microscope presented the usual characters of epithelial cancer. A portion of the internal cutaneous nerve ran across the sore, exposed, and for the extent of more than an inch quite isolated, and uninjured by the diseased growth.

On making a section of the mass from the axilla, it was found to contain a cavity of about two inches in diameter, opening at the ulcerative spot on the surface. The walls of this cavity were composed of epithelial cancerous material, and their interior covered with nodules of new growth, the surface of which was smooth, and secreting pus. This condition would probably have arisen from the mass of glands in the axilla softening and suppurating, then discharging their contents by the opening in the surface, the walls of the abscess thus formed taking on a new cancerous growth, which, advancing rapidly, seemed likely soon to fill up the interior. A similar formation of abscess in a mass of cancerous glands is often seen in the analogous case of secondary affection of inguinal glands, in malignant disease of the scrotum or

penis, and is quite different from the ulceration commencing at the surface which takes place in the primary disease.*

Mr. FLOWER, 15*th of March*, 1859.

---

13. *Melanotic Recurrent Fibroïd Tumour.*

This specimen was sent to me by Mr. Dolman, of Derby, with the following history. W. W., æt. 53, an inn-keeper, had a mole or mark on his back; this was scratched at the end of the year 1851, and a small lump came, which, in course of a few months, reached the size of a walnut, and was removed by ligatures and caustics. At the end of about two years, another growth, the size of an apple, was removed from the same place by the knife. In August, 1856, he went into the Derby Infirmary, and Mr. Hearn again removed a mass the size of a pint jug; the wound soon healed by granulations. The lump again began to appear, and gradually increasing, he was admitted into the Infirmary in December, 1857; the tumour then reached from the fifth to the seventh dorsal vertebra, and was removed by the knife. In March, 1859, the patient again visited the Infirmary, with the recurrence of the tumour for the fifth time, and another also then existed in the axilla.

The growths had a cancerous appearance, but were found to be composed of fibres containing large nuclei, corresponding to the recurrent fibroïd structure, amongst these were large masses of pigment or melanotic matter. The interest of the case was in the fact of melanosis being added to a growth of this character, and showing that the pigment was a mere accidental part of it; for just as a cancerous tumour may be observed springing up on a mole, and necessarily containing pigment, and being propagated with this addition, so may a less malignant or recurrent fibroïd spring forth from a pigmental piece of skin, and continually as it recurs be found to have the colouring matter within it.

Dr. WILKS, 5*th of April*, 1859.

* The patient remained for two months after the operation in comparative comfort; but at the expiration of that time, the cervical glands enlarged, and became painful, and the edges of the wound, which never completely healed, showed signs of the re-appearance of the disease; this has been gradually advancing up to the present time.—W. H. F., 6th of September, 1859.

14. *Colloïd Cancer from the Calf of the Leg.*

The tumour was sent to the Middlesex Hospital Museum, by Mr. Douglas, of Hounslow, by whom it was removed. The patient, a married woman, æt. 61, had observed, fifteen years previously and about a fortnight after the birth of her tenth (last) child, an enlargement on the inside of her leg, below the knee, of the size of a hazel-nut. This was first taken for a gland, but it gradually increased in size; in seven years, it had become as large as a tennis ball, and since then she has kept an elastic bandage, or rather pouch over it, notwithstanding which, it continued to grow. The skin over it became tensely stretched, and at the beginning of the present year, began to ulcerate. There was never any lancinating pain in the part, and until the skin gave way, the patient suffered very little inconvenience from it. On removal, the tumour was found to dip between the muscles of the calf, and to be closely united to the deep fascia. It is of a flattened spheroïd form, about five inches across, and three inches in depth; has a distinct, dense, limiting membrane or capsule completely isolating it from surrounding structures, is deeply lobulated, and has an elastic, semi-fluctuating feel.

On section, it presents the characteristic appearance of colloïd. Fibrous septa pass inwards from the capsule dividing the tumour into a number of separate lobules; these are filled up with a gelatinous substance, homogeneous in texture, semi-transparent, whitish in colour, with, in some places, a yellow or green, in others, a pink hue; varying in consistence from that of a very firm jelly, to that of a viscous fluid. Under the microscope, portions of this substance exhibited the fibro-membranous stroma of colloïd, (see Plate VII., Fig. 1), with rather an unusual preponderance of extremely delicate, curved, and intersecting fibres, not affected by acetic acid (in which respect they differed from the fine fibrous or areolar tissue, which constituted the septa, between the lobules). Among these were little masses of granules of various sizes, and numerous globules, apparently of oil. No nucleated cells were seen, but the spirit in which the specimen had been preserved for some time before it was examined might have somewhat altered its character.

Although, in accordance with the general custom, this speci-

DESCRIPTION OF PLATE VII.

Figure 1 represents the Microscopic appearances in Mr. Flower's Case of Colloïd from the Calf of the Leg, p. 256.

Delicate curved intersecting fibres formed a prominent feature in the microscopic structure of the growth. There were also white fibrous tissue, small granular cells, little masses of granules of various sizes, and numerous globules, apparently of oil.

Figures 2 to 5 illustrate Dr. Harley's case of Bronzed Skin, p. 265.

Fig. 2. Section of epidermis from the side.

a. The deep layer of cells, filled with pigment. The nuclei also are very dark.

Fig. 3. Section of portion of the abdominal parietes.

A. Layer of epithelium covering the peritoneum.

B. Pigment deposit.

C. Muscular layer.

Fig. 4. Separate cells, and masses of pigment from the same part.

A. Cells containing pigment.

B. Masses of pigment unsurrounded by a cell-wall.

Fig. 5. Transverse section of the supra-renal capsule, apparently healthy in structure.

A. Cortical substance.

B. Medullary substance.

C. Sinuses.

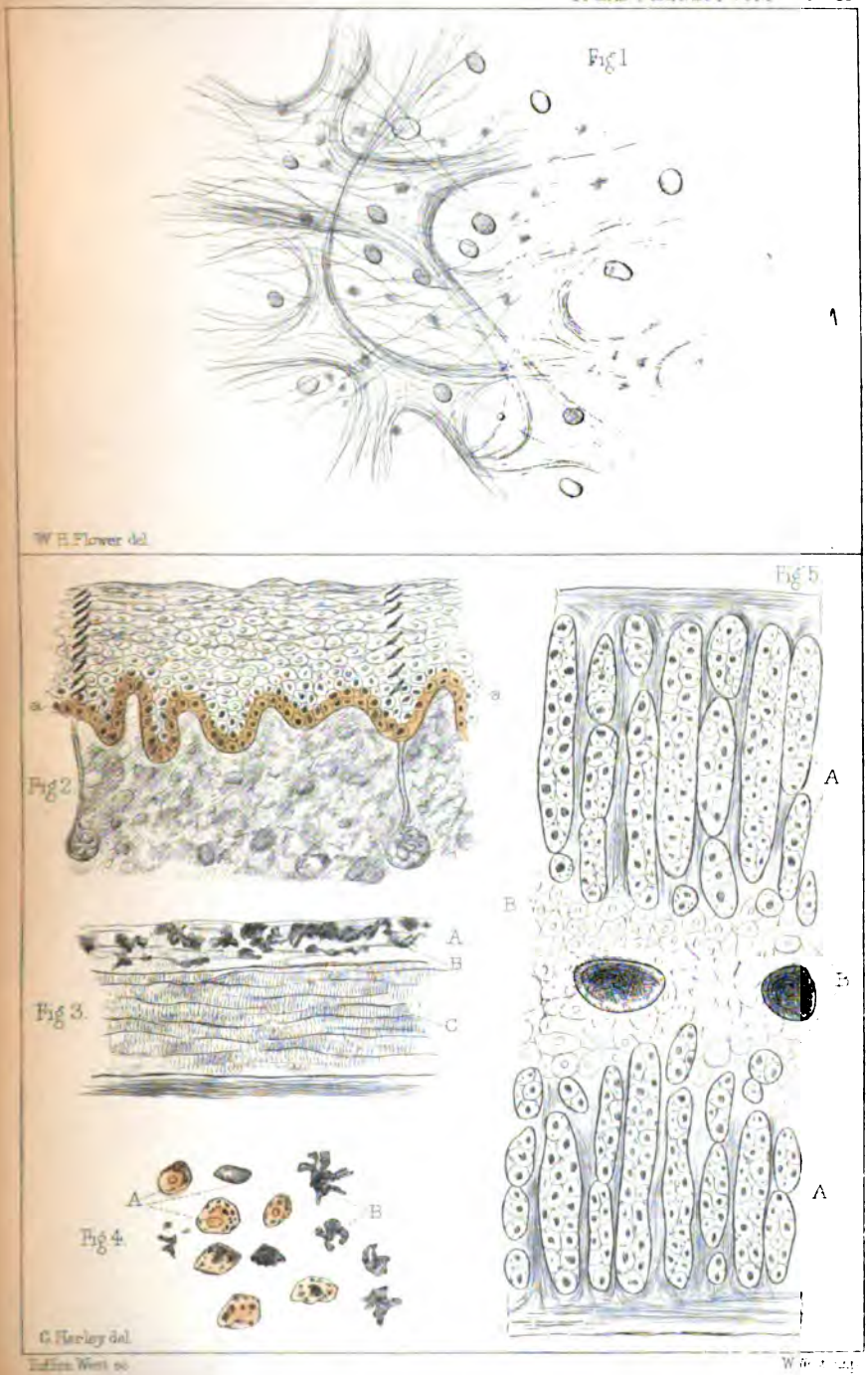

Buffon West sc.

men has been described in the title of the paper, as colloïd cancer, the author agrees with Mr. Sibley, that the connection between this disease and cancer, properly so-called, is more than doubtful, and refers for the reasons for this opinion to a paper by that gentleman, "On the Structure and Nature of the so-called Colloïd Cancer," in the *Medico-Chirurgical Transactions*, Vol. XXXIX. Mr. W. H. FLOWER, 19*th of April*, 1859.

---

15. *Subcutaneous Malignant Tumours containing Melanotic Matter.*

H. S., æt. 64, was admitted into the Marylebone Infirmary, under my care, October, 1858.

For several months past she has noticed several small swellings of about the size of peas, under the skin on the lower part of the abdominal region. One, however, of the size of a walnut, is very dark in colour from vascularity and threatens to burst and bleed; all are subcutaneous, and but little if at all adherent to subjacent tissues. I removed the large one entirely without injuring the muscles, and she was discharged in about a month's time, when the wound had healed.

On the 20th of January, 1859, reädmitted, with a large tumour nearly in the same situation; very vascular, and dark in colour. The other small tumours had increased in size; she was excessively weak and emaciated, and died three weeks afterwards.

Post-mortem examination.—At the site of the operation, there was now a tumour, the size of a fist, surrounded by numerous independent and subcutaneous swellings, each about the size of a small bean. The large tumour involved the muscles, and reached to the peritoneum; its outline was limited and not confounded with surrounding tissues. Contents, were a pultaceous matter of a dark slate colour. In the iliac glands of the same side, there were several small tumours of a similar character. The liver contained numerous deposits of the same material, varying between the size of a pea and an egg. Similar deposits, but fewer in number, were also found in the lungs.

Under the microscope.—The pultaceous matter was made up almost entirely of nucleated cells of ovoïd form, regular in size, most being about $\frac{1}{2000}$ of an inch in long diameter. The outline of

the cell-wall was clearly defined; within were numerous granules, some dark and opaque (pigment?); others highly refractory (oil); also, dissolved colouring-matter within the cells, especially in those from the deposits in the liver (bile?). Free masses of colouring-matter were also scattered in the field from the deposits in any situation. The cells in the liver deposits were generally larger and more irregular in form than those found elsewhere.

Mr. Henry Thompson, 19*th of April*, 1859.

---

16. *Recurrent Fibroid Tumour at the Bend of the Elbow, for which the Arm was Removed.*

The patient, a lady, æt. 72, from whom this specimen was taken, first came under my care in 1856, with a large, irregularly nodulated tumour at the inner side of the elbow. It had existed for about six months, and had apparently arisen from the irritation caused by a poisoned finger, the swelling being noticed almost immediately after the healing up of the sore. At the time of its removal, in June, 1856, it was as large as a hen's egg, and was rapidly increasing. The ulna nerve was firmly attached to, and mixed up with its capsule, and had to be divided in the course of the operation. The wound healed up quickly, and there was no reäppearance for nearly two years. A little hardness then came at the outer part of the cicatrix, but as it was not painful she did not apply until it had assumed nearly its present size. At the date of amputation, it was growing rapidly; the hand was swollen, cold, and painful, and the fingers presented a shrunken appearance, their sensibility was impaired, and they at times assumed a gangrenous appearance. There was hardly any pain in the tumour itself, though in many parts, the skin over the nodules was so tense and purple, that it seemed as if it might at any time give away.

The patient being in tolerable health, I decided to remove the limb. The tumour occupied the inner and anterior part of the bend of the elbow, and extended from the lower margin of the middle third of the arm to the junction of the upper and middle thirds of the forearm.

On section it was found to be made up of distinct cysts, varying

in size from that of a walnut to that of a cherry. It was of an opaque pinkish-grey colour, and crossed in various parts by the cyst-walls. The contents of the cysts very readily separated, leaving a clear glistening cyst-wall. The cut surfaces of the cysts presented a convex appearance; no true juice existed, and but little variation in the consistency of the different parts; it was moderately firm. Under the microscope it was found to consist of abundant small non-nucleated cells, some round, others of a long, oval shape, larger cells, with indistinct single nuclei, a few oat-shaped cells containing nuclei, and a few large rounded cells containing two nuclei. The original tumour resembled this, but was of rather a firmer consistence. Mr. SHILLITOE, 17*th of May*, 1859.

IX. DISEASES, ETC., OF THE DUCTLESS GLANDS.

I. THE SPLEEN.

1. *Enlargement of the Spleen and Lymphatic Glands.*

H. S., æt. 18, died under the care of my colleague, Dr. Pavy, in Guy's Hospital, on the 23rd of March, 1859. He had been a soldier, but pensioned about a year before his death owing to ill-health; his symptoms being increasing debility with enlargement of the glands in the neck. On admission, he was so feeble that he was unable to rise from his bed; he was perfectly white, and he was more or less dropsical all over, so that his first appearance suggested the idea of Bright's disease; the urine, however, was not albuminous. In the neck, and more especially on the left side, was an immense mass of enlarged glands; the blood was examined microscopically by the clinical clerk, and found not to contain any marked excess of white corpuscles. The spleen could be felt enlarged. His only symptoms while under observation were those dependent upon his almost bloodless condition, producing a pallor and feebleness quite remarkable.

The *post-mortem examination*, showed the body to be generally dropsical on the surface, including the arms and face; the internal serous cavities also contained serum, and the parenchymatous organs were œdematous. In the neck there was an enormous

tumour, composed of enlarged lymphatic glands, and the same condition continued down into the chest and abdomen; thus the mediastinal glands, both anteriorly and posteriorly, were immensely enlarged, including the bronchial, as were also those in the lumbar region, the inguinal being unaffected; these glands had undergone a separate enlargement, and thus were easily moveable on one another, and having no adhesions by any inflammatory products. The lungs were œdematous, but otherwise healthy. The heart was undergoing fatty degeneration, the inner surface of the left ventricle covered with a number of white streaks. The spleen was very much enlarged, weighing two pounds nine ounces; a section showed, scattered through it, a number of white deposits, like lumps of suet, and small streaks of similar matter in other parts. The liver was also enlarged, and weighed five pounds six ounces; it was coarse and granular, and on close examination was seen to have a number of white specks scattered through it, of the same character as those in the spleen. The kidneys also had the same coarse appearance, and presented the same minute speckling, owing to a similar deposit in them. All the other organs were healthy, including the brain, thyroïd, suprarenal bodies, &c.

The microscope showed the deposit in the liver, spleen, and kidney to be of the same character as that in the lymphatic glands, composed essentially of a nucleated fibre-structure, with some little amount of lardaceous matter combined with it. The glands, on section, showed a translucent or gelatinous appearance, but at the same time were very tough: portions were with difficulty torn up for the microscope, and then found to consist of nucleated fibres, with some amorphous lardaceous or waxy matter mixed with them. The material in the spleen showed the same tissue undergoing degeneration, and also that in the liver and kidney; in the latter organ it was remarkable to see bundles of nucleated fibre deposited between the urinary tubules.

I have brought forward this case as an example of a not very uncommon form of affection, but one which is not always recognized as a peculiar disease, and therefore requiring some distinctive name. The first notice of it is to be found in Volume XVII. of the *Medico-Chirurgical Transactions*, where Dr. Hodgkin relates

several cases of enlargement of the lymphatic glands, with a white deposit in the spleen. Subsequently, Dr. Bright, in a paper on abdominal tumours, refers to the latter organ as being subject to a malignant form of disease in connection with a glandular affection. In a paper which I published in Volume II. of the Guy's Hospital Reports, I re-quoted Dr. Hodgkin's cases, and related some others which had since occurred to me, but am unable to gather any from extraneous sources, excepting one brought before the Pathological Society by Dr. Markham, and recorded in Volume IV. of the "Transactions." This was the case of a young man who died with dropsy and anæmia, and it was found after death that all the lymphatic glands were much enlarged, and the spleen was filled with straw-coloured masses, and was one pound ten ounces in weight. The author felt some doubt as to whether to place the affection with cancerous or tuberculous disease.

It appears, then, certain, that there is some affection which especially attacks the lymphatic glands and the spleen; but judging from the present example, the other organs may be likewise involved, though to a less extent; and it is possible that in the earlier observed cases, the same might have existed, though overlooked, from want of microscopic examination. It will be seen that the deposit is principally fibrous in character, but associated with some translucent lardaceous material, and the glands have a similar structure. Quoting from my above-named paper, "the enlargement of the glands is gradual, extending sometimes over a period of two, three, or more years, and often, from commencing in the neck, called scrofulous. When the mischief is thus gradual in its commencement, and affecting only part of the glandular system, no marked symptoms ensue; but as time tends to its development in the thoracic and abdominal glands, a slow prostration ensues, terminating in death. The glands often reach an enormous size, much larger than when affected with scrofula; a bunch of them often being composed of separate tumours, each the size of an egg. When felt during life in their early progress, they are recognized by their peculiar elastic feel, differing both from the early hardness or the subsequent softness of scrofulous glands, and also differing from these (as far as our

experience goes) by being quite unaffected by remedial treatment, as iodine. In fatal cases, they are found, not only forming large tumours in the neck and groin, but accompanying the aorta its whole length throughout the body, and thus affecting all the posterior mediastinal and lumbar glands, occasionally even following the arch of the aorta to the anterior mediastinum. Sometimes, however, none of the external glands have been affected, and the existence of glandular enlargement has not been known until after death. When these bodies are removed, they are seen to form distinct tumours, easily separable from each other, there being no bond of union between them, arising from any previous inflammatory action or deposition of new material amongst them. When incised, their appearance is altogether peculiar, being of yellowish-colour, and having a soft translucent aspect. Upon squeezing or attempting to tear them, however, this softness is found to be an illusion, as they are remarkably tough, and emit no juice, but only a little serous fluid. On cutting off a small portion, and attempting to separate it by needles, it is found to have almost a leathery consistence. The cut surface of the gland is quite uniform, presenting no appearance of structure to the naked eye, though sometimes it contains small masses of dead material in the centre. The first idea suggested by its general aspect is a simple hypertrophy of the gland; but a microscopic examination shows this to be incorrect, for, although some glandular secreting elements may still be found, yet the main structure is a fibro-nucleated tissue; in fact, an altogether new formation, and not to be distinguished from an ordinary fibroplastic growth. Sometimes, besides the nucleated fibre element, there has been present some albuminous amorphous material, especially in those cases where lardaceous disease has existed elsewhere. The most remarkable feature in the history of the disease, is its intimacy with that peculiar affection of the spleen, which slowly and inevitably leads to a fatal end; the symptoms being anæmia, prostration, and final exhaustion. In what measure the lymphatic glands and spleen relatively participate in producing this result, I will not venture to say, although sufficient is known of the functions of both organs to give assurance, that disease in either will lead to severe derangement of the system;

and, moreover, connected as they are with the blood-making process, that if a slow destruction of their structure goes on, so will a gradual death of the patient as assuredly ensue."

From a comparison of these cases, it will be seen that they bear a close relationship to tuberculous and lardaceous disease, in as much as all the three conditions may be found associated. For instance, I should surmise that lardaceous disease signifies a simple albuminous plasma poured out into the various organs; and that this is probably closely allied to gelatinous infiltration of a tubercular lung; now if this occur, and at the same time any cell-structure should form, tubercle becomes associated with it; and if, on the other hand, a nucleated fibre should be produced, we have the combination as in the present case.

With regard to the effect of iodine upon lardaceous or waxy matter, I may repeat my statement in the paper before alluded to. "From my own experience, I should say that ordinary lardaceous or colloïd matter is not turned blue by iodine and sulphuric acid, as some appear to suppose." Dr. WILKS, 19*th of April*, 1859.

---

2. *Cystic Disease of the Spleen.*

This specimen came from an old woman, who died in Guy's Hospital of Bright's disease, and in whose kidneys cysts also existed. The spleen was of average size, but at its lower end there was a cyst of about the size of a walnut, and on its surface a few smaller ones. These contained simple serum, and were lined by a smooth membrane.

The interest of the specimen was in relation to the general formation of cysts, whether due to a distinct growth of cells, or to a dilatation of the natural tubes of the part. Although both theories can be held respecting many organs, I do not think that the latter is the true one, either in the kidney or liver, and as regards the spleen, it cannot of course be maintained, and thus affords an evidence of a distinct cystic disease. It is remarkable, that in this case, as well as those of cystic disease of the liver, the same affection of the kidney also existed.

This disease of the spleen is very rare, but Guy's Museum contains one other specimen; which came from a man who died of

Bright's disease. The organ contains several irregular cells, the largest of which is of about the size of a pigeon's egg; they do not communicate, they contain a serous fluid, and the splenic structure is healthy. Dr. WILKS, 19*th of April*, 1859.

II. SUPRA-RENAL CAPSULES.

3. *Bronzed Skin; Supra-renal Capsules healthy.*

The case was one of peculiar interest on account of the extensive, and intense darkening of the skin being associated with perfectly healthy supra-renal capsules.

The patient, a cabman, æt. 66, was admitted into University College Hospital, under the care of Professor Parkes, on the 7th of October, 1858; he was then suffering from ascites, dependent on contracted liver; was a fine, strong-built man, and in spite of extremely intemperate habits, and exposure to weather, had enjoyed remarkable good health, up to within four or five months before admission into the Hospital. The only illness he could recall to mind was an attack of jaundice seven years before, for which he was treated in the University College Hospital during five weeks. He left the Hospital apparently well. Four or five months afterwards, however, he noticed that some parts of his skin (which before had been of healthy colour) were gradually becoming darker, especially the skin of the face and neck; he also noticed dark patches on the trunk, arms, and thighs, which gradually increased in size, until a very considerable part of the whole body had assumed a very dark hue. On admission, the dark colour was uniform, or with slight variations of tint over the face, neck, shoulders, and arms; but over the trunk, and especially over the abdomen, it was diversified with irregular white patches, varying in size from one to four inches in diameter. It was uncertain whether these patches were whiter than natural, and he said he thought that those portions of the skin which did not become dark, became whiter than before. There was a little pigment on the conjunctiva (different from jaundice coloration), and a dark patch on the mucous membrane of the lips. The conjunctivæ were slightly

yellow, and the urine contained a small quantity of bile pigment; but the discoloration of the skin was not like that of "melas icterus," to say nothing of the white patches being altogether opposed to the hypothesis that the dark tint could be attributed to bile pigment.

The blood was examined microscopically; but no excess of white corpuscles or free pigment was found. The red corpuscles were large, flabby, and dingy-looking; blood crystals could not be obtained.

This patient was regarded with much interest during life, as it was supposed to be a marked case of so-called Addison's disease.

Post-mortem examination.—The microscopic characters of the skin were found to correspond with those cases of the so-called bronzed skin; there being great pigment deposit in the retemucosum, or lower layer of epidermic cells, as represented in Plate VII. Fig. 2, *a. a.*

There was also pigment deposit beneath the epithelium of the peritoneum, forming several black patches of various sizes. (See Fig. 3, A. and B., and Fig. 4, in Plate VII.)

The supra-renal capsules were perfectly healthy, both in size, shape, makroscopic and microscopic characters.

Right supra-renal capsule.—Normal in colour, of healthy consistence; of usual size and shape; measured two inches and a-quarter in its longest diameter; one inch and a-quarter in height; a-quarter of an inch at the thickest part. On section the medullary substance (Fig. 5, B.) was beautifully well marked, of the healthy slate-colour and firm consistence; no large cavity in it; no grumous matter; row of small sinuses (Fig. 5, C. C.), distinct, full of healthy-looking blood. Cortical portion (Fig. 5, A. A.) well-defined, running all round the medullary in a well-marked yellow ring, looked perfectly healthy.

Left supra-renal capsule.—Normal in colour, size, shape, and consistence; measured two inches and three-eighths in longest diameter; one inch and a-quarter high. On section the medullary as well as the cortical substance appeared perfectly healthy. Examined with the microscope, the columnar cell-masses (Fig. 5, A.) of the cortical substance were beautifully seen; the medullary cellular matter (Fig. 4, B. B.) was equally distinct; not the remotest trace of disease could be detected in either this or the other capsule.

The liver weighed thirty-four ounces, and was a fine example of hobnail or granular liver. The spleen weighed fourteen ounces and a-half; its capsule was uniformly thickened, to the amount of about a-quarter of an inch. The kidneys weighed four ounces and a-half each, and seemed healthy to the eye; but on microscopic examination were found to contain a slight excess of fibrous tissue. For fuller particulars of this case see Professor Parkes's paper in the *Medical Times and Gazette*, p. 600, Vol. II., 1858.

The preparations of the case are preserved in University College Museum.

Dr. Harley, 16*th of November*, 1858.

---

4. *Tubercular Disease of the Supra-renal Bodies. Bronzed Skin.*

The specimens exhibited (the supra-renal bodies, and a portion of the skin) were removed from the body of a man, who, during life, exhibited the symptoms which are considered to be characteristic of disease of the supra-renal bodies, the most prominent of which is the gradual alteration in the colour of the skin. I am indebted to Drs. Hancorn and Buss (with whom I saw the patient) for the opportunity of bringing these specimens before the Society.

The patient was a shoemaker, æt. 43, a married man. He was of small stature, thin spare make; hair and whiskers nearly black; eyes dark hazel—up to the age of 33, he had enjoyed good average health, and his father and mother were living and healthy. There was no history of phthisis or scrofula in any member of the family.

The account the patient gave of his illness was the following. When æt. 33, he began to suffer from pain and disease of the right wrist-joint. An abscess at length formed, and the disease terminated by the joint becoming fixed. He remained well for five years, till he had what he termed rheumatic fever, many of his joints becoming very painful. At this same time, however, the spine commenced growing out, and he lost the power of moving his legs. He was only able to walk by dragging his legs after him, the power of raising his feet from the ground being lost. He was blistered freely, and at length improved in his walking, and at the end of twelve months he resumed his

work. He continued in improved health till two years ago (æt. 41), when he was attacked with cough, and commenced losing flesh. The cough has never completely left him since that date, but at times it has been very slight in amount. His wife first noticed that the colour of his skin became dark twelve months ago, and the alteration has been much more marked in the last four months. During this latter period he has lost flesh and strength rapidly, and has been subject to faintness on exertion. For three or four months has had frequent vomiting, and latterly nearly all his food has returned; has had little or no perspiration. For the last five or six weeks, he has been quite unable to follow his occupation.

On the 6th of October, 1858, his face and hands were of a dark-brown colour, like the tint of a half-caste East Indian; the whole of the rest of the surface, arms, legs, and trunk were of a similar tint, but much less dark than the face or hands. The colour on the back of the hands, moreover, was much darker than that of the palms. The skin was of uniform colour, except of the face, where there were some maculæ of darker tint than the rest of the surface; conjunctivæ dirty white; lips dark, rather livid, red; tongue clean, red, somewhat raw. There was extreme emaciation, and the spine was affected with angular curvature, the eighth, ninth, and tenth dorsal vertebra being the most prominent; nearly complete anchylosis of the right wrist also existed, there being several cicatrices on the palm of the hand. The physical signs of partial consolidation of both apices of the legs were also present. The pulse was extremely small and feeble, 100. After this, the debility increased; the sickness continued; the bowels acted regularly, the evacutions being dark; the urine was copious, and usually clear and pale. The expectoration became more plentiful, but consisted only of mucus. He died on the 12th of October, 1858.

At the *post-mortem examination*, which was made forty-eight hours after death, the general colour of the surface was as before described, the rigidity very considerable. There was a complete absence of fat in all the ordinary situations, and the muscles were somewhat dark in colour. The peritoneum and mesenteric glands were quite healthy. The liver of ordinary size, rather congested,

free from fatty deposit. The kidneys also were somewhat full of blood, but were in other respects quite healthy. In the apices of the lungs some small tubercles existed, which were breaking down in a few places, the disease, however, being very limited.

Both the supra-renal bodies were smaller than natural, remarkably hard, and their surfaces being very irregular and knobby. On section the distinction between the cortical and central portions was obliterated, the whole body being converted into a dense yellowish cheese-like substance. None of the natural appearances of the organ could be discovered. On microscopical examination they are found to be composed of shrivelled nuclei not unlike the tubercle corpuscles seen in the lungs and elsewhere, together with a large amount of amorphous granular matter, the whole being supported by fibro-cellular structure.

Mr. SIBLEY, 16*th of November*, 1858.

---

5. *Extensive deposit of Tubercle in the Supra-renal Bodies. No Discoloration of the Skin.*

This specimen was obtained from a man æt. 36, who had deposit of acute tubercle in the pleuræ, lungs, peritoneum, liver, kidneys, and supra-renal bodies.

The right supra-renal body measured about two inches and a-half at the base, two inches from base to apex, and about half- or three-quarters of an inch thick. It weighed one ounce and a quarter. The left was rather smaller. The interior and greater portion of both were found to be the seat of a mass of yellow scrofulous deposit. No discoloration of the skin existed.

Dr. MURCHISON for Dr. SCURRAH, 1*st of February*, 1859.

---

6. *Diseased Supra-renal Capsules. Pericarditis. No Discoloration of the Skin.*

The supra-renal capsules were taken from a man, æt. 36, a painter, who died of pericarditis. One was very much larger—at least five times larger than natural. A considerable quantity of low fibrinous matter was infiltrated through its substance. The other was somewhat smaller than natural, and contained several

masses of calcareous and cheesy matter. There was not the slightest appearance of bronzing in any part of his skin.

Dr. MARKHAM, *5th of March*, 1859.

---

7. *Diseased Supra-renal Capsules. Extensive Discoloration of the Skin.*

Mrs. W., æt. 31, having been drooping for two years without definite symptoms of illness, became worse in September, 1858; was observed by her friends to become jaundiced, as they thought, in the following month, and came under my observation on January 18th, 1859. The symptoms at that time were extreme anæmia, and occasionally vertigo, pain in the loins and sickness; catamenia irregular; pulse under 80, and excessively feeble; skin cold; tongue clean; appetite bad; respiration feeble; heart feeble; lungs apparently healthy; lips livid; tongue pale; gums blanched; conjunctiva clear and pearly. The whole of the uncovered surface had a dusky hue, as if from greenish pigment. The greenish-tinge was produced by a number of small specks, patches and hues of deeper coloured integument; but the greenish discoloration was not of uniform shade, and neither altogether pervaded, nor was exclusively limited to, the exposed portions of integument. It was most evident upon the forehead, temples, back of the neck, and along the course of the trapezius muscle on both sides. The discoloration of the body was a dusky-olive hue, and four remarkable patches of a darker shade, in the dorsal region excepted, did not present the patchiness seen on the face and neck. On each arm and on the sides of the face and neck, were several almost black spots with well defined margins which had the appearance of nævi, but had, she asserted, only appeared within the preceding three months. Elsewhere, the deeper coloured patches faded insensibly into the colour of the surrounding integument. The hair had a strikingly dull, dusky, discoloured appearance, and was said to have become much darker within the few preceding months. There was an ill-defined dark brown line along the red portion of the lower lip, near the margin of the skin; and the buccal mucous membrane on both sides was of a yellowish sallow hue, and had besides several distinct light-

brown stains. Urine normal. Complained of smarting in the darker portions of the face and neck, when she became warm. Very wakeful at nights, but this did not arise from pain or uneasiness.

She continued to suffer from occasional sickness, vertigo, and pain in the loins; the anæmia and coldness of the surface increased; the pulse soon became too feeble to count; palpitation, breathlessness, and a tendency to syncope on slight exertion supervened, and she sank on the 12th of March. For several days before death she was unable to sit up, and had frequent retchings and palpitation on the least movement. She was conscious to the last. A disagreeable fœtid odour was observed about her during the last two days of life.

Post-mortem examination, thirty-six hours after death. Little or no emaciation; mammæ remarkably small and rather like those of a man than a woman; the whole body of a dusky mulatto colour, but the hue was darkest on the abdomen, and next to this on the face, neck, insides of the elbows, and the margins of the axillæ. The abdominal parietes contained a layer of fat one inch in thickness, and the thoracic integuments a layer of half-an-inch in thickness. Muscular tissue normal in appearance. Several firm old adhesions existed between the pleural surfaces; the lungs were congested, but crepitant, and with the exception of a very few yellow tubercles in the apices, the largest of which was the size of a small pea, and the next largest the size of a grain of wheat, were perfectly healthy; the heart weighed five ounces and three-quarters, and contained a large fibrinous clot in the right cavities, extending into the pulmonary artery. The omentum and intestines were very pale; the under surface of the omentum, the peritoneal lining of the diaphragm and abdominal parietes, and the peritoneal covering of the liver, were studded with small yellowish-opaque, irregularly stellate and almost crystalline-looking bodies, probably tubercular, which could be readily scraped off the serous surface with the back of a scalpel, leaving the subjacent membrane apparently intact, but slightly opaque. The peritoneal coat of the small intestines was slightly roughened and on examination with an oblique light, this was seen to be due to the presence of small perfectly transparent granular bodies closely aggregated upon the serous surface.

There was no enlargement of the mesenteric glands and the peritoneum covering the stomach and large intestines was healthy, as were likewise the kidneys, liver, spleen, and pancreas. Some patches of congestion on the mucous surface of the cardiac portion of the greater curvature excepted, the stomach was perfectly healthy. Both supra-renal capsules were converted into hard yellowish masses; on incision, the left capsule was found to consist entirely of yellow-cheesy tubercle; the right capsule was in a similar state, but softened at the centre, from which oozed a few drops of thick creamy fluid when it was divided. There remained no appearance of cortical or medullary substance.

Since the death of Mrs. W., I have been consulted for a sister, æt. 20, who is anæmic, slightly dusky in colour, and in whom the buccal mucous membrane has the same sallow hue but less intense, and without the brown stains that existed in her sister. There is no evident cause for the extreme anæmia, and her friends sent her to me, because they observed her colour to be undergoing the same change as her sister's had done.

Mr. Simon *for* Dr. E. H. Greenhow, *5th of April*, 1859.

---

8. *Extensive Disease of the Supra-renal Capsules. No Discoloration of the Skin.*

The man from whom the specimens exhibited were taken, was aged 23, of very fair complexion, of light auburn hair, and without the least discoloration of the skin. He died in the Middlesex Hospital of exhaustion, consequent upon enormous lumbar and pelvic abscesses, the result of caries of the sacral and lumbar vertebræ.

Post-mortem examination. — Lungs slighly emphysematous, but otherwise normal.

Heart and Pericardium normal. Thyroïd gland normal.

Liver (eighty-five ounces), very large, fatty, pale. Spleen normal.

Kidneys, large, tumid, containing numerous deposits of white tuberculous matter, which, in some spots, had undergone softening. The spots vary in size from that of a pea to that of a hazel-nut.

Each supra-renal capsule weighed three-quarters of an ounce. The normal structure was almost entirely replaced by a firm yellow

deposit, nearly amorphous. In a few spots which presented a more normal appearance than the rest, traces of the cortical tubes could be found; but these also contained much amorphous matter, mixed with nuclei, granules, a few shrivelled and withered cells, and numerous crystals of hæmatin.

Several mesenteric glands near the left kidney were swollen and infiltrated with (probably) scrofulous deposit.

Dr. Charles Coote, 17*th of May*, 1859.

---

9. *Epithelial Cancer of one of the Supra-renal Capsules, with similar Disease of the Tongue. No Discoloration of the Skin.*

T. S., æt. 66, died in the Middlesex Hospital under the care of Mr. Shaw. The patient had discovered a small hard lump near the base of the tongue on the left and under side. Sixteen months before his death the lump gradually increased in size, its surface became ulcerated, and the glands under the jaw enlarged. He was admitted into the Hospital on the 23rd of March, 1858, and the disease having passed through the usual stages, he gradually sank, and died on the 12th of July.

Post-mortem examination.—The body was found to be well formed, and was not emaciated. The skin did not exhibit any discoloration, or abnormal appearance. The tongue was nearly destroyed, its place being occupied by a foul ulcer, the edges of which, and also the glands beneath the jaw, presented the ordinary features of epithelial cancer. Microscopical examination of portions of the diseased mass verified the suspicion of the epithelial nature of the disease.

With the exception of the supra-renal body, all the viscera were healthy, the lungs, liver, spleen, kidneys, presenting no abnormal appearances.

The left supra-renal body was of the usual size, consistence and, colour, and under the microscope presented the natural structure. The right supra-renal body was enlarged to nearly double the size of the left, the chief increase in size being in the vertical direction; the general form, however, of the organ was to a certain extent preserved. On section the distinction between the cortical and medullary portion was completely lost, the whole

organ being converted into a firm, almost fibrous-looking, cream-coloured substance. In a few portions the tissue was broken down, a ragged cavity the size of a pea being observed. A microscopical examination proved that a large portion of this structure was of the nature of connective tissue, developing fibrous structure being observed together with many fusiform cells. In addition to these elements, large numbers of cells were observed, which closely resembled epithelial cancer cells. They were very irregular in form and size, but were mostly flattened and nucleated. A few bodies composed of similar cells, having a laminated arrangement were observed, the central portions being occupied by masses of more spherical cells.

Mr. S. W. Sibley, *17th of May*, 1859.

---

10. *Case of Bronzed Skin, with disease of the Supra-renal Capsules.*

This specimen was sent to Dr. Addison by Mr. Welford, of Bishopwearmouth, with the following history. W. S., æt. 21, a pupil to a druggist, was first seen by me on the 21st of February, 1859, for a rather severe attack of inflammatory sore-throat; but he had for some months previously been complaining of excessive debility, without anything to account for it; although his friends remarked that his complexion was getting darker, indeed, they thought he had jaundice; during this time he had taken various kinds of medicine, without experiencing any relief. After two or three days, the throat-affection was quite relieved; but the great weakness and rapid pulse, together with his dusky appearance, induced me to examine very carefully the surface of his body, when I found several dark olive-coloured patches: one or two on his shoulders and chest, one on each side of the umbilical region; but the most marked discoloration, amounting to almost an ecchymosed appearance, was on the integument covering the penis and scrotum; so dark were the genital organs, that his friends asked me if they were not mortified. I also detected considerable enlargement of the liver during my attendance; vomiting was persistent, and there was also great thirst; urine dark, and occasionally passed in large quantities; the skin could not be said to be dry, yet the moisture did not amount to perspiration;

the debility increased daily, and was accompanied, during the last few days, by stupor, from which, however, he could be roused by loud speaking; he derived no benefit from the treatment pursued, but gradually got worse, and died on the 5th of March.

Post-mortem examination.—Body not emaciated, but had a livid dusky appearance; the genital organs were not near so dark as during life. On cutting through the abdominal walls on the surface of the left rectus muscle, near the umbilicus, was a patch of black exudation, more like melæna than anything else, penetrating the muscle to about a line in depth; a similar patch was found on the under surface of the right rectus, a little below the umbilicus. The liver was enormously distended by portal congestion, but perfectly healthy. The left kidney was about twice the natural size, but healthy in structure, as was also the corresponding supra-renal capsule. The right kidney not so large as the left, but yet larger than natural, and healthy in structure. The right supra-renal capsule was diseased, containing a small collection of cheesy matter, with a drop or so of thinner fluid in the centre. Other organs healthy.

The supra-renal capsule was examined by Dr. Wilks, and found wholly changed in structure, from the deposition of a firm albumino-cretaceous deposit throughout its substance.

Dr. Wilks for Mr. Welford, *17th of May*, 1859.

In the succeeding Tables a classification of the above-described cases of disease of the supra-renal capsules will be seen, arranged especially with reference to the existence or absence of a "bronzed state of the skin" in those cases. In the following Table (A), are arranged those cases in which "bronzing of the skin," *was* associated with a more or less complete disorganization of the supra-renal capsules.

TABLE A.

No.	Name of the Exhibitor and Date of Exhibition.	Age and Sex of the Patient.	Colour of the Skin.	General State of the Affected Capsule.	Whether both Capsules were involved or not?	Were the Affected Capsules wholly destroyed?	General condition of other Organs.	Number in foregoing list of cases.
1.	Mr. Sibley. Nov. 16.	Man, aged 43.	The skin of the face and hands dark-brown, like that of a half-caste East Indian. The whole of the rest of the body of the same colour, but to a less extent. The skin on the back of the hands much darker than on the palms; and darker spots on the face.	Supra-renal capsules smaller than natural, and remarkably hard; their surface very irregular and knotted. On section, the distinction between cortical and central parts was seen to be obliterated, and the whole converted into dense, yellowish, cheese-like substance, none of the natural structure being discovered.	Both.	Whole of these organs were diseased.	Tubercles in the lungs, which were in places breaking down.	4.
2.	Mr. Simon for Dr. Greenhow. April 5th.	Woman, aged 31.	The conjunctivæ clear, pearly. The whole of the uncovered surface of the skin of a dusky hue, as if from greenish pigment. This colour produced by a number of small specks, patches, and lines of deeper-coloured integument.	Supra-renal capsules converted into hard yellowish masses.	Both.	No appearance of cortical or medullary substance.	Tubercles in the lungs and peritoneum, &c.	7.

No.	Name of the Exhibitor and Date of Exhibition.	Age and Sex of the Patient.	Colour of the Skin.	General State of the Affected Capsule.	Whether both Capsules were involved or not?	Were the Affected Capsules wholly destroyed?	General condition of other Organs.	Number in foregoing list of cases.
3.	Dr. Wilks for Mr. Welford. May 17.	Man, aged 21.	It was not uniform, some patches being very dark indeed. Not exclusively limited to covered parts. Several dark olive-coloured patches existed on the shoulders, chest, and abdomen. Most marked discoloration on the integument covering the penis and scrotum, amounting almost to an ecchymosed appearance.	One supra-renal capsule was diseased, containing a small collection of cheesy matter, with a slight quantity of thin fluid in the centre. The organ wholly changed in structure from a deposition of firm albuminous and cretaceous deposit throughout its substance.	One organ only.	Wholly changed in structure.	Liver and kidneys congested.	10.

In the following Table (B), are arranged those cases in which "bronzing of the skin" was wholly *absent*, although more or less disorganization of the supra-renal capsules existed.

TABLE B.

1.	Dr. Murchison for Dr. Scurrah. Feb. 1.	Man, aged 36.	No discoloration whatever of the skin.	The right supra-renal capsule weighed one ounce and a-quarter, the left was rather smaller. The interior and greater part of both capsules was occupied by a mass of scrofulous deposit.	Both affected.	Greater parts of both affected.	Acute tubercular deposit in lungs, liver, peritoneum, &c.	5.

	Name of the Exhibitor and Date of Exhibition.	Age and Sex of the Patient.	Condition of the Skin.	General State of the Affected Capsule.	Whether both Capsules were involved or not?	Were the Affected Capsules wholly destroyed?	General condition of other Organs.	Number in foregoing list of cases.
2.	Dr. Markham. March 15.	Man, aged 36.	Not the slightest appearance of bronzing in any part of the skin.	The supra-renal capsules contained a quantity of low, fibrinous, calcareous, and cheese-like matter.	Both affected. One was five times larger than ordinary size; the other was somewhat smaller.	Not wholly affected.	Pericarditis.	6.
3.	Mr. Sibley. May 17.	Man, aged 66.	The skin not presenting any discoloration or unnatural appearance.	One supra-renal capsule, natural. The other was enlarged to double its size, chiefly increased in cortical direction. Distinction between cortex and medullary portion quite lost; the whole organ converted into firm, almost fibrous-looking substance. In parts, the tissue broken down into cavity.	Only one.	One organ completely destroyed.	Epithelial cancer of the tongue.	9.
4.	Dr. Coote. May 17.	Man, aged 23.	Without any discoloration of the skin.	Each supra-renal capsule weighed three-quarters of an ounce. They were the seat of a firm yellow deposit, nearly amorphous. In a few spots presenting a more natural appearance, traces of cortical tubes were found.	Both.	Structure almost entirely replaced by the morbid deposit.	Deposit (scrofulous), in the mesenteric glands—also in lungs. Emphysema of lungs.	8.

The case in the following Table (C), affords an example of "bronzing of the skin," which had been unaccompanied by any disease of the supra-renal capsules.

TABLE C.

No.	Name of the Exhibitor and Date of Exhibition.	Age and Sex of the Patient.	Condition of the Skin.	General State of the Affected Capsule.	Whether both Capsules were involved or not?	Were the Affected Capsules wholly destroyed?	General condition of other Organs.	Number in foregoing list of cases.
1.	Dr. Harley. Nov. 16.	Man, aged 66.	The skin of the face, neck, shoulders, and arms were almost uniformly of a dark colour; but over the trunk, and especially the abdomen, diversified by irregular white patches, from one to four inches in diameter. Slight pigment in conjunctivæ, and dark patch on lip. Slight jaundiced state of conjunctivæ also.	Both supra-renal capsules perfectly healthy—in size, form, microscopical character, &c.	Neither of these organs involved.		Diseased liver.	3.

Dr. JOHN W. OGLE, *17th of May*, 1859.

X. MISCELLANEOUS SPECIMENS.

INCLUDING MALFORMATIONS OF OUTWARD PARTS; EFFECTS OF POISONS; MORBID STATES OF THE BLOOD, SKIN, TEETH, ETC., ETC.; CASES OF DIPHTHERIA.

1. *A Dissected Specimen of Non-congenital Club-Foot, of Paralytic Origin, and of Fifty Years' standing.*

The limb was removed from a female, æt. 51, by Mr. Hester, of Oxford, on the 4th of October, 1858.

Distortion commenced during the earliest period of infancy: it was probably occasioned by paralysis, consequent on dentition. When she began to walk, the heel of the left foot could not be brought to the ground, and distortion increased gradually until the foot had assumed a vertical direction. Notwithstanding the distorted condition of the foot, she walked firmly and without pain, until six years ago, when she suffered from erysipelas of the leg. Ulceration followed, which extended over a large portion of the dorsum of the foot. The leg was rendered useless and unfit to bear the weight of the body; and the ulcer was painful and extending, and it could not be healed. Amputation was therefore performed.

The external characters of the distortion were such as are usually seen in a case of equino-varus of paralytic origin. The anterior portion of the foot was inverted and its inner margin was slightly raised. The dorsum was prominent and very irregular, the head of the astragalus projecting; the bone itself being thrust downwards and forwards. The four lesser toes were flexed. They had evidently formerly supported the weight of the body. The great toe was extended, and its extremity rested on the dorsal surface of the adjoining toe. The plantar surface of the foot was deeply arched. The os calcis was raised above its normal position (as is always observed in this form of distortion), the upper edge of the tuberosity being three-quarters of an inch above the extremity of the internal malleolus, and one inch above the tip of the external malleolus—(Woodcut 14).

I have noticed with more detail than I should otherwise have

done, the position of the os calcis, in consequence of the following statement by Mr. W. Adams, in Volume VIII. of the Society, relative to the position of this bone in equino-varus:—"The foot was very much bent upon itself from the transverse tarsal joint, and the effect of this condition—one of much more frequent

WOODCUT 14.

Represents the parts as they appeared on dissection.

occurrence than is generally described—is always to add to the apparent elevation of the tuberosity of the os calcis, and, in such cases, the os calcis is found, upon dissection, to deviate very slightly from its natural horizontal position. It was so in the

present instance as may be seen in the plate (Plate X. Volume VIII.), by noticing the relation of the tuberosity of the os calcis to the malleolus."*

If the illustrations here referred to be compared the one with the other, it will be manifest why I insist on the exact position of the os calcis in distortions of this nature. Both of these figures can scarcely be correct. That which is attached to this paper was executed by Mr. Bagg, and it is most accurate, as will be seen on comparing it with the original specimen, which is now in the Museum of the College of Surgeons.

The bones of the foot were softened and fragile. A very thin layer of cartilage alone remained to cover the articular surface of the astragalus; and the outer shell of the bone itself was no thicker than the cartilage; whilst the cancellous tissue was a mass of fat and oil, with some few spicules of bone interspersed.

All the muscles of the leg and foot were in an extremely advanced stage of fatty degeneration: those situated on the anterior aspect of the leg, being of a pale-yellow and fawn colour, had still the fasciculated appearance of muscle; whereas those in the posterior region were more agglutinated, and were not to be distinguished from a mass of fat. The tendons, also, were considerably diminished in volume.

The microscopical description of the muscles of the leg and foot was kindly undertaken by Professor Quekett; and the report, which is as follows, was made by Mr. Murie, of the College of Surgeons.

Extensor longus digitorum was composed almost entirely of areolar tissue; degeneration of muscular fibres was complete. No healthy muscular structure remained, but there was found a honeycomb structure of large fat globules, the interstices being filled with innumerable granules, and other fatty matter.

Tibialis anticus.—Transverse striæ were visible; but the greatest number of fibrils were filled with granular fatty molecules. The larger fibres broke into a series of squares, as though they were brittle. Between these, series of large fat globules were seen. In the lowest part of the muscle, which was more yellow and fatty in external aspect, few fibres could be distinguished, and in them striæ were not visible. The mass consisted chiefly of

* Vol. VIII., p. 396.

a meshwork of areolar tissue and fatty matter with cells containing crystals of margaric acid.

Extensor proprius pollicis.—No muscular striæ; fibres filled with oil globules; there existed much areolar tissue and large fat cells.

Gastrocnemius. — Muscular fibres abundant, striated and healthy; areolar tissue moderate; between the fibres, large fat cells, containing crystals, existed: the latter were very abundant; fat in granules in diminished proportions.

Soleus.—This muscle, as a mass, was like a lump of fat; yet here and there were portions of a deeper fawn colour. In these, healthy muscular fibres were seen in abundance, mingled with others, containing molecules of fat. One or two fibres exhibited a breaking-up into transverse laminæ, such as has been already described by Mr. Quekett, in Volume III. of the Society's "Transactions," p. 474, as "broken into short lengths."—Vide Pl. XII, Fig. 3. ibid. In some portions which were examined, there were not any large fat globules present; in others of a yellower shade, but few muscular fibres were found, and these contained oil molecules; but the mass chiefly consisted of areolar tissue and large fat cells, many of which contained crystals of margaric acid.

Tibialis posticus.—Few or no muscular fibres were found, but areolar tissue; fat cells, containing crystals of margaric acid, and oil globules.

Flexor longus digitorum.—The structure of this was nearly similar to that of the last-described muscle; there were traces of muscular fibres, but they were entirely converted into molecular fatty matter.

Flexor longus pollicis.—The outer aspect of the muscle was analogous to the preceding. One small patch of reddish muscle-like substance remained, which consisted almost entirely of healthy striated muscular tissue. Some fibres were in the first stage of fatty degeneration; oil globules were mingled among or between the fibres. In other portions of the muscle no striated fibres remained, and there was but slight appearance of muscular tissue; but areolar tissue and fat only. The few fibres which were found, contained molecular fatty matter.

Peroneus longus, consisted chiefly of fibrous areolar tissue,

together with large sized fat cells, containing crystals and other fatty matter. The muscular fibres were as though converted into a granular membrane.

Peroneus brevis presented very few muscular fibres, and no striæ were visible. It was full of oily matter; large globules, containing crystals, were arranged in honeycomb form, together with other fatty elements floating about.

Mr. Brodhurst, 16*th of November*, 1858.

---

2. *Case of "Typhoïd Fever," remarkable for the copious eruption of rose-coloured papules.*

The drawing exhibited to the notice of the Society, represented the appearance of the skin of a patient recently under my care in the Fever Hospital for "Typhoïd Fever." The patient was a female, æt. 20. The eruption was present at her admission on the eleventh day, and had not entirely disappeared until the thirtieth. The spots were remarkable for their great number, and it was calculated that at one time there must have been upwards of a thousand. Two hundred and sixty were counted, on the front of the chest and abdomen alone: and they were also very numerous on the back and extremities; there were even a few upon the face. They presented the usual colour of the so-called "lenticular rose-spots," were rounded, elevated, and disappeared completely upon pressure. A few of them were of unusually large size (one-fifth of an inch in diameter), and, here and there, two or more might be observed coalescing by their edges. They also came out in successive crops. Thus, on one day, two hundred and sixty were counted in front of the chest and abdomen, and each was surrounded with a circle of ink. Two days later, one hundred and sixty fresh ones had made their appearance, and many of the old ones were gone. After this there were observed, at intervals of two days, ninety, fifty, twelve, and three fresh spots, many of the old ones having faded as the new ones came out.

Dr. Murchison, 21*st of December*, 1858.

---

3. *Specimens showing the co-existence of Tubercle and Cancer. Cancer of the Uterus. Tubercle of the Lungs.*

The following case illustrates the possibility of the occasional co-existence of tubercle and cancer, a fact of which I have published an example in a former volume of the Society's "Transactions:"—H. T., a married woman, æt. 40, was admitted into St. Thomas's Hospital on the 7th of October, 1858. She stated that she had had three children, of which the youngest was sixteen years old, that the catamenia had ceased four years ago, and that she had enjoyed good health till within the last four months. During the latter period, marked symptoms of uterine disease had manifested themselves. The disease was found, on admission, to be carcinomatous; it progressed rapidly; and she died much emaciated on the 20th of November. There was no hereditary history of malignant disease.

Post-mortem examination.—Of ordinary stature; extremely emaciated; weight, four stone ten pounds.

Chest.—Pericardium and heart healthy. Both pleuræ presented numerous firm adhesions. These were most abundant on the left side; and on the anterior surface of the right lung was a little recent lymph. The lungs were of moderate size, and heavy, sparely crepitant, and thickly studded with distinct tubercular deposits. These latter were chiefly of the grey variety, but were frequently as large as tares and of an opaque white hue. Some were solitary, but the majority were clustered, the clusters varying in size, and being characterized, as usual, by a periphery of tolerably distinct tubercles and a centre of blackened, indurated fibroïd tissue. The disease was most advanced in the apices, and diminished thence towards the bases. In the left apex was a cavity about as large as a hen's egg. Larynx, trachea, and bronchial tubes healthy.

Abdomen.—Peritoneum healthy. Liver, spleen, pancreas, stomach and intestines, kidneys and supra-renal capsules, quite healthy. The ovaries, Fallopian tubes, and upper half of the body of the uterus were also healthy; but the lower portion of the body was infiltrated with an opaque white material; and the os and cervix uteri, with the upper third of the vagina, were ex-

cavated by a deep, irregular, and almost sloughy-looking ulcer. On making vertical sections through the diseased tissue, the base of the ulcer was found to consist of a white, opaque, tolerably firm growth, looking like cancer, but yielding no creamy juice, which infiltrated the surrounding structures, and varied in thickness from three-quarters of an inch downwards. Neither the rectum nor the bladder was perforated by it, but the mucous membrane of the latter was, in two or three situations, adherent to hemispherical projections of the growth.

Microscopical examination.—The growth forming the base of the uterine and vaginal ulcer was found to present all the microscopic characters of epithelial cancer. It displayed numerous more or less complex laminated capsules, many of the thick-walled cells, which have some resemblance to ova, together with the ordinary oddly-shaped epithelial scales, degenerated cells, and nuclei. The tubercle-like deposit in the lungs presented the appearances commonly observed in such formations. It consisted of imperfect and broken-down nuclear bodies, and abundant granular matter, embedded in a greater or less amount of fibroïd tissue, which displayed distinct traces of the original lung structure. But there were no appearances that could be looked on as cancerous; and certainly not the least trace of that form of cell-growth which characterized the uterine disease.

Dr. Bristowe, *4th of January*, 1859.

---

4. *Suicidal Poisoning by Aconite.*

Previous history.—J. H. D., æt 58, a gardener, had suffered from fistula in ano for some time previously; owing to this, and to the pressure of adverse circumstances, he had become despondent, and several times expressed intentions of suicide.

About nine P.M., on the 10th of July, 1858, after deliberately cutting up with a penknife a root of aconite which he had dug up for the purpose, he swallowed a quantity of the fragments, and having done so, smoked his pipe as usual and went to bed. About ten P.M. he was heard to utter "a horrid noise as if in a fit." He was found in convulsions; medical assistance was at once sent for, and a quantity of salt-and-water administered. During

the two hours following he had a succession of paroxysms, occurring at intervals of about twenty minutes, which had the following character. Each paroxysm lasted for several minutes, and was ushered in by a shuddering noise; immediately after which the arms became rigid, or were raised with an agitated movement above the head, which was thrown back, and the lower limbs were extended rigidly. The features were distorted sometimes to one side, sometimes to the other. The eyes were usually closed (the state of the pupils not being observed). There was no general convulsion; the surface was covered with a profuse perspiration, and the countenance pale. Consciousness was throughout unimpaired; he recognized surrounding persons during the paroxysms, and made frequent attempts to address them, being apparently prevented from doing so by spasms of the respiratory muscles. During the intervals, he spoke intelligently as to the motives which had actuated him, and expressed his surprise at the violence of the symptoms.

The salt-and-water produced copious and repeated vomiting, he himself aiding the effect by tickling his throat with his finger, &c. About half-past twelve A.M., before any further remedies had been applied, the paroxysms ceased. He became completely collapsed, the surface was cold and moist, the pulse was almost imperceptible but markedly intermittent; the pupils were dilated, the intelligence was perfect. He died shortly before one A.M., having expressed himself connectedly, and articulated perfectly, five minutes before.

Post-mortem examination, fourteen hours after death. External appearances.—Surface pale, with livid discoloration of dependent parts; some rigidity of muscles of the calves, the rest of the muscles flaccid.

Head.—Dura mater natural; arachnoïd covering of convolutions somewhat congested; sub-arachnoïd fluid slightly excessive; some opacity of intergyral spaces; sectional surfaces of brain not vascular; brain-substance moist; slight excess of liquid in ventricles.

Thorax.—Lungs filled the thoracic cavity completely, their anterior margins overlapping. On opening the pericardium it was observed that the left ventricle of the heart was firm and resistant,

the right flaccid. The organ was opened *in situ;* the right ventricle was empty, but on replacing the heart in the pericardium, a large quantity of perfectly fluid-blood entered it from the auricle; about a drachm of blood contained in the left ventricle was also fluid.

Lungs unnaturally bulky; their substance crepitating unusually under the finger; they exhibited over their whole surface the appearance of vesicular emphysema, most marked at their anterior and inferior margins. In some points the lung tissue seemed to be ruptured by the coalescence of several enlarged vesicles. The sectional surfaces exuded everywhere on pressure abundant, frothy, sero-sanguineolent fluid. The bronchial mucous surface was congested, and more rugose than natural, the longitudinal rugæ being especially more marked.

Alimentary mucous membrane.—Mucous membrane of tongue redder than natural at base; congestion of epiglottis and of epiglottidæan folds; mucous membrane at upper end of œsophagus somewhat redder than natural, this redness becoming more intense towards the lower end. The longitudinal rugæ more marked than usual, and the solitary glands large and projecting.

The stomach contained about three ounces of glairy, red fluid, in which floated numerous fragments of aconite root. The mucous membrane was universally intensely congested, the congestion being most intense at the great curvature, where it assumed the appearance of capillary extravasation. There was no ulceration. The duodenum contained a fluid entirely similar to that in the stomach; its mucous membrane intensely congested at the pyloric end became progressively less so downwards, the congestion entirely ceasing at the upper part of the ileum, which contained also a glairy fluid, not so sanguineolent as that of the stomach. The large intestines contained fæces; their mucous membrane was congested at the transverse colon, healthy in other parts.

Liver, spleen, and kidneys congested, but otherwise healthy.

Dr. Sanderson, *4th of January*, 1859.

---

5. *A Report on Malformations of the Teeth, as indicative of Diathesis.*

In the last volume of the Society's "Transactions" I described

certain peculiarities in form, size, &c., of the permanent teeth, which I believed to be consequent upon inherited syphilis. Since then I have made numerous additional observations on the subject, which, while they have, in a general way, confirmed my previous views, have also further developed them and given them more precision.

Although it has been long a matter of general observation that deviations from the normal type of teeth, both in form and size, are very common, but few attempts have yet been made to employ these deviations as helps to the diagnosis of diathesis. In several communications made to the Pathological Society during its past session, I have endeavoured to take a wider range, and to include the whole question of malformation of the teeth as indicative of diathesis, not restricting myself, as heretofore, to that small department of it which has reference to hereditary syphilis as one amongst many causes. It would be profitless to the reader were I here to repeat descriptions of all the casts and sketches exhibited to the Society, and I have therefore preferred to condense my deductions from the whole under the following heads.

A. *Inherited Peculiarities of form, &c.*—It is often observed that the teeth in different individuals of the same family present remarkable similarities in type—for instance, in form, colour, liability to caries, &c. The same observation also holds good in respect to certain malformations which are undoubtedly due to hereditary transmission. I have repeatedly seen large craggy teeth, of exceedingly irregular surface, present in father and son, or in two or more brothers or sisters. A condition of horizontal notching, in which a furrow extends in a horizontal line across all the front teeth, oftenest in the lower ones, but occasionally on either or both sets, is also not infrequent as a family peculiarity. From malformations of this kind little or nothing can, of course, be deduced as to the temperament or diathesis of the patient. Their recognition is important only in order that we may distinguish them from others which, in this respect, are of much more value. It may be noted, then, that these teeth are usually of hard structure, and do not either become carious or wear prematurely. This is especially the case with "craggy" or "rocky" teeth, as they are called. They retain their peculiarities through a large part of their pos-

DESCRIPTION OF PLATE IX.

The Figures illustrate Mr. Hutchinson's case of Syphilitic and Non-syphilitic Malformations of the Teeth, p. 289.

Fig. 1. The lower incisors of a girl, aged 15, the subject of inherited syphilis. The teeth are very short, rounded, and peg-like, with wide interspaces. This sketch shows the most typical condition ever exhibited by the lower set. It is a further stage of what is seen in Fig. 2 of Plate VIII.

Fig. 2. The milk teeth (upper set) of a syphilitic child, aged nearly three. The necks of the four incisors have been attacked by circular caries, which has wholly spared the canines. The extremities of the lateral incisors have already fallen away, and those of the centrals will soon follow.

Fig. 3. The milk teeth (upper set) of a girl of five, the subject of inherited syphilis. The central incisors have been destroyed by caries, and their stumps exfoliated, and of the laterals only the stumps remain. The canines are perfect. The sketch shows a further stage of progress of the changes illustrated in Fig. 2.

Fig. 4. The temporary canines (upper and lower) of a boy, aged 9, the subject of inherited syphilis. They are remarkably symmetrical, and all of them show a central, tusk-like projection, the result of a peculiar circumferential wearing away (not caries). See pp. 293 and 294.

Fig. 5. The upper permanent teeth of a boy aged 11, not syphilitic. The teeth are somewhat honey-combed, of bad yellow colour, and have peculiarly thin and narrow edges. They differ from the syphilitic type, in all possessing, in greater or less degree, the same features, instead of each pair having its own peculiarities. Possibly the result of a mercurial course in infancy.

Fig. 6. Two upper permanent central incisors, not syphilitic, but of the type known as "craggy teeth." They are larger and wider than syphilitic teeth, not notched, and of much harder structure. (See p. 289.)

Fig. 7. Thin-edged and broken teeth, not syphilitic, from a woman, aged 20. The notches in the upper ones differ markedly from those shown in Figs. 1, 3, and 4 of Plate IX. In these they result not so much from the softness and original malformation of the teeth as from their preternatural thinness and brittleness. Near the edges of the lower set a horizontal line of notch is seen to extend.

Fig. 8. The permanent front teeth of a boy, aged 15, who had taken much mercury in infancy. The teeth are all of them of yellow colour, somewhat pitted in their surfaces, and very thickly coated with tartar. Near the edges of the lower set, a horizontal line extends similar to that adverted to in Fig. 7.

Fig. 1

Fig. 3

Fig. 2.

Fig. 4

Fig. 6.

Fig. 5

Fig. 7.

Fig. 8

Lear Adams inc. Tuffen West sc.

W. West chromolith

sessor's life, with an abrupt definition of outline, quite different from what is observed in the soft-structured teeth, whose malformations are due to arrest of development in infancy. An illustration of craggy teeth, though not of one of the commonest varieties, is given in Plate IX., Fig. 6. It shows the central upper incisors so affected. It may be observed here, however, that hereditary peculiarities of form are quite as often seen in other teeth as in that particular pair; whilst, as I shall presently have to show, they are the two which are the test-teeth as to syphilis.

B. *Mal-nutrition in Infancy as a cause of Dental Malformations.*—That delicate, ill-nourished children are very liable to early caries of their teeth there can be no doubt. That teeth liable to premature caries are often remarkable for their clear, pearly aspect, is also, I believe, a well-established observation. Such teeth, however, are not malformed: their deviations from the healthy type appear to concern structure and not form. Supposing an infant, during its first year, to be puny, ailing, and feeble, without suffering from any degree of inflammation of the mouth, either syphilitic, mercurial, or idiopathic, in what way will such an illness affect the development of the permanent teeth? I believe we have no evidence whatever in support of the opinion that it would exert any greater influence upon the teeth than it would upon the bones, the features, and the various internal viscera whereas, as regards the latter, it is a well-known fact that such infants often develop, ultimately, into remarkably healthy adults. All the various varieties of dental malformation, excepting those due to hereditary tendency—"the honeycombed or pitted teeth," those with vertical or those with horizontal notches, the thin-edged teeth, the dwarfed and peg-shaped teeth—are, I suspect, much oftener due to some transitory attack of inflammation of the alveolus, during the first year of the child's life, than to any interference with the nutrition of the whole body. We are speaking, of course, of the permanent teeth only. In attempting to conceive of the manner in which inflammation of the alveolus may affect these, it is necessary to bear in mind that they are parts of the dermal skeleton, and therefore closely connected with the mucous membrane of the gum, to which they are immediately

subjacent; that they are superficially placed in a ridge of gum, the two sides of which present a large extent of surface, which, during stomatitis, may become congested and swollen; and lastly, that from the fifth month of intra-uterine life until the age of two years, the incisor teeth exist in the state of soft uncalcified pulp. These facts borne in mind, it is easy to realize how any passing attack of stomatitis, by whatever cause induced, may not "crack nature's moulds," but so spoil the shape of them as to materially alter that of the soft impressible structures inclosed within them. Not only, also, are the sacs of the permanent teeth at this time liable, by inflammatory tumefaction, to injuriously compress the dental pulps, but the nutrition of the latter must, during such a condition, be very seriously interfered with. It is in such processes, then, I may repeat, that we ought to seek the explanation of dental malformations, rather than in influences affecting the nutrition of the body generally, but not specially that of the gums. With these remarks we shall, then, leave the subject of constitutional influences, and proceed to consider the local and far more potential ones. These latter may be classified as—1. Inflammation of the gums induced by mercury; 2. Inflammation of the gums occurring in thrush, idiopathic stomatitis, &c.; and 3. Inflammation of the gums induced by inherited syphilitic taint.

c. *The exhibition of Mercurials in Infancy as a cause of Dental Malformations.*—It is a well-known fact that mercury given to young children very rarely affects the mouth. Dr. West, and many other observers, have given very important evidence on this point. Why it should not, considering the certainty of its action in this direction in adults, it is difficult to say. Nor can we indeed doubt, that occasionally it does so act, even in the youngest infants. It is also very possible that it may induce congestion and tumefaction about dental pulps in many cases in which no ptyalism obvious to patients, nurses, or medical attendant occurs. I have given in Fig. 8 of Plate IX. an illustration of a state of the permanent teeth which I have repeatedly observed in those who, in infancy, had taken long courses of mercury. The teeth are thin, especially at their edges, of bad, yellow colour, and are thickly coated, the lower ones especially so, with tartar. The latter condi-

tion is, I suppose, due to disordered secretion on the part of the salivary glands, induced by the mineral. With such teeth the gum is usually seen to be leaving the teeth at their necks, and to be more or less congested. The teeth of patients with a mercurial history often show the normal serrations of undue distinctness; and sometimes there is an appearance of thinning of the central part of their free edges in a crescentic form. When this latter condition occurs, the diagnosis between mercurial and syphilitic teeth becomes difficult; but the fact that the latter are but rarely much coated with tartar will generally help the observer to a right conclusion. The condition of pitting of the enamel, characteristic of what are known amongst dentists as honeycombed teeth, may very possibly be due to the employment of mercury. It is rare in the subjects of inherited syphilis.

All the above remarks apply to the permanent set only. I am not familiar with any peculiar states of the milk teeth, other than their occasional exfoliation or decay, which are induced by mercury.

D. *Thrush, Idiopathic Stomatitis, &c., as causes of Dental Malformations.*—It is not probable that either in true thrush (*i.e.*, the aphthous stomatitis of young infants), or in the follicular or ulcerative forms of idiopathic stomatitis, the inflammation extends deeply. In certain instances, however, it may do so, and in such these affections may interfere with the development of the teeth. I have not been able to distinguish any particular type of malformation, as probably induced by these diseases; but of the so commonly observed varieties of honeycombed, thin-edged, and serrate teeth, it is very likely that some acknowledge these affections as their cause.

E. *The Stomatitis of Hereditary Syphilis as a cause of Dental Malformations.*—No fact is better established in the clinical history of hereditary syphilis than that infants suffering from other well-marked symptoms, rarely escape an attack of inflammation of the mouth. Coincident with severe snuffles, rash on buttocks, and general atrophy, there usually occurs a more or less prolonged stomatitis, in which the mucous lining of the cheeks

and lips, and the gums are all affected. This attack usually occurs between the ages of one and six months. It is usually subdued quickly by the judicious use of mercury, but otherwise may have a prolonged duration. The gums are often greatly swollen, and in proof that the dental structures do really suffer from it, we occasionally see the crowns of the milk teeth, portions of alveolus, &c., exfoliated in its course. Two instances of the latter event, were recorded in the last volume of the Society's "Transactions," in neither of which had mercurials been given, the disease and its consequences being solely due to syphilitic poison. In this disease we have, then, the conditions existing by which, as seen above, malformations of the teeth are usually caused. Beyond the expectation, that in the subjects of inherited syphilis the permanent teeth should exhibit some peculiarities, *à priori* inference cannot carry us. There is, it must be admitted, but little reason for believing that the malformations induced by syphilitic stomatitis, should differ from those by mercurial or those by idiopathic stomatitis. We know, indeed, that the rashes of syphilis differ in certain peculiarities from the non-specific affections of the skin, and it is possible that the syphilitic stomatitis of infants may also so differ from the idiopathic, as that a notable difference in the induced dental peculiarities may be the result. Further than this, however, we cannot go by conjecture. Whether such is the clinical fact or not, can be determined only by carefully collected evidence. That it is, and that the subjects of inherited syphilis bear about with them, in certain peculiar malformations of the permanent teeth, data, by which their prior history may in a large number of instances be detected, I venture without hesitation to affirm. The number of cases which I have collected bearing upon the question has now been considerable, and my confidence in the correctness of the conclusions is greatly augmented by the fact, that they have obtained the assent of the entire surgical staff of the Ophthalmic Hospital, as well as that of many other exceedingly competent observers. It is at Ophthalmic Hospitals that the subjects of inherited syphilis of an age to have cut their permanent teeth are chiefly to be met with, since they come there on account of attacks of interstitial keratitis. Most of the cases upon the observation of which I ground the following

general conclusions as to the teeth of hereditary syphilis, have been already recorded in more or less detail in the Journal of the Ophthalmic Hospital, to which the reader is referred who may wish to pursue the subject.

The *temporary teeth* in syphilitic children do not present any peculiarities of form; they are, however, often of bad colour, and are very liable to early decay. The central upper incisors are the first to suffer from caries, and often crumble away under its influence, within a year of their being cut. The upper laterals soon follow, but the canines very rarely indeed. The caries generally attacks the neck of the tooth, and rapidly eats through it, causing the crown to drop away, soon after which the fang comes out. Children who have suffered severely from syphilitic stomatitis, are often toothless as regards the whole of the upper incisors, from the age of two years till the permanent set are cut. In Fig. 2, Plate IX., this form of circular caries of the necks of the upper central incisors is well shown. The child was only two years of age, and was the undoubted subject of syphilis. In Fig. 3 of the same Plate, a later condition is shown; both the central incisors having come away, and only the stumps of the lateral ones remaining. Occasionally, the lower incisors suffer in the same way, but far more seldom than the upper ones. The deciduous canines as above remarked, rarely either become carious or drop out. They are, however, liable to a curious kind of circular wearing-away, which reduces them to the condition shown in Fig. 4 of the same Plate. A sort of tusk or peg remains in the centre of each tooth; the process of circular attrition having commenced a little above the level of the dental neck. This condition I have only seen in five or six patients, and in all these it was symmetrical on both sides, and in both upper and lower sets. I have never yet seen it excepting in syphilitic children. It is not usually produced in any very marked degree until about the age of from six to eight. I have seen quite recently an approach to it in one of the molar teeth of a syphilitic child. Prior to the last-mentioned observation, I was inclined to attribute this circular attrition of the canines to some peculiar motions of the jaw, acquired by the child in consequence of the loss of the incisor teeth. Whatever its mechanical and immediate cause may be, there can be but little

doubt that these teeth must be of abnormal softness to permit of such peculiar wearing-away of their outer layers.

As bearing upon the value of this condition as indicative of syphilitic antecedents, I may mention a case, the particulars of which were supplied to me by Dr. Hess, of Finsbury Square. Having heard a paper read by myself before the Hunterian Society on this subject, in which this peculiar state of the temporary canines was described; and having listened with great incredulity, Dr. Hess determined at once to examine the mouth of a child, whom he knew to be the subject of venereal taint. He had attended the parents of the child for syphilis before its birth, and subsequently treated the infant itself for the same disease. He found the canines in exactly the condition I had described, and was good enough in sending me a report of the case, to add a pen-and-ink sketch of the outline of one tooth, which showed remarkably well the central peg.

Asking the reader's attention to the fact first adverted to, that of the temporary set, the upper central incisors suffer most often and most severely, I will now pass on to the conditions of the *permanent teeth* induced by hereditary syphilis.

We shall find here, again, that the stress of the disease falls in the upper central incisors. I cannot too strongly insist, that this pair are the test teeth as regards hereditary syphilis. Other teeth may, and most commonly do, furnish corroborative testimony, but it is in the upper central incisors that peculiarities are often observed, which I have never yet seen in similar degree, excepting in the subjects of the disease in question.

In all the figures in Plate VIII. these peculiarities are exhibited, but the typical and more common ones are seen only in Figs. 1, 2, 3, and 5. These sketches show the upper incisor teeth short, narrow, their angles rounded off, and their edges exhibiting a broad, shallow notch. Usually, one or two teeth converge towards each other; in other cases they stand apart with an interspace, or they even diverge. The single broad notch, of greater or less degree of depth, is hardly ever wanting. The teeth are almost always of bad colour. They may, however, in some instances, be of very fair whiteness. On looking carefully at the surface of the notch, there is almost always evidence of wearing, that is, the enamel

DESCRIPTION OF PLATE VIII.

The Figures illustrate Mr. Hutchinson's case of Syphilitic Malformations of the Permanent Teeth, p. 294.

Fig. 1. An upper permanent central incisor of a boy, the subject of inherited syphilis. The tooth has been very recently cut, and shows a broad vertical notch, in which are several small projecting spines (the sole remains of the atrophied mid-lobe).

Fig. 2. Two upper and four lower incisors (permanent) of a girl, the subject of inherited syphilis, all but recently cut. The upper teeth are narrow from side to side, at their edges, and show a thin middle lobe, bounded above by a crescentic line. The lower teeth are rounded, and show foliated extremities. All the teeth are small, and spaces occur between the adjacent ones. In the upper ones, the crescentic thin mid-lobe, and in the lower ones, the foliated extremities will, before long, break away, and leave the teeth in the states shown in Fig. 3, Plate IX., and Fig. 1, Plate VIII. respectively.

Fig. 3. The central upper incisors of a lad, aged 15, the subject of inherited syphilis. The teeth are short, convergent, narrow from side to side at their edges, and show in each a vertical notch.

Fig. 4. In these teeth, almost similar characters as in Fig. 3 are seen. The notches are, however, less deep, whilst the narrowing from side to side is very marked.

Fig. 5. The upper incisors of a girl of 17, the subject of inherited syphilis. There is a wide space between the central ones, and both these teeth, although of nearly normal length, are narrow, and show deep vertical notches. The lateral incisors are, as is usual, of normal size and form. These teeth are much less typical of hereditary syphilis than those in Figs. 3 and 4.

Fig. 6. The upper incisors and canines of a girl of 12, the subject of hereditary syphilis. The right canine is a temporary tooth: all the others are permanent. The incisors are remarkable for great inequality of size and difference of form. The right central incisor is very small and notched. The right lateral incisor is of normal size, all the others much below it.

Fig. 7. The upper permanent incisors of a boy of 12 (syphilitic). This sketch shows a condition of extreme dwarfing of the central ones, which, although cut four years ago, have never grown higher than a line or two above the gum.

Fig. 8. An exceedingly well-characterized set of syphilitic teeth (upper and permanent), from a girl aged 16. The central incisors are dwarfed, narrow, and notched; the lateral ones of normal size; and of the right canine, the apex is replaced by a notch, in the centre of which is a small tubercle.

Fig 1

Fig 2

Fig 5.

Fig 3

Fig 4

Fig 6



Fig 7

Fig 8

Lenn Aldous del. Tuffen West sc.

Wilbert chromo imp.

is not perfect at the scooped-out border of the tooth. I believe that these teeth rarely present the notch at the time of their being cut. In Fig. 1, is seen one such just cut; and in the notch are some small spines, which would doubtless soon break away under the effects of use and leave the tooth bearing a most close similarity to those seen in Fig. 4. In a majority of cases, however, these teeth, when they come first through the gum, show, instead of a notch, a central projecting lobe, as seen in Fig. 2. Above the base of this lobe, which is very thin, extends a crescentic line, marking out the size which the notch will have when, as is quickly the case, the thin central plate has been broken or worn away. I have seen one case in which I believe that the teeth had been cut with the central notch already well formed, and without either spines or any appearance of projecting middle lobe.

The upper lateral incisors vary greatly in the conditions which they present. Sometimes, but rarely, they, like the central ones, show vertical notches; at others, they are unusually long and thin, more like ivory pegs than teeth. As a rule, however, they deviate but little from their normal type.

Amongst those from which valuable corroborative testimony, as to the nature of the case, may be obtained, are the four canines and the lower set of incisors. In syphilitic mouths the canines, as a rule, show blunted extremities, in the centres of which are seen single little tubercles. This state of things is shown in the right-hand canine of Fig. 8. It is almost always present in syphilis; but it is very frequent also in cases in which no suspicion of such disease exists. The lower incisors hardly ever show notches in their borders. Sometimes their central lobes are peculiarly elevated, and by an excessive development of their tubercles and serrations, they come, as in the appended Woodcut, to resemble the teeth of certain fishes. The condition exhibited in Fig. 2, is not very infrequently seen in teeth which have not been long cut. After a time, the foliated extremities there shown break away, and leave the teeth shortened and peg-like, as is seen in the set sketched in Fig. 1 of Plate IX. The peculiarly broken-up, almost wart-like extremities just alluded to, are not out-growths, but rather an atrophied condition of the crown of the tooth, and in them traces of the normal trilobate

division are generally recognizable. The same remark applies to the little tubercles seen in the depressed apices of the canines, which, also, are not outgrowths, but merely projections, left as such by the non-development of the circumferential layers. All the peculiarities of syphilitic teeth are, indeed, easily explained as arrests of development. In Fig. 7 of Plate VIII. the arrest has been

WOODCUT 15.

Represents the upper and lower teeth, partly permanent and partly of the first set. Syphilitic and fairly typical.

most unusually complete, far more so than I have ever seen in any other instance. The teeth sketched are the permanent upper central incisors of a lad of fourteen, and had been cut for upwards of four years. After being cut, they had never grown higher than about a line above the level of the gum, but had remained in the stunted, discoloured condition there seen. The case is interesting, as affording further proof that the greatest severity of the disease falls upon the pulps of the upper central incisors.

The recognition of the subjects of inherited syphilis, by means of their incisor teeth, can only be effected, with any confidence, between the ages of eight and from twenty-five to thirty. Later than thirty-one the notches have generally been worn level, and the teeth merely resemble those of a much older person. I have seen teeth preserving their peculiar syphilitic stamp in patients of middle age, but in a large majority of instances such is not the fact.

Before concluding this report, I wish to draw attention to certain fallacies which may lead to mistakes in the attempt to diagnose hereditary syphilis by means of the permanent teeth.

1. The teeth may be notched from accidental attrition, such as that of smoking. Smokers who bite their pipes usually wear a

notch either between the canine and lateral incisor, or between the canine and first bicuspid, such notch not being in the centre of any one tooth. Now and then, however, notches will be seen in the central incisors due to the attrition of a pipe. In such cases, it will be noticed, however, that the teeth, in other respects, are of normal type—that they do not show that rounding off of their angles which is almost invariably present in syphilitic teeth.

2. The notch may be the result of accidental breakage.

3. A notch, somewhat resembling that of the syphilitic type, is now and then seen in "craggy" teeth. If the reader will refer to Fig. 6, Plate IX., he will understand how this may be the case. The thin borders of the teeth there shown might easily break away and leave a notch. It must be remembered, however, that syphilitic teeth are generally of soft structure, and look rounded and worn; whilst one main feature of craggy teeth is, that they look hard, and are of rugged exterior. Whenever a tooth which has borne several years' wear looks hard and rocky, and has abruptly defined angles about it, whether of breakage or otherwise, the inference is that it is not syphilitic.

It would be tedious, indeed almost impracticable, here to introduce such detailed particulars of the cases (more than seventy) in which I have observed the peculiarities of dental malformation above-described, as would enable the reader to form his own opinion as to whether the patients were really the subjects of inherited syphilis. I must, therefore, content myself with stating, as concisely as I can, my reasons for that belief. They are as follows:—

1. Because, in cases of interstitial keratitis, a disease which I have elsewhere endeavoured to prove to be of hereditary syphilitic origin, these peculiar teeth are almost invariably met with.

2. Because I have hardly ever seen teeth of well-characterized syphilitic type, excepting in patients who either had keratitis at the time they were under observation, or had had it at some former one.

3. Because these teeth are usually found coincident with the physiognomy of hereditary syphilis.

4. Because, in a large majority of cases where these teeth are seen, a clear history of infantile symptoms is obtainable.

5. Because, in not a few instances, the parents of children with these teeth have spontaneously informed me that they had suffered from syphilis prior to the child's birth, and that the latter had also been treated in infancy for the same.

6. Because I have repeatedly seen these teeth in patients the known subjects of hereditary syphilis, but who had never taken mercury.

7. Because I have often examined the teeth of those, not the subjects of syphilis, who in infancy had taken courses of mercury, without ever once finding the syphilitic type of teeth at all closely simulated.

8. Because I have repeatedly ventured to pledge myself to a diagnosis of hereditary syphilis founded solely on the state of the teeth, and subsequently found that the patient's history placed the correctness of the opinion beyond a doubt.

9. Because the teeth described above are not met with in subjects of any of the forms of struma, properly so-called. Thus the teeth of phthisis have long been known to be remarkable for their brilliant pearly-whiteness and fine form; and out of thousands of cases of strumous varieties of ophthalmia (*i.e.*, the ulcerative, pustular, &c., superficial and not interstitial), in which I have looked at the teeth, I have never once seen them of marked syphilitic type. A similar statement to the last I may also make as regards numerous cases of true glandular struma, in which I have examined the teeth, and found them usually of large size and good form.

10. Because the same clinical evidence which has been satisfactory to myself has also proved convincing to many other much better observers, including the whole surgical staff of the Ophthalmic Hospital.

Most of my cases have been subjected to the scrutiny of my friend, Mr. Alfred Coleman, of Finsbury Square, whose well-trained observation, as a practicing dentist, in all that relates to the teeth, peculiarly fitted him to correct any errors into which I might otherwise have fallen. To his assistance I am very largely indebted, and have much pleasure in acknowledging the obligation. Mr. Salter, of New Broad Street, has also examined a certain number

of my cases, and although very sceptical at first, now considers my chief conclusions as well-grounded. To him I owe several very valuable suggestions, which I took advantage of in the prosecution of the inquiry. I am informed that Mr. Paget has recently had under observation, in St. Bartholomew's Hospital, some cases strongly confirmatory of my conclusions.

Mr. HUTCHINSON, 18*th of January*, 1859.

---

6. *Peculiar Condition of Human Skin.*

The portions of human skin exhibited were taken from a body found by Mr. F. Buckland in the vaults of St. Martin's-in-the-Fields. The skin was dried up to the state of thick parchment, and very much resembled the bark of a tree. It was here and there elevated into small pyramidal-shaped masses, the apices of which exhibited a white point. The specimens shown were taken from the backs of the fingers. Mr. Buckland stated, that they were pretty numerous on the forehead and other parts of the body, which was dried up to the state of a mummy, having been buried without lead in a deal coffin full of sawdust.

Mr. Quekett, conservator of the Museum of the Royal College of Surgeons, kindly examined these pyramidal-shaped growths under the microsccope, and reported that they were decidedly vegetable; being probably a species of fungus, which had grown from the corpse, when in a state of putrefaction.

Mr. FRANK BUCKLAND, 2*nd of March*, 1859.

---

7. *An Inquiry into the existence of Amylaceous Compounds in the Human Body.*

Being anxious to satisfy ourselves with regard to the accuracy of Professor Virchow's statements as to the existence of cellulose in the human body, we have carried out a joint investigation of the subject, and embody the results in the following communication.

Though it be scarcely desirable to reproduce in detail investigations so well-known as those to which we refer, we find it necessary to make a preliminary statement of the cardinal points

to the examination of which our labours have been devoted. These are, briefly; the alleged discovery in the body of a substance resembling in its properties vegetable cellulose; 1. *In* health, constituting the so-called corpora amylacea of the brain; 2. *In* disease, constituting the deposit in the waxy degeneration of the liver, spleen, kidneys and other organs.

With the above-stated object, we examined in the first place the effects of iodine, alone or combined with other reägents, upon various forms of vegetable starch and cellulose; and subsequently compared them with the effects of the same reägents, similarly applied, upon well-marked specimens of the animal products. We did not, however, neglect to avail ourselves of such directions as are furnished by Professor Virchow himself, or to employ such modifications of method, as from time to time suggested themselves.

1. In starch, obtained from wheat, rice, and the potato, we found the grains assume, on the application of iodine, a blue (or purplish-bluê) colour, which rapidly increased in depth, until an almost black colour was produced. Sulphuric acid, either concentrated or somewhat dilute, being added, the grains swelled, became less intensely coloured, and covered the field of the microscope with their collapsed capsules and richly-tinted extravasated contents. Where sections of tissues containing starch were thus treated, the starch in the central portions exhibited a reddish-purple colour in marked contrast with the deep blue (or purplish-blue) of the edges. This appeared to us to result from a less complete, or perhaps modified action of the reägents on these parts.

Results exactly similar followed the use of Schultze's solution.

Examined by polarized-light, the grains invariably exhibited the characteristic cross.

2. Cellulose, from the turnip, onion, and starchless parts of plants.

On the first addition of iodine, no colour was exhibited by the cellulose (the cell-wall) while any portions of the lignine (the secondary deposits within the cells and ducts), contained in the section became tinged with a brownish-yellow colour. Dilute sulphuric acid, even after many hours' contact, failed to develop in this any trace of colour; but the strong acid immediately pro-

duced an intense blue tint, exactly like that produced in starch by the same means. With Schultze's solution the like results were obtained. The central parts of sections showed the same reddish-tint as before. In both cases the tissue became swollen and structureless before the colour was obtained.

3. The corpora amylacea of the brain. These bodies were very decidedly affected by iodine alone, assuming a dark reddish-black colour, which rendered them very prominent among the other nerve-tissues. On the addition of sulphuric acid they became large and soft, assumed a reddish-violet tint, almost identical with that noticed in the interior of the sections of vegetable tissue. The same reactions were afforded with Schultze's solution.

These bodies presented no cross when examined by polarized light, did not appear to be laminated, and, when acted on by sulphuric acid, melted away at the margins.

4. Waxy degeneration.

Sections of well-marked specimens of the waxy degeneration in the liver, spleen, and kidneys were next so submitted to examination. These, immediately on the application of iodine, showed, principally at their edges, a decided tint, varying according to the strength of the solution, and the amount used, from a yellowish-red or melon colour, to a deep reddish-brown, very like that of strong solutions of iodine.

Sulphuric acid, whether applied pure or dilute, for a short or for a long period, effected but little change, excepting to render the tint after a time lighter, without altering its character. In some cases, a bluish edge-tint was produced when the sulphuric acid was first added. This was evidently due to the precipitation of iodine in a molecular form, and almost always occurs when sulphuric acid comes in contact with iodine-solution and animal matter. No tint at all approaching the starch or cellulose tint was obtained during the course of several hundred experiments. With Schultze's solution the same colour was obtained as with iodine alone.

Similar experiments were made upon the same organs in a healthy condition, but here the colour produced was only a faint-yellow, scarcely deeper than that of the surrounding fluid.

5. Various pathological products were examined in a similar

way. These included the fibroïd tissue of cirrhosed liver, the fibrinous effusion of pleuritis, the grey induration-matter deposited in the lungs in cases of chronic phthisis, tubercle itself, cancerous material, coagulated fibrin, and the fibrinous submucous infiltration of the epiglottis in cases of diphtheria.

In most of these, only a faint-yellow colour was obtained.

In the diphtheric effusion, and in the villi of a villous cancer, a colour approximating to that of the waxy liver was produced, the resemblance being far closer than that between any specimen of the waxy liver, and the true starch or cellulose colour.

The conclusions at which we have arrived are :—

1. That the corpora amylacea approach very closely in their chemical reäctions to starch, being coloured at once by iodine, and behaving in most respects as starch does after the addition of sulphuric acid; that their being coloured at once by iodine separates them from cellulose, while the absence of a cross when viewed by polarized light, and the red-black instead of blue-black tint which they assume on the addition of iodine, alone separate them from starch.

2. That the material constituting the waxy deposit found in the liver, spleen, and kidneys, exhibits decided and well-marked reäctions with iodine, but that they do not correspond with those of starch. The immediate production of the colour when iodine alone is added, the reddish-brown character of the tint, the little alteration after the addition of sulphuric acid, are all points of distinction between this and cellulose. Yet this does not alter the fact of a definite iodine-reäction belonging to the so-called waxy substance, as well as to the diphtheric effusion, and the villous cancer. Like other substances—as, for instance, lignine—it may possess its own proper iodine-reäction, without partaking in any degree of the nature of amylaceous matters, and, from its microscopic appearance and general character, we are inclined to believe it to be allied rather to fibrin than to vegetable substances. Neither Professor Virchow, nor ourselves, have succeeded in forming sugar from this material.

The above conclusions are deduced from a very large number of experiments made systematically and continuously during a period of six months. A course of experiments necessarily

implies a proportion of failures, and a final acquisition of certain niceties of manipulation, a record of which is always useful to those afterwards engaging themselves in like investigations. On these grounds we append the following brief remarks:—

1. In order to obtain the characteristic action of iodine and sulphuric acid upon cellulose, it is necessary first to impregnate the tissue with iodine, and afterwards to add the acid.

2. Since the addition of sulphuric acid to the solution of iodine precipitates the latter element in a molecular form, of an indigo-blue colour, it is necessary before adding the acid to wash away all the iodine solution from around the microscopic section; otherwise the abundance of deposit may obscure the view, or its colour lead to serious error. Even when these precautions have been most complete, we have been almost misled by precipitation occurring in the iodine, which slowly exuded from the edges of a well-washed specimen into the surrounding fluid.

3. We failed in our earlier experiments to obtain a blue colour with true cellulose, through employing our sulphuric acid in a too dilute form. We soon discovered that it was essential to our success, that we should use acid of the greatest strength, and we have employed this ever since with invariable success. It is worthy of remark, that the deceptive effects obtained from the animal waxy deposits coincided with the use of the weaker acid only—that, in fact, which was inoperative on vegetable cellulose.

4. After a short time, we began to make use of Schultze's solution, and found it identical in its reäction with iodine and sulphuric acid, but more convenient in practice, since, no precipitation of iodine took place. The solution was prepared according to the instructions of Professor Busk in the *Microscopical Journal.*

5. We employed iodine dissolved either in water or spirit, or in water and iodide of potassium; we obtained equally satisfactory results with all; but found the last-mentioned most convenient, on account of the greater ease in varying its strength.

6. As the number of morbid specimens accruing during the period of our observations was necessarily small, we were compelled to preserve portions of them for further examination. We employed for this purpose spirit or glycerine, neither of these

interfered with the reactions, but while the spirit rendered the parts opaque, glycerine preserved their transparency.

The following is a list of cases which presented us with specimens of the waxy degeneration. The corpora amylacea may be obtained from almost any brain.

1. A. M., 1st of October, 1858. Chronic disease of rectum and vagina; pneumonia; waxy spleen; succulent kidneys.

2. G. R., æt. 37, 4th of October, 1858. Chronic phthisis; cicatrizing ulcers in intestines; waxy liver.

3. R. H., æt. 54, 11th of October, 1858. Pneumonia; pleuritis; pericarditis; waxy spleen.

4. C. W., æt. 58, 19th of February, 1859. Chronic phthisis; waxy spleen.

5. G. P., æt. 54, 28th March, 1859. Disease of vertebræ; tubercle; waxy and fatty liver; waxy spleen and kidneys.

6. H. W., 29th of December, 1858. Waxy kidneys, liver, and spleen.

7. Waxy spleen, from case of hepatic abscess.

Dr. J. S. Bristowe,
Mr. W. M. Ord, *5th of April*, 1859.

---

8. *Fœtus, presenting several remarkable Deformities and Malformations.*

The fœtus exhibited, which lived for a short time after birth, and was said to have been of full term, presented the following external deformities:—The left foot was affected with talipes varus.

The right foot had but three toes (the great and two smaller ones), and close to the great toe was a fissure, extending through the whole thickness of the foot, apparently as far as the astragalus. The metatarsal bones corresponded to the number of the toes, and the anterior tarsal bones were divided by the cleft.

The anus was imperforate, and only a mark in the skin indicated its position.

The penis was rudimentary and without any urethra, the scrotum being entirely absent.

The tip of the coccyx appeared to project through the skin of the back.

On opening the abdomen, the colon (immensely dilated), was found to terminate apparently in the left iliac fossa; but a small cord (pervious for a short distance), could be traced from this down into the pelvis.

The testes were retained in the abdomen, and were apparently normal.

The right kidney appeared to be a cyst; and both ureters, when traced, were dilated, and terminated in a small pouch, from which there was no apparent outlet.

The supra-renal capsules were normal in position and size.

The two hypo-gastric arteries united within a short distance of their origin to form one large vessel, which passed up to the umbilicus.

The heart appeared to have a bifid apex, formed by both ventricles projecting equally on each side of the septum.

There was no hare-lip, nor fissure in the palate.

This account is necessarily incomplete, owing to the impossibility of obtaining leave to make a further dissection.

Mr. Christopher Heath, *5th of April*, 1859.

---

9. *Malformation of the Left Lower Extremity, &c.*

R. F., a child 15 months old, was brought to me at Guy's Hospital upon the 21st of February, 1859, with the following malformations (see Woodcut 15). He was a well-nourished child, and apparently had no signs of disease.

The left thigh was longer than the right, by at least a quarter of an inch.

The left fibula was absent, the tibia being of its normal size.

The left os calcis could not be made out and was very small, if not altogether absent.

The four smaller toes, with their metatarsal bones, upon the left side, were also deficient, a soft fleshy mass, as shown by the drawing, occupying their position.

The left testis had not descended into the scrotal pouch, nor could it be felt in any position; a small empty pouch being present over the external ring.

Upon the left gluteal region there was a sub-cutaneous nævus,

and also a cicatrix indicating the seat of a small outgrowth, which had been excised after birth.

WOODCUT 16.

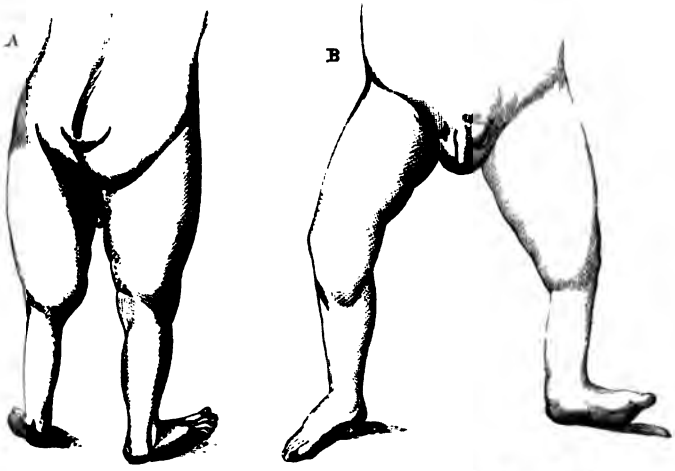

Represents—A, a back view; B, a front view, of the lower part of the trunk and limbs.

The anus was out of the median line, being situated towards the left side.

The right side of the body was quite natural.

Mr. THOMAS BRYANT, 19*th of April*, 1859.

---

10. *A Wax Model and a Dissection of the Malformed Right Hand of a Woman.*

The malformation consisted of a dwarfed condition of the second and third metacarpal bones, and of the phalanges of the first finger. The extremities of the metacarpal bones were diminished in size. The shaft of the second one was entirely wanting, the two extremities being joined on to each other. That of the third was about half its normal length and thickness. The corresponding fingers were drawn back upon the dorsum of the hand, by the action of the extensor muscles. This, in the case of

the first finger, was so extreme, that in addition to the want of development in the phalanges, it was rendered entirely useless, being almost buried in the inter-digital fold of skin on the palm.

The radial extensor tendons and the interossei muscles were normal in their attachments, the latter being correspondingly diminished in size.

Mr. JOHN WOOD, *3rd of May*, 1859.

---

11. *Dissection of a Specimen of Flat-foot (talipes valgus), in a Man of advanced years.*

In this case the inner arch in both feet was depressed; in the right foot, so much so as to be completely inverted, and to touch the ground when covered by the soft parts. This was found to depend upon an ankylosis of the astragalo-scaphoïd joint, with much depression of the head of the astragalus, shortening of the upper side of the neck, and considerable exudation of bony matter in the ridges. The scaphoïdo-cuneïform articulation was also diseased, the articulating surfaces being denuded of cartilage. There was no trace of purulent matter, nor any cicatrix on the skin indicative of abscess. The ligamentous structures surrounding the bones were much thickened, especially on the plantar surface. The inferior calcaneo-scaphoïd ligament, and the tendon of the tibialis posticus were especially hypertrophied. As a consequence of the sinking of the inner arch, the outer malleolus had also sunk down so as to work upon the outer surface of the calcaneum, which was much everted. The formation of a slightly raised articular facet on the two bones had been the effect. The other foot was similarly affected, but not to the same extent.

This condition of the foot is one often seen in Hospital practice in elderly males, associated with a stiffened and rheumatic condition of the lower limbs. It seems particularly to affect those subjects, who have had much walking and standing in the wet, or under heavy loads, such as porters and soldiers. Among the latter class of men, the battalion men, as distinguished from the lighter and more active light-infantry, have received the 'soubriquet' of "flat-feet." It is, doubtless, of a similar nature

to that condition of removal of cartilage without suppuration, which affects the hip, knee, and other joints, of a rheumatic origin.

Mr. JOHN WOOD, *3rd of May*, 1859.

---

12. *Case of a Boy, aged Five Years and a-Half, born without legs, and with each arm only about two inches in length.*

W. G., the subject of this remarkable malformation was born at Clapham on the 22nd of October, 1853, and is now, consequently, more than five years and a-half old.

WOODCUT 17.

His head and trunk are, in appearance and measurement, much the same as is usual with a child of his age; but the boy is almost entirely destitute of upper extremities, and absolutely so of the lower ones.—(see Woodcut 17.) His entire height is twenty-two inches and a-half. There is no curvature or deformity of the spine, but the lumbar vertebræ are perhaps a little less incurved—somewhat more rounded and prominent—than usual; the chest is of fair size and form, and measures nineteen inches in circumference at

the nipples. The pectoral muscles are rather small, though quite distinct.

His right arm is two inches in length, the left one two inches and a-quarter. Each one contains the head and a small portion of the adjoining part of the humerus. The lower end of each humerus is rounded off; and between it and the skin covering it there is some cellular or fatty tissue. The skin at the end of the arms is smooth, and presents no mark or indentation, or any indication of a rudimentary hand.

There are no lower extremities; but in the position of the head of each femur there is a small projecting mass which, on the right side, is only half-an-inch in length and one inch in diameter, and on the left, one inch long and one inch and three-quarters in diameter. Each of these projections is attached to the trunk by a peduncle of about half its own diameter; but the peduncle is so short as, on first examination, to be scarcely perceptible. These small masses are quite soft, and appear to consist only of skin, cellular tissue and fat. There is no trace of either femur. In the position of the acetabulum a slight ridge may be just felt, which probably corresponds with the margin of the cavity which ought to exist.

The glutei muscles are somewhat (but not remarkably) less than usual, and the lower part of the pelvis appears rather flat. The scrotum is short and contracted, but contains both testicles.

The boy is of light complexion, and has but little colour on the cheeks; hair light; irides of iron-grey colour. His teeth are much decayed. The palate is more arched than usual.

Expression of countenance animated and rather intelligent. Can read and repeat verses. He is attentive to, and interested in, what passes around him. He does not articulate all his words well, as he has some degree of impediment in his speech, and his mother says he spoke more plainly a year ago than he does now. He has had very good health. Hooping-cough he got well over, and he has not had the other diseases of childhood.

He exhibits a considerable amount of activity; and there appears to be more than usual mobility and power of flexion of the lumbar region. When laid down, he is not able, without assistance, to raise himself into the erect posture; but when placed in that position, that is, resting on the lower part of the pelvis, he is able

to maintain himself in it for some time without assistance, a feat he has only been able to do within the last month or so. He is able to move the portions of arms he possesses to a considerable degree. He can thus hold a small object (such as a shilling) in either axilla; and he is able to raise the left shoulder sufficiently high to rub the ear with it. When he wishes to move from place to place, he rolls over sideways. This motion he effects, when he is placed on his back, by bending upwards the pelvis and twisting the thorax to one side. He then appears to straighten the lumbar vertebræ, and at the same time assists himself in turning over by means of his chin (which he presses on the carpet), and by one shoulder. All this he effects very rapidly, so that he quickly rolls from one end to the other of a room. He usually picks up an object with his teeth.

There is no auscultatory sign of malformation of the heart.

The boy's father was a labourer, who was married at the age of thirty-four, and died, aged forty-one, of "rapid consumption." He was not considered a strong man. The mother, a charwoman, always enjoyed good health, and is now rather ruddy, and certainly healthy-looking. She was married when thirty-two years old; had two miscarriages, of which the second occurred (at the third month) two years before the birth of this child, which took place when the mother was thirty-six years of age. No member of either the father's or mother's family had presented any deformity, and the mother's family, at least, was a healthy one. During her pregnancy, the mother received no blow, fall, or injury, nor had she any fright. She had no "impression" that her child would be deformed, nor did she know that it was so until some hours after its birth. It was born at the usual period of gestation, and, as regards the head and trunk, was of the average size.

For first seeing the child, I am indebted to Mr. Darnton Greenwood, of Clapham, who has not only taken great interest in the case, in a medical point of view, but has also done very much, in other ways, for the welfare of the boy. The accompanying woodcut is a copy from a very good photograph, taken for Mr. Greenwood, and which he kindly gave me.

The boy himself was exhibited to the Society.

Dr. Hare, 17*th of May*, 1859.

DESCRIPTION OF PLATE X.

Figure 1 represents the Microscopic appearances in the Case of Aphthous Exudation described by Dr. Peacock, p. 311.

Figure 2 represents the Microscopic appearances in the Case of Diphtheritic Exudation described by Dr. Peacock, p. 312.

Figures 3 to 8 illustrate Dr. Bristowe's Remarks on the Microscopic character of Diphtheritic Deposit, p. 322.

Fig. 3. Under surface of false membrane from the fauces.

Fig. 4. The same, acted on by acetic acid.

Fig. 5. Flocculent false membrane from the posterior nares.

Fig. 6. Fibrous exudation into the sub-mucous tissue over the epiglottis.

Fig. 7. Fibrinous casts of renal tubules.

Fig. 8. Fatty deposit in renal epithelium.

Fig. 1

× 300

Fig. 2

T. West del.

Fig. 3.

Fig. 4.

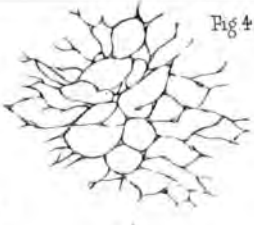

Fig. 5

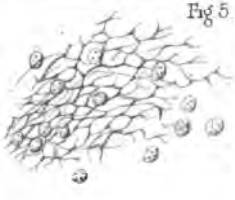

Fig. 6.

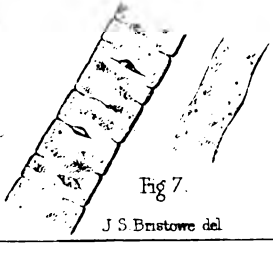

Fig. 7.

J. S. Bristowe del.

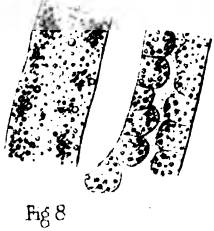

Fig. 8

Duffen. West. sc.

W. West. imp.

13. *Case of Epithelial, or Warty Growth upon the Chordæ Vocales.**

This occurred in a male child, æt. 4, and caused sudden death from asphyxia. The preparation was sent for exhibition by Dr. Wilkinson, of Holloway. Fourteen months ago the child had a slight cough and hoarseness, the latter symptom increasing accompanied by a croupy sound in breathing up to the time of death; after six months he had a fit of severe dyspnœa, producing lividity of the face and extremities, after which with intervals of comparative health (the respiration continuing wheezing and the voice lost) he had two other fits of suffocating cough, which at last carried him off suddenly in the night.

The specimen showed a warty growth on each side of the chink of the glottis. They sprung from the upper surface of the vocal cords, and completely filled up the ventricles and sacculi of the larynx. The masses could be separated into many bundles of warty stems branching into lateral processes, and closely packed together into the ventricles. Under the microscope, they were found to consist entirely of epithelial cells of the ordinary shape of those of the mucous membrane covering the glottis, but somewhat larger. The cells were not packed concentrically as in epithelial cancer, but seemed to be simply laid upon each other as in common warty growths. The sudden fits of dyspnœa which at last terminated fatally, were probably due to congestion of the neighbouring mucous membrane of the rima glottidis, which would, in the absence of the growths, have produced only a temporary cough. Mr. JOHN WOOD, *15th March*, 1859.

II. DIPHTHERIA.

14. *Microscopic Drawings of the Deposit in a case of Aphthous Exudation and in one of Diphtheria.*

The drawings were executed by Mr. Tuffen West.

1. The first drawing (Plate X., Fig. 1), represented the appear-

* This case is described amongst the miscellaneous specimens, as its introduction amongst the diseases of the respiratory organs was inadvertently omitted.

ances in a specimen of aphthous exudation, removed from a young man, æt. 19, in the last step of phthisis. He was taken during the hot weather of the last summer with a sharp febrile attack, attended by sickness, vomiting and diarrhœa, and complained of a sense of burning heat in the course of the œsophagus and stomach. The mouth, tongue, and fauces became rapidly covered by specks of white-coloured deposit, which rapidly coalesced, forming a continuous coating, fully an eighth of an inch in thickness. When this was removed the sub-jacent mucous membrane was found red, glazed, and excoriated; and the deposit quickly reäppeared on the denuded surface. When examined under the microscope, the deposit was found to consist of "buccal epithelium, with the mycelium of a fungus interlacing in every direction, with sporidia forming in parts, and multitudes of free sporules."

2. The other drawing (Plate X. Fig. 2), represented the appearance of the exudation in a case of diphtheria. It displayed "blood corpuscles, held together by a rust-tinged matrix, with slight traces of fibrillation in places; small granular cells about the size of blood-cells, some showing a nucleus rendered larger and clearer by the addition of acetic acid (pus); together with epithelium from the fauces in different stages: no vegetable growth could be detected in any portion of the deposit." The drawing was taken from a portion of exudation removed, the day before death, from the fauces of a boy, æt. 6, a patient of Mr. J. M. Burton, of Blackheath. He was ill about twelve days, did not at any time present active febrile symptoms, nor, till shortly before death, marked laryngeal obstruction; he sank chiefly from exhaustion. Two younger children of the same family, though removed from their home to a distance (in one case quite at the commencement of the illness), and a lady who had visited there but resided in town, also died of diphtheria, after the little boy. The children had not previously had scarlet fever, but there was no reason to suspect that the cases had any connection with that disease. The neighbourhood in which the cases occurred is usually very healthy and is elevated, dry and well drained, and the house is large and airy.

Dr. Peacock remarked that, in the first class of cases, he believed the deposit to consist essentially in a vegetable growth;

but, in the latter, he regarded it as an ordinary fibrinous exudation, and thought that the vegetable growth, when found, was only accidental. He had examined the deposit in another case of diphtheria, and found only the usual characters of fibrine, without any traces of vegetable growth.

Dr. Peacock, 19*th of October*, 1858.

---

15. *False Membrane, covering the Tonsils and the Epiglottis, and lining the Larynx and the Trachea, in a Case of Diphtheria.*

The patient was a girl, æt. 15, residing at Bagshot, in Surrey. She was a well-formed person, with good muscular development, and moderately fat. Her residence appeared to be healthy, and was isolated from other houses. She appeared to be well nourished. Two children in the same family had previously died of diphtheria. The symptoms in this girl's case were very insidious: the first indication of the disease being merely an inconvenience in the throat, resembling a slight cold. When Dr. Blount, of Bagshot, first saw the girl, he found the tonsils covered with a pellicular exudation, and very much swollen, particularly the right tonsil. On the morning of the 17th of October, she was in an unsatisfactory state, but was quite sensible, and indeed was able to get out of bed. In the afternoon of the same day, she was informed of the funeral of the child who had last died; and while the ceremony was taking place, she rapidly sank and died, apparently from syncope. There had been scarcely any cough or difficulty of breathing, and no symptoms of asphyxia. On *post-mortem examination*, both tonsils were found enlarged, but particularly that of the right side; they were both covered with a dirty greyish-brown spongy-looking substance, which, however, could be removed from the sub-jacent structure. The epiglottis was completely covered by the false membrane, which likewise lined the larynx and the trachea. This false membrane in all points could be elevated by the handle of the scalpel, leaving the mucous surfaces beneath in a congested state, but quite entire.

The false membrane was, however, so firmly attached to the mucous surfaces, that it could be detached only in small strips, and not in a consistent and continuous mass.

Dr. Semple, 19*th of October*, 1858.

16. *Part of the Tongue, the Tonsils, Pharynx, Œsophagus, Epiglottis, Larynx, and Trachea of a Child who died of Diphtheria.*

D. M., æt. 7, residing at Bagshot in Surrey, was taken ill on the 17th of October, and died on the 30th. This was the tenth fatal case which had occurred in the same locality within about a month. The general and constitutional symptoms were but few; there was languor and debility; a quick pulse, 120, and never varying: there was a great disinclination to move or to make any effort; there was also a feeling of coldness; there was no cough and not much uneasiness; the bowels were regular, and the urine was natural; the nights were passed without requiring attendance until within three days of death. There was great disinclination for food and drink. The exudation was seen at first only on the left tonsil and the posterior part of the pharynx of the same side, and did not seem to spread; the parts around appeared from the first to be of a dull-red colour. On the 25th of October he complained of his throat externally being very tender, and the point indicated was the larynx; but the voice was changed only in being weaker and somewhat more shrill. On the 27th of October, spots of purpura appeared on the body, and on the 30th, death took place quietly and apparently from exhaustion; he asked for some water to drink a few minutes before death.

Post-mortem examination.—The parts external to the larynx and trachea exhibited a uniform black mass, as if from extravasated blood. The surface of the body was covered with purpura, and there were effusions of blood resembling purpura on the heart, pericardium, and endocardium.

The tonsils were intensely congested and swollen, presenting almost a black colour, and their external surface exhibited some scattered white aphthous patches. The pharynx and larynx were intensely reddened, and in the latter, close to the rima glottidis, some false membrane was found, but of very limited extent. The trachea contained a considerable quantity of dark-red mucous matter, but no distinct false membrane. The mucous membrane was very much injected. The œsophagus was of a healthy appearance. Dr. Semple, *2nd of November*, 1858.

---

17. *Fauces, Larynx, and Trachea of an animal that had been inoculated with Diphtheritic exudation.—Query: Can Diphtheria be communicated by Inoculation?*

While showing the above-mentioned specimens to the Society, Dr. Harley said that he had inoculated five animals with the exudation taken from the fauces of a young woman aged twenty-three (one of Dr. Walshe's patients, in University College Hospital), supposed to be labouring under diphtheria. The patient had a severe attack of scarlet fever ten years previously. On the present occasion, she was not aware of having been in any infected neighbourhood. Had lately very much hard work, and very little nourishment. Married, and mother of three children.

The experiments were performed as follows:—

1. As children are especially liable to diseases accompanied with membraniform deposit—such as croup, for example—two young pups were selected.

2. As badly-nourished, sickly people have been supposed to be favourable subjects for diphtheria, a sickly, ill-fed, full-grown dog was procured.

3. A perfectly healthy adult dog was also experimented upon.

4. As the foregoing were all warm-blooded animals, and the experiment was wished to be made as complete as circumstances would admit of, a common snake, which is a cold-blooded animal, was also employed.

Some of the membrane carefully removed from the fauces of the woman, together with some of the yellowish-coloured mucus secreted from the denuded surface of the pharynx, which was found on microscopical examination to contain all the cell elements of the perfectly-formed membranous deposit, was collected in watch-glasses, and covered up from the action of the atmosphere. The fauces, and pharynx of each of the four dogs were now scarified; and while two of them had the abraded surfaces well rubbed over with the diphtheritic membrane, the other two were inoculated in a similar manner with the yellowish mucus. The snake, on the other hand, was inoculated on the back of the neck, close to the head. Twenty-four hours after the performance of the operations, the two pups

were killed and examined, but nothing was detected save the marks of the scarifications. Four days afterwards, the sickly dog died. On examination, no change was found to have taken place about the throat, except that a small ulcer had formed on the centre and most posterior part of the soft palate. This ulcer was not covered with anything resembling a diphtheritic exudation; but, on the contrary, presented the usual appearances of a common ulcer of the mouth, and had most probably resulted from the scarification and the force employed in rubbing in the matter The other dog, as well as the snake, are both quite well (seven days after the operation).*

Dr. Harley, *7th of December*, 1858.

---

18. *Specimens illustrating the Morbid Anatomy of Diphtheria.*

A. H., æt. 13, had been suffering from diphtheria for nineteen days before his death, and during the last eleven had been under treatment in St. Thomas's Hospital. On the eighth day of the disease, a large mass of thick, dense, very fibrinous false membrane detached itself from the fauces; leaving the surface of the tonsils and soft palate raw (like that of skin from which the cuticle has been removed after blistering), but not ulcerated or sloughing. On part of this surface a second thinner false membrane soon formed, and subsequently came away in shreds. There was irritating discharge from the nose, and during the last days of life some of the patient's drink escaped this way. Early in the disease there had been swelling below the jaw; but this had subsided many days before death. On the seventeenth day of the disease, superficial ulceration began at the left tonsil, and on the eighteenth day had extended to the size of a shilling. On each of the last eleven days of life, the urine was examined:—it always gave abundant precipitate with nitric acid, and latterly, also with heat; but in the earlier days it precipitated imperfectly

* This communication (which otherwise would have been introduced amongst the specimens from the lower animals at the close of the Volume), has been inserted here, as bearing upon the interesting question of the effects of a disease which, at the present time attracts so much attention.—Ed.

with heat, and largely with acetic acid. Microscopically, it showed fibrinous tubule-casts, containing traces of hæmorrhage, but scarcely any renal epithelium. Throughout the progress of the disease, the patient was pale, feeble, and disposed to be chilly; so that wine and much external warmth had from the first been necessary. The tongue was always moist. No eruption appeared upon the skin. There was no delirium or stupor, and neither cough, nor any sign of laryngeal obstruction was observed. The respiration was natural till within a few hours of death, when it became short and hurried.

The following were the *post-mortem* appearances.

With exception of an occasional very delicate film, there was no false membrane about the fauces. In the situation of the left tonsil was a sloughy ulcer, somewhat larger than a shilling. The posterior surface of the soft palate was congested, and there adhered to its somewhat swollen mucous membrane small patches of false membrane. In the recess of mucous membrane beside the epiglottis, was an irregular depression—evidently the remains of an almost cicatrized ulcer. About an inch below the aperture of the glottis, the pharynx presented on its right side a small circular ulcer, about two lines in diameter, with somewhat raised margins, and on the left side another similar ulcer about the size of a pin's-head. In other respects the pharynx and œsophagus were healthy. On washing out the nares, a strip of false membrane an inch in length was removed. The mucous membrane covering the septum showed patches of congestion, was thickened, and had shreds of false membrane adherent to it.

Both lungs, except in their upper and anterior parts, were greatly congested with blood and less crepitant than is natural, especially the lower lobes, whose posterior parts were in many places nearly or quite without air, the most solidified portions broke down on firm pressure with the finger. At one section the exuding fluid was obviously purulent; and microscopical examination showed pus extensively in other parts of the hepatized structure. The bronchial mucous membrane was a little injected. The tubes contained thin frothy fluid tinged with blood, or more tenacious reddened mucus.

The kidneys were large and intensely congested. Sections of

the cortex, microscopically examined, showed frequently the presence of large transparent colourless rods of apparently fibrinous material, soluble in acetic acid and liquor potassæ. These rods were sometimes floating free, sometimes partly or wholly held within urinary tubules, of which evidently they were casts. They were generally structureless; but (no doubt from the manner of their formation) they had a disposition to transverse fracture, and sometimes presented lines curving almost concentrically across them, or had this direction given to little clusters of granular matter (probably altered epithelium) which they occasionally contained. Apart from the presence of these casts, the tubular structure of the kidney was not very obviously diseased; but, after prolonged and careful examination, it could confidently be said that, at least in many parts the cell-growth within it was redundant, so that the tubules were more opaque than natural, and had their interior canal encroached upon, or even quite occluded by an increased amount of epithelium. The Malpighian tufts, within their capsules, showed a little indistinctly.

The venous system was everywhere remarkably full of blood. The liver was greatly congested. The heart was healthy, with a firm coagulum in each of its four cavities.

The above specimens were shown to illustrate two points:—1. the occurrence of ulceration, as a secondary process, in the textures which had primarily been covered with false membrane; and 2. the occurrence of internal complications in diphtheria. In reference to the first point, Mr. Simon observed, that, although certainly it is essential to diphtheric inflammation to be primarily not an ulcerative or gangrenous process, yet other post-mortem examinations of diphtheric throats had shown him that their state, especially the state of the tonsil (with fibrinous and bloody infiltration of its substance) is one which might easily pass into ulceration or sloughing. In reference to the second point, he observed that, in respect of the morbid appearances discovered in the kidney, as well as of the condition of the urine during life, this case tallied with others which he had examined, and led him to believe that the tendency to renal complication is an essential part of diphtheria. He had not previously had any opportunity of examining the lungs of diphtheric patients, and could not say

whether pneumonia frequently existed as a complication of the disease. Mr. SIMON, *15th of February*, 1859.

Report on the kidney from the above-described case of Diphtheria.—The kidney had a swollen appearance, and its surface was lobed, and mottled by an irregular blending of anæmia and congestion. The gorged Malpighian bodies were everywhere visible by the naked eye. On a section the medullary cones contrasted by their deep-purple colour with the comparative pallor of the cortex. The cut surface emitted, on pressure, a fluid which was rendered turbid by the broken-up tissues.

WOODCUT 18.

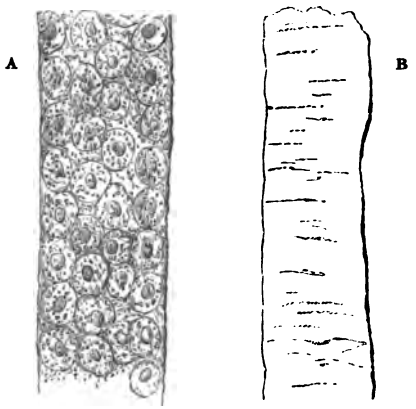

Represents—A, one of the renal tubules containing granular matter; B, a cast from another tube.

The microscope showed the epithelial cells swollen, opaque, and containing an unusual amount of finely granular material. There was little evidence of epithelial desquamation, or of intra-tubular hæmorrhage. Here and there a tube, devoid of epithelium, had its cavity filled with transparent fibrin, forming a wax-like cast whose diameter was equal to the whole calibre of the tube.

The capillaries were everywhere much gorged with blood. Many of the Malpighian capillaries had the somewhat opaque

and finely granular appearance which is commonly observed when an albumino-fibrinous exudation has passed through their walls.

It will be seen then, that the condition of this kidney, as observed both by the naked eye and by the aid of the microscope, is identical with that which is found in a large proportion of the instances of acute inflammatory renal disease which occur in connexion with scarlatina; and we know of no means by which an inflamed kidney from a patient who has died of diphtheria, can be distinguished from the analogous affection which occurs so commonly in cases of scarlatina, and less frequently in connexion with various other zymotic diseases.

In this particular instance there appears to have been little, if any, epithelial desquamation, but in a case of diphtheria which recently came under our observation (G. J.), there was an abundant desquamation as shown by the epithelial casts in the urine, and the stuffed condition of the tubes in the kidney. Desquamation is not an essential phenomenon. It may be absent, or it may be present both in cases of scarlatinal renal disease, and in cases of diphtheritic renal disease.

George Johnson, M.D.
S. Wilks, M.D., *2nd of March*, 1859.

---

19. *Membranous Cast of Trachea and Bronchi expectorated by a patient labouring under Diphtheria.*

The preparation was sent to me by Dr. David Thompson of Launceston, under whose care the subject of the case had been. The preparation consists of a membranous cast of the larynx, trachea, and larger bronchi, extending to the third subdivision. Near its upper extremity the cast is perfectly complete and tubular; above and below this it is incomplete. The substance of the cast is firm and tenacious, and presents an appearance and consistence very similar to those of wash-leather.

The patient was a girl, æt. 12, and was first seen by Dr. Thompson on the 11th of August, 1856. At that time the fauces were red and congested, the tonsils enlarged, and of a deep-red colour, and on the left one there was a large patch of white deposit.

On the 12th, this deposit had extended over the right tonsil. On the 14th, there was huskiness of voice, but little or no dyspnœa. On the 16th, there was complete loss of voice, with croupy cough, but still not much dyspnœa. On the evening of the 16th, the patient expectorated the cast above described, and for a few hours after she appeared much relieved; but within twelve hours she died suffocated. The friends would not permit a post-mortem examination, so that it was impossible to say whether the suffocation was the result of a re-formation of the membrane, of its extension into the smaller bronchi, or of a portion of it having become impacted in the rima glottidis.

Dr. Thompson is unable to say, whether the patient ever had scarlet fever. Diphtheria was at the time of her illness prevailing very extensively in the neighbourhood, and the sister of the patient, as well as two cousins residing at a distance of two miles, died of the disease. Scarlet fever was not prevalent at the time.

Dr. Thompson adds, that diphtheria appears to have become endemic in Launceston during the last four years, and that at present he sees on an average three or four cases a-week.

Dr. Murchison, *15th of March*, 1859.

---

20. *On the Morbid Anatomy of Diphtheria.*

Having enjoyed several opportunities of investigating the morbid anatomy of diphtheria, I have thought that it might not prove altogether unacceptable if, ere the interest created by the disease has passed away, I ventured to lay before the Society the results of my experience, even though they should be confirmatory merely of previously recorded observations. My experience consists in the close study of the three cases appended to this communication, in a careful independent examination of the case published in the present volume by Mr. Simon, in the inspection of several specimens of the larynx, many specimens of detached false-membrane and a few of kidney submitted to me from time to time for examination, and in the clinical teachings of several non-fatal cases of the affection which have been more or less continuously under my observation.

1. *Condition of fauces and adjoining parts.*—The affection of the throat consists in a peculiar kind of inflammation of the

mucous tissue accompanied by the formation of a false membrane. This inflammation (in the early stage superficial and originating usually in the neighbourhood of the tonsils and on the back of the pharynx), may extend either in depth or surface. In the former case it may involve not merely the sub-mucous tissue and the substance of the tonsils—parts usually affected; but may invade the sub-jacent muscles and the neighbouring glands, and include even all the tissues of the front of the neck. In the latter case it may spread over, not only the pillars of the fauces, the soft palate, the base of the tongue, and the greater part of the pharynx, but frequently the posterior nares and the larynx; and may even pass into the trachea and along the bronchial tubes, or travel along the œsophagus as far as the cardiac orifice.

The false membrane presents a greyish or dirty yellowish-white tinge; is generally about half-a-line in thickness, but often thinner, and sometimes very much thicker; its outer surface is usually somewhat uneven and fissured, occasionally, even flocculent; its deep aspect, except at the time of separation, is pretty firmly adherent to the sub-jacent mucous membrane, is moulded upon it, and may at times be distinctly seen to send prolongations into the mucous follicles. In consistence it approximates somewhat to that of false membrane connected with serous membranes, but is somewhat less elastic, and at the same time more friable and solid. It varies, however, considerably in these respects; and the outer region is generally more flaky, and less coherent than the deeper.

On microscopic examination, it appears to consist chiefly of epithelium and coagulated lymph (Plate X., Fig. 6). The epithelium, which is that belonging to the affected sub-jacent membrane, seems generally pretty healthy, but sometimes more or less granular and breaking down. Nuclear bodies, in greater or less abundance, are also frequently present; these being probably either the transformed products of the mucous crypts, or the abortive epithelial formations of the mucous membrane itself. The coagulated lymph essentially resembles that poured out on serous membranes, and consists of a close network, the trabeculæ of which are refractive, and various in size and shape, but comparatively thick, and the inter-

stices of which are minute, and irregularly polygonal in form. The meshes are so small, and the intervening fibrillæ so irregular and thick, that when seen in mass they present a pebbly appearance, suggestive of the appearance of innumerable nuclei; this appearance, however, is almost always fallacious, as may be seen by examining the edge of a microscopic section; or by the addition of acetic acid, which expands and renders the whole transparent (Fig. 4), brings no nuclei into view, but instead, an irregular, comparatively large network, which appears to consist of the attenuated axes of the now dilated and partially dissolved trabeculæ. The only distinction between the fibrinous network here spoken of, and that formed upon serous membranes is the accidental one of size; and that this is apparent rather than real is shown by the fact, that though in serous membranes the network is usually far larger and coarser, in both cases it is occasionally found much more delicate than the above description would imply.

I have always observed that the free surface of the false membrane is made up chiefly of epithelium, the deep almost exclusively of fibrine; from which fact it may be assumed that the morbid process taking place at the mucous surface consists essentially in the effusion of coagulable lymph; that the first effused portion entangles the epithelial cells, and that the subsequent ones accumulate between the true epithelial layer and the basement membrane, becoming successively more and more free from entangled cells, and more and more purely fibrine. It may be added, that the free surface becomes generally mixed with extraneous matter, such as starch, milk, and muscular fibre; and may form a nidus for the development of lowly organized cryptogamic plants.

The mucous membrane itself, sub-jacent to and around the false membrane, is always more or less congested; and the sub-mucous tissue, especially in those situations in which it is naturally lax, as about the epiglottis and upper half of the larynx, becomes not only œdematous, but the seat of interstitially-deposited lymph; which, undergoing coagulation, presents an arrangement similar to, but coarser than that of, the false membrane occupying the free surface. When the false membrane has separated, the mucous surface is generally left whole, though delicate and tender;

often, however, it is distinctly excoriated, and sometimes exhibits decided ulceration. The tonsils are usually more or less enlarged, become soft and deeply congested, present occasionally suppurating points, or cavities, in their interior, and sometimes become distinctly gangrenous. The inflammation does not appear to extend commonly much beyond the structures here enumerated; yet it may invade other tissues of the neck, and even, as in the case of T. N., involve the whole of the cervical region anterior to the spine. That the muscular tissue may become impaired is shown by the frequent supervention of a more or less well-marked paralytic condition of the soft palate; yet I have been unable to detect in the muscles thus affected any deterioration in their ultimate structure.

The form of throat-affection above described, though doubtless forming an essential part of a peculiar and specific form of disease, does not itself, in its morbid anatomy, present any specific nature. The changes which take place in the mucous membrane and sub-jacent tissues are of the same kind as those observed in other forms of throat-inflammation; and the false membrane deposited differs in no important respect from that of common croup, or from that which is occasionally seen in cases of scarlet fever, erysipelas, or even smallpox.

2. *Condition of lungs.*—The bronchial tubes are probably not generally affected; though, when the larynx and trachea have become involved, they almost necessarily get loaded with secretion, and may even, in rare cases, present an extension of false membrane. The condition of the lung-substance itself, however, is commonly, I suspect, a point of greater importance; at least if I may venture to draw conclusions from the cases which have come under my observation.

In two of the four complete autopsies which have furnished material for this paper (in Mr. Simon's case and in that of M. A. F.), the lungs were found to be the seat of extensive lobular pneumonia. These organs were much more solid than natural, and studded thickly and uniformly, from apex to base, with small hepatized masses, separated from one another by a network of crepitant and comparatively healthy tissue. The solid masses in some parts resembled carnified tissue; in others, apoplectic effu-

sions; in others, presented all the varieties of true hepatization; and in all cases displayed, both microscopically and otherwise, ample indications of their inflammatory origin. Traces of the same kind of affection were present in the case of T. N. The lungs of J. P. were the only ones that appeared absolutely healthy. Now, the form of lung-affection above described (which I have frequently recognized as a sequel of laryngeal affections and of infantile bronchitis, and which is, therefore, manifestly not peculiar to diphtheria), is one that creeps on insidiously, is attended by none of the usual symptoms of pneumonia, and, from its anatomical distribution, by none, or scarcely any, of the ordinary auscultatory phenomena; yet it tends gradually to destroy a large portion of lung-tissue, and cannot fail, therefore, to operate seriously in promoting a fatal issue; and does, I strongly suspect, play an important part in producing those deaths which occur with such lamentable frequency during apparent convalescence.

Condition of heart.—I have no reason to suppose that the heart is usually otherwise than quite healthy. In the case of T. N., however, it was not only the seat of intra-muscular hæmorrhage, but in a state of well-marked, though early fatty degeneration. These conditions I imagine to have been due to the accidental intensity of the disease, and to be explicable on the same principles as the like conditions occurring in purpura, pyæmia, scarlet fever, and other cases in which the quality of the blood becomes rapidly impaired.

3. *Condition of kidneys.*—I believe that all the kidneys which I have had the opportunity of examining, have presented to the naked eye a healthy or nearly healthy appearance; yet all of them that I have submitted to microscopic examination, have presented marks, more or less distinct, of disease (Figs. 7, 8). In some I have recognized merely slight traces of hæmorrhage into the tubes, with an occasional transparent fibrinous cast. In some I have observed, besides the above appearances, a certain degree of opacity and granularity of the epithelial contents of the convoluted tubules. And in the most advanced examples, I have discovered granular exudation between the Malpighian capsules and tufts, a distinctly fatty and distended condition of the epithelial cells, the presence of fibrinous casts and hæmorrhagic exudation, and

these not confined to the cortex, but occupying in an equal degree the medullary portion. All the appearances here enumerated indicate the presence of slight inflammation, but of inflammation not necessarily therefore unimportant, or unlikely to be followed by serious consequences.

4. The above description includes the more important pathological conditions which I have observed in cases of diphtheria. I may add, however: 1. (in reference to the blood), that there were fibrinous coagula even in the heart of T. N.; and that hæmorrhagic exudation was not confined to the tissues of the heart and neck, but had occurred in many parts of the sub-peritoneal tissue, and in the substance of the supra-renal capsules. 2. (in reference to the skin) that I have on several occasions witnessed a measly (probably petechial) eruption, appearing generally shortly before death, and due probably to the same cause as the internal hæmorrhages, to which reference has just been made.

---

21. *Diphtheria. Fatty Degeneration of the Heart. Renal Affection. Internal Hæmorrhage, &c.*

T. N., æt. 10, the son of a farm-labourer, was admitted into St. Thomas's Hospital, under Mr. Solly's care, on the 12th of November, 1858, with contraction of the left wrist- and elbow-joints, after a burn. On the 18th he was operated upon, and continued under mechanical treatment up to the commencement of the malady of which he died. He appeared perfectly well on the 20th of March, 1859, but on that day partook secretly of some gin and other improper articles of diet. The following morning he had a slight attack of shivering, and seemed otherwise a little indisposed. On the 22nd he complained of slight soreness of the throat. This increased, and on the 24th the following notes were taken by the surgical registrar:—"Throat much swollen externally, particularly on the right side. On looking into the throat, the right tonsil is seen filling up the fauces, and has upon it a pultaceous material. Pulse small and weak, 130; tongue furred; skin cool."

On the 25th he was placed under my care. He has slept a little in the night, and is said to be a little better than he has

been. He is extremely feeble, however, not at all feverish, and perfectly rational. The skin is cool, and gives no indication of rash. Pulse small, weak, slightly irregular, and about 100. There is great tumefaction, hardness, and tenderness in the upper part of the throat, chiefly in the parotid and submaxillary regions, and more on the right side than on the left. The anterior half of the tongue is clean, and its papillæ are healthy; the posterior half is somewhat furred. The right tonsil is much swollen, and covered by a thick wash-leather-like false membrane, which is prolonged from it into the pillars of the fauces, over the right half of the soft palate, and to the edges of the posterior teeth. The nose bled this morning, and a little thin sanious fluid has continued to ooze from it. Has no pain anywhere except in throat; experiences pain and difficulty in swallowing, but can manage to take fluids. No cough or difficulty of breathing. Bowels opened yesterday.

March 26th, two P.M. Slept pretty well, but is much worse than he was. Skin cold, without trace of rash. Pulse quite imperceptible. Throat more swollen, hard, painful on pressure, and studded on the right side with small congested points. Tongue dryish, but not much furred. The breath has a faint gangrenous odour. There is no appreciable change in the condition of the interior of the throat. Is quite sensible but very restless. No pain except in the throat. No cough or embarrassment in breathing.

He continued to sink, and died at half-past five P.M., remaining sensible to the last.

He was treated chiefly with wine, brandy, eggs, and beef-tea, poultices to the exterior of the throat, and gargles containing chlorate of potash and a little hydrochloric acid.

The urine, from accidental circumstances, was not examined. No appearances indicative of scarlet fever were ever recognized; but during the progress of his fatal illness a few sores on the arm assumed a superficially gangrenous condition. There had been no diphtheria in the ward previously; but a second boy, who ultimately recovered, was attacked with the same disease within a day or two of his death. There had been a case of erysipelas about six weeks before, and, about the same time, a mild case of

scarlet fever. It is believed, but it is not quite certain, that the subject of the present report had never had scarlet fever.

Post-mortem examination.—In fair condition. Left hand and arm much contracted, in consequence of the cicatrization of an old burn; and a little above the wrist were two or three shallow ulcerated surfaces, covered by thin, black, depressed eschars. The front and sides of the throat were thick and brawny; and the parotid and submaxillary regions were much swollen and hardened; especially on the right side, where also the integuments were studded with congested and livid spots.

On cutting into the neck, its muscular and cellular tissues, from the integuments to the vertebræ, and from the ears and root of the tongue to the upper opening of the thorax, were found indurated and brawny, and so infiltrated with blood as to be everywhere almost black. There were no circumscribed fluid or clotted collections, but the blood was uniformly diffused throughout the tissues. There was no appearance of pus, and no visible indications of inflammatory deposit.

The soft palate and uvula, the tonsils and pillars of the fauces, the œsophagus and larynx were all intensely and deeply congested, tumid, brawny, and covered in many places by toughish adherent ashy false membrane, or by pultaceous puriform exudation.

The soft palate was quite half-an-inch thick, infiltrated with blood, and studded with shreds of false membrane. The tonsils were swelled, but at the same time presented deep fissures and excavations, and were covered pretty completely by greyish-yellow false membrane. This was in parts thick, tough, and pretty firmly adherent, but over the convexity of the tonsils became changed into a soft pultaceous deposit, which seemed partly pus, and partly superficial slough. On incising the left tonsil it was found softened, deeply congested, partly infiltrated with blood, and studded with distinct pus-holding cavities; and the surfaces of the fissures passing into it from the surface were soft, greenish, and slightly gangrenous. The right tonsil was generally in the same condition as the left, but presented several deep, distinctly gangrenous, fœtid excavations. The mucous surface of the base of the tongue, and back of the pharynx were

congested, and presented here and there shreds of adherent membrane. The mucous investment of the epiglottis, and indeed that of the whole larynx were thickened, indurated, and deeply congested. The epiglottis was covered pretty extensively by a toughish adherent membrane about half-a-line thick; and a similar formation in less abundance was studded over the rest of the laryngeal surface, and was accumulated along the vocal cords. The trachea was congested, but otherwise healthy; the œsophagus also was healthy: but the tissues immediately surrounding them, like those of the rest of the neck, were infiltrated with blood. Several portions of the hard palate, and of the septum nasi, were removed, and their mucous covering was found congested and lined by adherent false membrane.

Pericardium healthy. Heart small, firmly contracted, and nearly empty; its auricle and right ventricle containing a little fibrinous clot only. The valves were healthy. The muscular tissue was generally pale; but almost all the musculi papillares and carneæ columnæ of the left ventricle, and the walls of the apical half in nearly their whole area, and to a depth varying irregularly from a-quarter of an inch downwards, were almost black from a nearly uniform infiltration by blood. The same condition was observed in the right ventricle but to a less extent. The papillary muscles and the parietes were studded irregularly and thickly with black blood-infiltrated patches of various sizes; some of which were so thick as to reach the external surface of the organ, and some of which presented white spots and patches on their surface, looking at first sight like suppurating points.

Pleuræ healthy; lungs crepitant throughout and not materially congested. They presented, however, on their external surface, a few dark-red, almost black spots, about a quarter of an inch in diameter, which were found to correspond to small sub-jacent patches of solid, dark-coloured, granular lung-tissue. The bronchial tubes contained much secretion.

Peritoneum healthy. Liver of usual size, generally of normal colour and consistence; its surface and substance, however, were thinly studded with petechial spots. Spleen of usual size, pale, and of moderate consistence. There was a little effusion of blood in the sub-mucous and cellular tissue around the pancreas

and supra-renal capsules; and the latter organs presented patches of extravasated blood in the interior, though apparently in other respects healthy. The cellular tissue of the mesentery was studded pretty thickly with small and not very intensely coloured patches of congestion and extravasation. The stomach and intestines were healthy; but the ileum contained two lumbrici. The kidneys were of the usual size, pale, and apparently perfectly healthy. Aorta and vena cava healthy.

Microscopic examination.—The false membrane about the fauces and neighbouring parts was made up chiefly of a network of fibrillated lymph. The fibrillæ were very irregular in outline and dimensions, but generally comparatively thick, and they coalesced with one another in all directions so as to leave irregular spaces between them, which were small, and often not larger in diameter than the fibrillæ themselves. When seen in thickness, the tissue above described presented a pebbly character like that offered by an accumulation of nuclei; but the fallacious nature of such appearance was recognized on looking at the thin edge of a section; or by adding acetic acid, which rendered the whole transparent, at the same time expanding it, and bringing into view an exceedingly delicate and irregular network of well and sharply-defined, occasionally bulging, fibres, which appeared to be, so to speak, the skeleton of the original network. In some places the false membrane consisted of an apparently uniform layer composed of an extremely fine and indistinctly fibrillated tissue, studded with molecular matter, and presenting something of a ground-glass character. Imperfect epithelium was entangled here and there in the substance of the membrane, but was most abundant on the superficial surface.

The pus-like fluid in the tonsils consisted of well-marked pus-cells, characteristically affected by acetic acid. Some of the muscular tissue from the small muscles of the larynx, and from those of the neck was examined, and found to be striated and healthy-looking; but the spaces between the fibres were loaded with blood-corpuscles. The cellular tissue in front of the epiglottis presented a network of fibrillated tissue, like that constituting the false membrane itself, but the meshes were larger and more distinct.

The muscular tissue of the heart was found to be generally in an early stage of fatty degeneration, the transverse markings being nearly absent, and the fibres studded with minute molecules. But in the portions infiltrated with blood, the degeneration was more advanced than elsewhere, the striæ were wholly deficient, the fibres crowded, and in some cases opaque with beads of oil, many of which were of considerable size. The white pus-like spots in the right ventricle consisted simply of muscular fibres extremely degenerated.

The kidneys, though looking healthy to the naked eye, were really much diseased. The Malpighian bodies were generally healthy, but a few presented accumulations of oily granules between the capsule, and contained tufts of vessels. The epithelium of the tubes was generally opaque and granular; in many instances the peripheral surface of the cylinder of cells presented numerous oily globules; and not infrequently the tubes appeared filled with separated and irregularly clustered epithelial cells, loaded with oil so as to be almost opaque. In a few cases, tubes were filled with recently-extravasated blood; and occasionally transparent casts were seen floating about the field of the microscope. The contents of the medullary tubules were more generally unhealthy even than those of the cortical ones. Many contained transparent fibrinous casts, and the majority presented oily breaking down epithelial contents.

CASE 2.—*Diphtheria. Lobular Pneumonia, &c.*

M. A. F., a female servant, æt. 22, was admitted in the early part of February, 1853. No record of the case is preserved beyond the details of treatment. These details seem to indicate that on admission she was labouring under some acute affection of the lungs, that she soon became convalescent and was put on a course of tonics. On the 12th of March a sudden change of treatment took place; a blister was applied to the throat; a purgative was administered; a mixture containing æther and ammonia was prescribed, and wine, which had previously been administered in small quantities, was increased. This plan of treatment was persisted in, but she died on the 24th.

Post-mortem examination. — The mucous membrane of the pharynx, fauces, and base of the tongue was covered by a layer of lymph between a-half and a-quarter of a line thick. Its free surface was irregular, fissured, and in places flocculent. It adhered pretty firmly to, yet could easily be separated from, the sub-jacent mucous surface, which was congested, here and there excoriated, but nowhere distinctly ulcerated. The lymph ceased gradually at the lower part of the pharynx, and the œsophagus was healthy throughout. Both surfaces of the epiglottis, and the rest of the mucous membrane of the larynx, were similarly enveloped in a layer of adherent lymph. The deposit extended continuously from the superior to the inferior vocal cords, so as completely to conceal the orifices of the sacculi laryngis. On removing it, however, a prolongation from its deep surface was found to extend into the sacculi, and to form a kind of cast of them. As far down as the true vocal chords the lymph was as thick and abundant as in the pharynx; but below this it was less copiously deposited, and on the left side almost completely absent,—the uncovered mucous surface, however, being much congested. The mucous membrane of the trachea was congested, and a patch of lymph, continuous with that in the larynx, extended about an inch and a-half down its anterior surface. The mucous and sub-mucous tissues of the upper half of the larynx were much thickened, the epiglottis measuring a-quarter of an inch in thickness; and the calibre of the larynx, though quite pervious, was considerably diminished. The lymph was of a dirty greyish-brown colour, and moderately tough, allowing of removal in strips; but its deep surface was considerably tougher than its free,—the latter, indeed, being for the most part pulpy or shreddy. It was found, microscopically, to present an irregular and indistinct fibrous structure, studded with nucleus-like bodies, for the most part imperfect and irregular in shape.

Pleuræ healthy. Lungs of moderate size, but firmer, heavier, and more lacerable than natural. On section, they presented a peculiar appearance. They were much congested throughout, but displayed, on close examination, a peculiarly mottled aspect, owing to numerous patches of a dark colour being scattered uniformly and thickly throughout the substance of the organs, but

separated from one another by a network of lighter and more healthy-looking tissue. The solid patches were small, about the size of one or two lobules, generally discrete, but running occasionally into one another. They projected from the cut surface; had a dark colour, in some as black as that of pulmonary clot; were granular and solid; yielded on pressure no fluid, or at most a little bloody serum. They had more the appearance of apoplectic than of inflammatory formations, and, under the microscope, that idea seemed at first sight borne out by the vast numbers of blood-corpuscles floating about, and obscuring the tissues. On washing these away, however, the cells and intercellular passages were found to be filled with nuclei. In mass, these might have passed for pus; but floating about the field were many nuclei which appeared to be of the same nature, and these were round or oval, as nearly identical as possible with the nuclei in the cells of the bronchial mucous, and were unaffected by acetic acid. Moreover, when the air-cells containing them were acted on by acetic acid, and compressed so as to separate the nuclei, the latter were clearly seen not to be influenced like pus-corpuscles. The nuclei had a great tendency to cohere, so that no amount of pressure availed to squeeze them from the air-cells, or to separate them completely from one another. The intervening parts of the lungs were of a paler red, yet redder than natural and crepitant. The bronchial tubes were a little injected, and contained much frothy serous fluid. Pericardium and heart healthy.

CASE 3. *Diphtheria. Extension of disease along the Œsophagus.*

J. P., a cheesemonger, æt. 35, was admitted on the 29th of June, 1852, for psoas abscess. He was treated with tonics and stimulants, continuously up to the 13th of October. On that day two drachms of antimonial wine, and three of solution of acetete of ammonia were ordered to be taken every four hours; on the 15th, a blister was applied to the throat, and the same day he died.

Post-mortem examination.—Much emaciated; several ulcerated openings in the right groin.

The tonsils were healthy, but the surface of the pharynx

behind them was covered by a thick, loosely-adherent, white, doughy-looking material. This extended in large quantities half-way down the œsophagus; and in the form of aphthous patches studded the remainder of the œsophagus, and a small portion of the stomach in the neighbourhood of the cardiac orifice. The mucous surface of the pharynx and upper half of the œsophagus was extensively ulcerated; that of the lower half of the œsophagus much congested, and in many places excoriated. The interior of the upper part of the larynx, including the vocal cords, was loaded with a similar kind of material, and the mucous membrane was œdematous and ulcerated. The deposit appeared, under the microscope, to consist almost entirely of epithelium, mixed with fragments of fibrillated material, and extraneous matters accidently present. The lower part of the larynx and trachea were perfectly healthy; the lungs somewhat congested.

There was a large abscess in the course of the right psoas muscle, which communicated with the ulcerated openings in the groin, but was quite unconnected with bone. There was no other visceral disease.

Dr. J. S. Bristowe, *5th of April*, 1859.

XI. SPECIMENS FROM THE LOWER ANIMALS.

1. *Intestines of a Pig, which for six weeks before death had been fed with "Typhoïd Dejections."*

It it now pretty generally admitted, that the two forms of continued fever, typhus, and the fever which is ordinarily designated typhoïd, constitute well marked and distinct species of disease. That the true typhus is contagious, or that it may be communicated by the cutaneous or pulmonary exhalations from the sick to the healthy, is a fact which will admit of no dispute. There are many, however, who still doubt the contagious nature of the so-called typhoïd fever; although it seems difficult to account for the facts which have been adduced in France, more particularly by

Bretonneau,* Gendron,† and Piedvache,‡ in any other way, than that this fever also may occasionally be communicated.

A distinguishing feature in this fever is the ulceration which takes place in the bowel, which in many cases gives rise to diarrhœa. Now, it has been imagined by some observers, and especially by Dr. Budd of Bristol, and the late Dr. Snow, that the fever is propagated by the dejections from the bowels, either through the medium of the drains or of the water which is drank. There are many facts which lend considerable plausibility to this supposition; but, without entering into the question of its validity, I would simply remark, that I believe many of the cases which have been urged in its support, may be explained on the hypothesis of a spontaneous origin of the fever from the putrid emanations from the drains, which have been thought merely to convey the poison. It is worth observing, that all those who have considered that the fever might be communicated by the dejections, have been strong opponents of the possibility of its spontaneous origin.

Be this as it may, it is obviously of great importance, both in a medical and a sanitary point of view, to determine, whether fever may be communicated in the manner just alluded to. The experiment to which I am about to allude, was undertaken in order to throw some light upon the question; and the results are offered, simply for what the results of one experiment may be worth.

The animal selected for the experiment was a pig, and for the following reasons:—

1. In its diet, this animal approaches most nearly to man; while it was thought that less difficulty would be encountered in making it submit to the experiment, than might be the case with many other animals.

2. There are few or no animals in which the structures which become specially diseased in typhoïd fever—viz.: Peyer's glands —are so well developed.

3. We have evidence, that the disease in question is met with

* Archiv. Gen. de Med., Ser. 1, Tom. X., p. 166.

† Journ. des Connais. Med.-Chir., 1834.

‡ Mem. de l'Acad. Nat. de Med. Tom. XV., 1850, p. 239.

in the pig, as well as in many other of the lower animals. Cases of typhoïd fever in the pig, in which the characteristic lesions were found after death, have been described by Falke,* and other German writers on veterinary pathology. For references to several such cases, I am indebted to Mr. Gamgee of the Veterinary College, Edinburgh.

The individual pig selected was between three and four months old. Care was taken that the dejections were obtained from typhoïd patients, in which they presented the light-ochrey colour peculiar to the disease, in the most marked degree; and they were mixed up with barley-meal and other articles of food. The first was given on the 9th of September, 1858. For the first three weeks, one was given every day, or every second or third day. During the next fortnight, two or three were given every day; and during the last week, one every second day. They were eaten greedily. On two different occasions during the first fortnight, the animal had slight diarrhœa, lasting for twelve hours, and its ears felt rather hot, but these symptoms speedily subsided. With these exceptions, the animal exhibited no abnormal symptoms; its appetite was unimpaired, and its stools were of natural consistence; while it increased greatly in weight and size, as will be seen by the following measurements, taken at the commencement and at the termination of the experiment.

	Sep. 9th.	Oct. 23rd.
Circumference at middle of belly .	25¾ in.	29 in.
Ditto behind fore-legs . .	23 in.	27 in.
Ditto in front of hind-legs	22½ in.	26 in.

On the 23rd of October the animal was killed, and its body opened. There was abundance of sub-cutaneous fat, and the muscular tissue appeared healthy in every respect. The intestines throughout were healthy. There was not the slightest trace of any recent or old ulceration anywhere, nor of any thickening or alteration of Peyer's patches, or of the solitary glands. The mesenteric glands were not enlarged.

The parts exhibited to the Society are the lower three feet of the ileum, and the first ten inches of the large intestine.

Dr. Murchison, 16*th of November*, 1858.

* Memoir on Abdominal Typhus, published at Leipzig. A.D. 1840.

2. *Mammary Cancer in a Bitch.*

The animal from which this specimen was removed about four months ago is twelve years and a-half old, and has had numerous litters of puppies, which have been weaned too soon more than once, leaving the mamma distended, hard, and painful. The disease has been growing for more than three years, during which time she has had puppies.

Present condition. — November the 7th; the wound caused by the operation has healed with the exception of two small spots, one of the size of a lentil, which is covered by a scab, and the other at the upper part of the wound from which a larger scab has just been removed, leaving a little moist spot the size of a pin's-head.

Besides the change in the gland itself, which is hard and lobulated, there are many detached small, hard, rounded masses of like structure, surrounding the gland. The juice of the tumour, when fresh, exhibited round, fusiform, and caudate nucleated cells, together with oil globules, and minute granules of no determinate form; but since its maceration in spirit, the round cells greatly predominate, with oil globules and granules.

Dr. Ogier Ward, 21*st of December*, 1858.

---

3. *Specimens of Coagulation of the Blood in the Lower Animals.*

Among these was the coagulated blood of an elephant that died at the Regent's-park Gardens. The animal appeared to be in perfect health until a severe thunderstorm occurred, when it seemed to be much frightened. It trembled frequently, had profuse watery diarrhœa, and died the next day. On examination soon after death, Dr. Crisp found all the viscera apparently in a normal condition. but the blood generally was coagulated and free from serum. It was tough, and could readily be pulled out of its vessels. Thus one portion exhibited from the posterior canal and iliac veins measured four feet in length. In this instance, the coagulation was probably wholly or in part due to the loss of serum from the bowels.

Dr. Crisp remarked that there was still a great deal of mystery

respecting the cause of the deposition of fibrine in the heart and large vessels. He had found these deposits very frequently in the lower animals, especially in birds, and in the chelonian reptiles in confinement. In some animals dying of chronic diseases (the antelopes especially), the fibrine was in very large quantities; so that its relative proportion, instead of being two or three per cent., amounted to fifteen or twenty. He was disposed to attribute this increase to a partial loss of vitality of the blood during life, and the consequent deposit of fibrine. Dr. Crisp had kept the blood of various animals in stoppered-bottles for five years, and in all the specimens, whether fluid or solid, he obtained the crystals of hydrochlorate of ammonia, and the white fumes on the application of a glass rod, dipped in hydrochloric acid, to the mouth of the bottle.

Dr. Crisp, *15th of March*, 1859.

---

4. *Two Puppies with Hare-lip.*

These pups were both from the same bitch, but of different litters. They have each a fissure in the upper lip, and a slight corresponding notch in the hard palate. In one the fissure is on the left side (as it is, most commonly, in the human subject), while in the other it is on the right side of the median line. One pup was killed immediately after birth, but the other lived for some weeks. Mr. Christopher Heath, *3rd of May*, 1859.

---

5. *Calcareous infiltration of the Kidneys of a Parrot, with Softening (Post-mortem Digestion?) of the lower part of the Œsophagus.*

This bird, æt. 9, was in excellent health till the day of its death, when it looked ill, its feathers were ruffled, its wings drooped, and it had lost all its vivacity and appetite. It was sick, and made many efforts to vomit, and had slight diarrhœa. It took only a little milk during the day. It died in the night; and as it was thought to have been poisoned, I offered to examine it three days after its death.

There was no fat in any part of the body, though the cellular tissue had the appearance as if the fat had been removed by ab-

sorption. The lungs were congested and œdematous. The kidneys were enlarged, and of a light flesh-colour, and infiltrated throughout with calcareous matter in the form of spheres and lines, as though it occupied the Malpighian bodies and tubuli. The craw contained some milk, highly acid. Its membrane, and that of the œsophagus, were pale and firm down to three quarters of an-inch above the gizzard, where it became quite soft, and separated from the lower portion, round the edges of which, at intervals of a quarter of an-inch, were a number of green grandular bodies, the size of small shots. The lining membrane of the gizzard was tinged with bile, but healthy; and the lower bowels were generally softened, and of a pink colour. There was a quantity of matter like imperfectly coagulated milk in the cavity of the abdomen. There was no anasarca.

Dr. Ogier Ward, 17*th of May*, 1859.

---

6. *Drawing, showing Atrophy of the Muscles on one side of the Larynx of a "Roarer" (Horse). Observations on Modifications of the Human Voice, Cough, &c., in consequence of a greater or less Paralysis of the Laryngeal Nerves by pressure.*

The drawing consists of a posterior view of the horse's larynx, in which the posterior Crico-Arytænoïd muscle, &c. (dilator of the glottis), on the left side, was seen to be in a very pale and completely dwindled state.—(See Woodcut 19.) The fibres of the corresponding muscle on the opposite side are, on the contrary, quite abundant, being, indeed, apparently hypertrophied, firm in texture, and of a dark-red colour. Moreover, there is an unusual condition of part of the cartilaginous structure of the larynx, the free border of the "rima glottidis" on the left side being considerably thinner than that on the other side, and also possessing a less convexity inwards. The original specimen was the property of Mr. Field, the veterinary surgeon, in whose museum it had existed for a length of time, and had been kindly lent to me by Mr. W. Field, Jun., in order that I might have a representation of it made. The exact history of the specimen is a little doubtful, as it is not quite clear whether it is one in which the unwonted condition of the laryngeal muscles

in question has been caused by disease, or is the result of experimental interference (which, as I shall attempt to show later on, is the most likely supposition).

I brought the drawing before the notice of the Society, in re-

WOODCUT 19.

Represents the posterior laryngeal muscles of the horse; those of the right side are seen to be in a plump and healthy condition, while on the left side a few shrunk and pale fibres alone remain. (From a drawing by Mr. Richmond, jun.)

ference to a subject with which all practical medical men are conversant, viz., the alteration of the human voice, and the peculiar noise attendant upon the breathing in certain morbid states wherein the pneumo-gastric nerve, or its "recurrent laryngeal" branch, are materially involved—a subject which has, on more than one occasion, received the attention of this Society. The peculiarity in respiration alluded to is almost exclusively confined to the act of *in*-spiration, which acquires a character that may be termed at one time "gruff," or "rhonchial," or "raucal;" at another, "shrill," "stridulous," or "whistling." This pecularity of inspiration is well exhibited in certain cases of tumours or aneurysms

in the neck, or within the thorax;* but of course it is in some degree recognized also in many other diseased conditions, in which obstruction to the passage of air towards the lungs exists in various parts of the respiratory tract; albeit in none to so well-marked a degree as in those instances where the chink of the glottis is narrowed or occluded during inspiration, either owing to positive spasm of the constrictor muscles of the aperture, or to paralysis of the intrinsic laryngeal muscles, which permits the collapse or approximation of the arytænoïd cartilages during the act of inspiration, by reason of the pressure of the air when indrawn, to supply the vacuum attendant on the previous expiration. The peculiarity in the respiratory efforts above spoken of, as well as the modifications of the strength, pitch, and quality of the voice, and the unusual character of the cough observed in certain cases of disease in man (so markedly exaggerated under emotion, quick muscular movement, or any effort which induces accelerated breathing in the patient), has often struck me as being very analogous to that which, in the case of the horse, obtains for it the epithet of "roarer," "high-blower," "piper," "wheezer," "whistler." As in the case of the horse, great difficulty in diagnosis as to the causation of the roaring is frequently met with,† so it is often a question in human patho-

* It must not be forgotten, that in these affections this character of the inspiration may in some cases be *tracheal* in its source, or even *bronchial* as well as laryngeal, by reason of direct pressure upon the various parts of the air-passages, wholly independent of any interference with the recurrent laryngeal nerve.

† It appears that the various deviations from the natural condition as respects the breathing, in horses which come under the generic title of "roarers," have been traced to a great variety of causes, but the pernicious influence of almost all of them may be ultimately traced to a narrowing or obstruction of some parts of the cavities or tubing through which the air has to pass on its way down to the lungs. For example, amongst the multifarious causes assigned for this affection in different works I find the following enumerated:—"thickening and induration," or "ulceration" of the lining mucous membrane of the glottis, and the different parts of the larynx, trachea, &c.; "cicatrices," "foreign bodies," "tumours," "cysts," "abscesses," in connection with the above parts; "layers and bands of fibrinous exudation" on the free surface or across the diameter of the larynx or trachea; affections of the laryngeal cartilages themselves, such as "fractures" and other injuries, "ossification" and thickening as from old-standing disease; "distortion," as often brought about by long-continued or tight reining or curbing, as in the breaking-in of carriage horses, establishing,

logy, of much interest and no slight difficulty, to decide upon the exact origin of the peculiar alteration of the voice or breathing under consideration.

This leads me to speak of the modification of voice, whether respective of the strength, or timbre, or powers of modulation so often noticeable in cases of *pulmonary phthisis*. My impression has long been (and, indeed, according to my experience, post-mortem research has demonstrated it to be so) that the affection of the voice in this disease is, by no means infrequently, quite *un*-connected with any altered condition of the mucous membrane of the parts forming the upper outlet of the larynx, such as we do very frequently meet with in this class of cases, and which, either alone or with an attendant affection of the vocal chords, completely accounts for the hoarseness, or other altered conditions of the voice, cough, &c. It is known that the peculiar arterial whiff or bruit, often audible within the upper part of the chest, apart from any intrinsic disease of the blood-vessels, has been supposed by some to be referrible in many cases to pressure upon, and consequent indentation of, some of the large intra-thoracic vessels by tubercular and consolidated lung-tissue. Should this supposition be correct, I see no impro-

for the sake of a proud bearing, a constrained and unnatural position of the head and neck; or the constant use of the neck-strap in place of the halter, the use of ill-fitting collars, or much pinching of the larynx (often resorted to with a view to the testing of unsoundness), especially in the case of young horses whose cartilages are yielding. Simple spasm of the glottis-closing muscles, owing to superficial ulceration of the mucous membrane at the upper aperture of the larynx is spoken of as a cause, at times, of the various forms of roaring; and also certain diseases in the neighbourhood of the larynx, such as abscesses, diseased salivary glands, &c., which induce atrophy or destruction of the adjoining intrinsic muscles of the larynx. Some of the French writers have attributed it, in some cases, to enlargements or ganglia, situated on the pneumo-gastric nerve, and to various kinds of poisonous agents, animal, vegetable, and mineral.

Mr. Percivall in his "Hippopathology," mentions that the seat of roaring is "occasionally" in the *lungs* themselves, and quotes Mr. Turner to the same effect. In such cases, it is most likely that "wheezing" is the special affection produced.

For a most interesting case of "roaring," in which the cause (unforeseen during life), proved to be a diminished capacity of one of the nasal fossæ by excessive enlargement of one of the turbinated bones, owing to extreme dilatation of its bony cells, see the "Veterinarian," Vol. X., 1837, as described minutely by Mr. James Turner. It is a curious fact that there are several instances on record proving the frequent *hereditary* character of "roaring."

bability in conjecturing that the nervous structures abounding at the upper part of the chest (and among them the recurrent laryngeal, or the main trunk of the pneumo-gastric nerve) may in some cases become involved.* And this might, of course, also occur, not only from the pressure of the consolidated and distended lung, but also as a result of implication of the nerves by thickening with puckering and induration of the neighbouring inflamed pleuræ, or by pressure from certain pleural exudations external to the lung-substance, consequent upon neighbouring inflammatory action. In this manner might the laryngeal muscles (on one or other side), which are innervated by the nerve branch in question (*i.e.*, the whole of the intrinsic muscles of the larynx, as well constrictors as dilators, save the crico-thyroïd) become interfered with, their action more or less diminished, and their nutrition proportionately impaired.

In such a case, whilst the chest-expanding or chief inspiratory muscles were, it may be, even more than usually active—("the consent of motion," as Le Gallois says "between the muscles of the glottis and those of the chest being arrested"), and the downward force or pressure of the inspired air was approximating the arytænoïd cartilages, which, by reason of the paralysis of their muscles, would be unresisting; the aperture of the glottis would become diminished or even quite closed, thus producing the modifications of voice and cough, or even actual stoppage of breathing quite independent of any diseased condition of the respiratory mucous membrane at any part.† That this unnatural state of the glottis might arise, in natural disease, in consequence of such an interruption of influence from the recurrent laryngeal,

* The relation of the recurrent laryngeal nerve to the lung and pleura on *either* side of the chest, whether, *i. e.*, as hooking round the aortic arch on one side, or the first part of the subclavian artery on the other, would render the supposition tenable.

† In some horses who are roarers, owing to disease of the upper part of the larynx, the power of coughing is wholly absent, the necessary forcible preliminary closure of the glottis being prevented.

Diminution of this power of coughing in man I have also seen from the same cause in one or two Hospital patients, the subjects of syphilitic disease of the larynx. In one patient I found that in no way could I satisfactorily induce vomiting either by tickling the fauces or by actual emetics given by the stomach, and his breathing on any hurry assumed quite a roaring character.

is fully borne out by the remarkable experimental investigations of such observers as M. Dupuy, who, in 1826, found* that *roaring* in the horse was the direct and constant result of section or compression of the eighth pair of nerves. Many other experimentalists might be quoted, who found the same result, as may be seen related in the various works devoted to veterinary subjects; but I will venture to quote a forcible passage from the "Veterinarian" for 1837, Vol. X. p. 77,† in which the results of the operation are graphically described by the late Mr. John Field, who assisted Mr. Herbert Mayo in several of his experimental inquiries. That gentleman observes as follows:—"Having ascertained that the organs of respiration of a horse used for farm purposes were sound, I cast him, laid bare the recurrent nerve of the off side, and passed a ligature loosely round it: he was then allowed to get up, and after a few minutes galloped severely without evincing the slightest defect in his breathing: the nerve was then drawn forward by the ligature. and one inch and a-half of it excised; and immediately on only trotting the horse a short distance such a degree of roaring was occasioned, that, had the exertion been continued he would soon have fallen.‡ I kept this horse four years; and although his breathing became better, he always continued a sad roarer. At the end of that time I destroyed him for the larynx, which exhibited the usual condition of wasted muscles on the side deprived of the influence of the recurrent nerve."§ The above detailed

* See Mr. Percivall's Hippopathology, Vol. II., p. 47, 1840, wherein reference upon this subject is made to the "Recueil de Medecine Veterinaire."

† A Monthly Journal of Veterinary Science, edited by Mr. Percivall and Mr. Youatt at one time.

‡ I have found it stated that roarers have been known to drop down dead when put to very extreme exertion owing to apnœa.

§ The obvious value of the above-mentioned preparation, and the excessive importance of the experiment would of course render it a matter of imperative necessity that it should be preserved; and I am, I believe, right in assuming that the specimen in the present Mr. Field's Museum, from which my drawing was taken (and the doubtful history of which I alluded to above), is the identical one here described so circumstantially by the late Mr. Field.

One or two other specimens also exist at the present time in the same museum, illustrating atrophy of laryngeal muscles in "roarers," but they are

experiment and all of the same nature are replete with the highest physiological interest, and in a practical point of view have a most valuable bearing, inasmuch as they throw considerable light upon those cases in which the glottis in man becomes for a certain length of time manifestly more or less narrowed by muscular contraction, whether this have remote origin in causes inhibiting the nervous supply furnished to the laryngeal muscles, thus more or less paralyzing them, allowing the in-drawing or approximation of the arytænoïd cartilages and ligaments of the glottis during the *in*-spiration of the air; or whether it is to be sought in causes producing active and immediate spasm of the constrictors, such as we have for example, in what is termed "laryngismus," either that frequently met with in children, termed "spasmodic croup" or "laryngismus stridulus,"—or the laryngeal spasm of hooping-cough, or that so frequently encountered in the epileptic and certain hysterical seizures, and allied affections.

The whole subject is also illustrated by the various experiments undertaken for the purpose of showing the influence of the pneumo-gastric nerve and its recurrent laryngeal branch upon the voice and breathing, from the time of Ruffus of Ephesus,* Galen,† Vesalius,‡ Mundinus,§ down to modern days when we have the researches of such observers as Morgagni.‖ Drelincourt.¶

much less marked instances than the above-mentioned one. I observe that Mr. Porter, in his article on the Larynx, in "Todd's Cyclopædia of Anatomy and Physiology," states, that Sir P. Crampton had seen examples of Atrophy of the laryngeal muscles removed from "roarers," in the Veterinary College of London. Mr. Porter also alludes to mention made by Andral of atrophy of these muscles in case of loss of voice.

The Veterinarian "(op. cit.)" and other works of the same character contain several cases related by correspondents in which atrophy of the intrinsic laryngeal muscles was met with in old "roarers." The subject is alluded to by Dr. Stokes in his work on "the Diseases of the Heart and Aorta," 1854, p. 569, and mention also made of a similar case submitted to the Dublin Pathological Society by Dr. Smith.

* Morgagni de Sedibus et Causis Morborum, &c.—Ep. XIX., Art. 23.

† De Locis Affect.. Class. 4ta., Lib. I., C. VI.

‡ Hum. Corp. Fabric, 1555, VII-XIX., p. 571.

§ About the 14th century, quoted by Haighton.

‖ Appellationes Part. Hum. Corp., Paris, 1554, p. 32.

¶ Experim. Anatom., 1681.

Brunn,* Dr. George Martin,† Haighton,‡ Monro secundus,§ Dupuytren, Günther,‖ Reid,¶ Gurlt and Hartwig,** Longet,†† Romberg,‡‡ and others too numerous to quote.§§

As regards the interesting question, whether the larngeal or vocal muscles can be supposed capable under any circumstances of regaining their function (one of no slight moment in clinical studies), I will quote the experiments (before alluded to in a foot note) of Mr. Haighton, who whilst satisfactorily determining that the recurrent branches of the pneumo-gastric nerve were the true vocal nerves, showed that the voice could "when taken away by a division of the vocal nerves, again return." He alludes to the circumstance, that even Galen had considered that the voice "ought to return after it had been lost by experiment;" but that supposition of Galen's was merely founded on the fact (of which he was aware) that a communication existed between the recurrent and the upper laryngeal branch.‖‖ Haighton proves by experiment, however, that the reëstablishment of the voice does not depend on this nervous communication but on another cause, and that is the reunion of the divided nerve.

* Leipzig Commentaries for 1755.

† Paper in the "Medical Essays and Observations," Edinbro'. Vol. II., p. 96, styled "The experiment of cutting the recurrent Nerves carried on further than has hitherto been done."

‡ Paper in the "Memoirs of the Medical Society of London," Vol. III., p. 422, on the determination of the effects of the division of the upper and recurrent laryngeal branches of the eighth pair, on the voice.

§ Observations on the nervous system, 1783, p. 65.

‖ Zeitschrift f. d. Gesammte Thierheilkunde, &c., Vol. I., p. 267, quoted by Romberg.

¶ Edinbro' Medical and Surgical Journal, 1838-1839.

** Magazin f. d. Gesammte Thierheilkunde, 1841, No. 1 p. 98.

†† Recherches Experimentales sur les Fonctions des Nerfs. des Muscles du Larynx, p. 21-22.

‡‡ Manual of the Nervous Diseases of Man, Sydenham Society, Vol. II., p. 320.

§§ References to various experimenters are made by M. Le Gallois, in his Experiences sur le Principe de la Vie, 1812, p. 202.

‖‖ Galen (*loc. cit.*) mentions the circumstance of two boys, from whose necks strumous masses were removed by an ignorant Surgeon, who tore away along with the tumours, in one case, one of the recurrent nerves, and in the other, both of these nerves. Of the one boy, Galen observes, "sed mutum reddidit;" of the other, "ipsum similiter semimutum reddidit.

It is obvious, that this ascertained fact of the possibility of a return of the voice after excessive injury, or even excision of a part of the nerve is of some practical import when we come to consider, in certain cases, the feasibility of performing the operation of tracheotomy for the relief of laryngismus, depending on pressure at some distance from the glottis, or such operations about the neck as may tend to involve the main pneumo-gastric nerve itself.

As an appendix to the above observations, I cannot resist the wish to draw attention to three deeply interesting cases, illustrating the subject of this communication. The first is one of a man which I find related by Dr. Brinton in Vol. III. of our "Transactions," p. 304, and in which was an aneurysm of the arch of the aorta, considerably destroying the trachea, and having in the substance of its walls the left recurrent laryngeal nerve. On minute examination, the structure of the nerve at the part involved was found completely altered, and the muscular fibres of the laryngeal muscles on the same side were paler than on the opposite side, their transverse striæ being much less distinct, &c. Among other symptoms during life were recorded stridulous breathing, especially on inspiration, and partial loss of voice. A second case (a very marked one) was that of a woman, described by Dr. Todd at page 208 (Feb. 26, 1853), of the sixth volume of the "Medical Times and Gazette," which is the case, I believe, alluded to by Dr. Stokes, in his work before quoted, on the Heart and Aorta, p. 569. A third noteworthy case, of a similar nature (the pressure being caused by a cancerous tumour of the neck), is related by Dr. Budd, at page 62 of *this* volume, in which dyspnœa, the result of injury to the recurrent nerve, caused death. Our medical works and periodicals contain several cases in which alterations in the character of the cough, voice, and breathing have resulted from pressure upon this nerve-branch, or the main trunk of the pneumo-gastric from which it emanates.

Postscript.—Since writing the above, I may state that I have seen two interesting wax models, showing atrophy of the posterior intrinsic muscles of the larynx (in connection with roaring), in the Royal College of Veterinary Surgeons, Red Lion-square,

London. I have also, by the courtesy of Professor Varnell, seen several specimens of the dissected larynx of the roarer (perhaps those alluded to by Sir P. Crampton), in the Museum of the Royal Veterinary College, Camden Town. All these, like the one which I have had illustrated above (and also the wax models), showed the atrophy on the LEFT side; and Professor Varnell told me that he does not remember ever to have seen the muscles on the right side affected, unless in cases where BOTH sides were involved. He showed me specimens in which abscess connected with the trachea, as also distortion of the trachea, and tumours connected with the epiglottis, had been severally the causes of roaring. He also said that he had seen atrophy of the laryngeal muscles of the horse owing to ankylosis between the arytænoïd and cricoïd cartilages. Dr. JOHN W. OGLE, 17*th of May*, 1859.

INDEX.

Abscess in the right lumbar region, attached to the kidney - 190
„ in the pons Varolii - 14
Abscess-like dilatation of the calices of the kidney - - 209
Aconite, suicidal poisoning by 285
Amputation of the right leg, two years after excision of the knee-joint - - 220
Amylaceous compounds, on the existence of in the human body 299
Aneurysm of the aorta, with a peculiar condition of the liver 99
„ of the arch of the aorta 73, 76
„ — cured - - - 83
„ of the intra-pericardial portion of the aorta, rupture of - 105
„ of the abdominal aorta—death from accumulation of effused blood round the œsophagus 84
„ of the anterior communicating artery, rupture - - 3
„ of the innominate artery - 106
„ enormous, of the right subclavian artery - - - 103
„ small, in the substance of the cerebellum - - 4
„ of the heart, ruptured - 111
Angina, scarlatinous membranous, pharynx of a child affected with 139
Animals, specimens from the lower 334
Ankle-joint, strumous disease of, followed by necrosis and acute periostitis of the tibia - 214
Anstie, (Dr.) softening of the spinal cord, from concussion arising from fracture of the cranium, and of the sixth cervical vertebra - - 59
Aorta, aneurysm of, with a peculiar condition of the liver - 99
Aorta, *continued.*
„ communication of with the left bronchus - - 71
„ arch of, aneurysm of the 73, 76
„ — cured aneurysm of - 83
„ thoracic, constriction of - 77
„ — obliteration of - - 97
„ the intra-pericardial portion, aneurysm of, ruptured - 105
„ abdominal, aneurysm of - 84
„ — wound of from a pistol-shot 168
Aortic valves, rupture of, by violence 92
Aphthous exudation, microscopic drawings of deposit in - 311
Apnœa, death by, in a case of disease of the sphenoïd bone, &c. - - - 224
Appendix vermiformis, ulceration of the - - - 151
„ contained in the sac, in a case of inguinal hernia - 170
Arms, case of a boy with arms only two inches in length - 308
Arterial obstruction, producing fatal phagedæna of the face - 101
Artery, anterior communicating, aneurysm of - - 3
„ basilar, obstruction of - 49
„ internal carotid, obstruction of, and their branches - 50
„ cerebral, obstruction of by clots 21
„ — cause of obstructive coagula in - - - 44
„ — analysis of seven cases of obstruction of - - 44
„ innominate, aneurysm of the 106
„ left internal, blocking up of 54, 56
„ pulmonary, impervious at its origin - - - 90

Artery, *continued.*
„ — contraction of its orifice, from fusion of the valves - 107
„ — detachment, and impaction of fibrinous concretion in 114
„ right subclavian, enormous aneurysm of - - 103
„ — abnormal origin of the - 119
„ vertebral, obstruction of - 49
Ascites, in a case of cancerous tubercle of the liver, &c. - 179
Astragalus, dislocation of the 224
Atelektasis pulmonum - 61
Atrophy of the right hemisphere of the brain, with distention of the lateral ventricles - 38
„ of the left cerebellar hemisphere 38
„ total, of the gall-bladder - 176
„ of the kidney - - 199
„ of the muscles of the larynx of a "roarer," (horse)- - 339
Auricle, right, communication with the left ventricle, from perforation of the septum - 110

Ballard (Mr. T.), the stomach of an infant, the posterior wall of which was extensively destroyed by the gastric juice - 172
„ specimen of encephaloïd cancer of the kidney - - 188
Baly (Dr. William), malformation of the heart—the pulmonary artery impervious at its origin 90
„ ulceration of the œsophagus near its lower extremity, completely preventing the passage of food 165
„ — *report* on, by Dr. Bristowe and Dr. Markham - 167
„ case of fatal obstruction of the small intestines by a gall-stone 184
Barker (Dr. T. A.), case of hydatid in the brain - - 6
„ case of croup, in which the false membrane extended from the fauces to the minute bronchial tubes - - - 69
„ extensive dilatation of the œsophagus - - - 140
Birkett (Mr. John), right inguinal hernia developed in childhood; testis over the external abdominal ring; reduction of the hernia; adhesion and perforation by ulceration of the walls of the intestine at the seat of stricture; death from peritonitis 128
Bladder, communication of with the sigmoïd flexure of the colon 208
„ — ditto, the result of ulceration of a false diverticulum - 131
„ ulceration of the - - 190
Blood, obstruction to passage of through the veins, etc., of the cranium, and resulting disease - - - 28
„ coagulation of, in the lower animals - - - 337
Bones, diseases, etc., of 211-236
Bones of the leg, fracture of, following ulceration from epithelioma 234
„ inter-maxillary, necrosis of 216
„ fœtal, retention of, in a uterus affected with cancer - 210
Brain of an idiotic boy, eleven years of age - - - 15
„ cases illustrating disease of, as a result of obstruction to the passage of blood through the veins and sinuses of the cranium 28
„ atrophy of the right hemisphere of the - - - 38
„ case of hydatid in the - 6
„ softening of the anterior lobes 50
„ — of posterior part of left hemisphere - - - 49
„ — extensive, of surrounding corpus striatum - - 54
„ red softening of, from syphilitic disease of the bones of the cranium - - - 8
„ syphilitic disease of 21, 56
„ cholesteatomatous tumour of 24
Bristowe (Dr. J. S.), aneurysm of the anterior communicating artery—rupture - - 3
„ aneurysm in the substance of the cerebellum, gout, renal disease, etc. - - - 4
„ fatal epilepsy, resulting from superficial cerebral hæmorrhagic effusions - - 11
„ syphilitic disease of the brain and liver, with obstruction, by clots, of cerebral arteries - 21

BRISTOWE, *continued.*
„ analysis of seven cases of obstruction of the cerebral arteries 44
„ — tabular arrangement of ditto 57
„ cured aneurysm of the arch of the aorta - - - 83
„ case of aneurysm of the abdominal aorta—death from accumulation of effused blood round the œsophagus, and consequent obstruction - - 84
„ disease of the tricuspid valve—detachment of fibrinous concretion, and impaction of the same in the left division of the pulmonary artery - 114
„ case of enteritis - - 148
„ association of cystic disease of the liver and kidneys - 174
„ specimens showing the coëxistence of tubercle and cancer; cancer of the uterus; tubercle of the lungs - - 284
„ on the morbid anatomy of diphtheria, with three cases - 321
„ *report* on Dr. Baly's case of ulceration of the œsophagus 167
„ and Mr. W. M. ORD, inquiry into the existence of amylaceous compounds of the human body 299
„ see PEACOCK (case of stricture of the ileum).
BRODHURST (Mr. B. E.) dissected specimen of non-congenital club-foot, of paralytic origin, and of fifty years' standing 279
Bronchi, cicatrization and contraction of, after expectoration of rings - - - 60
Bronchial tubes, fibrinous casts of, (note of additional particulars and post-mortem of the case at p. 53 of vol. IX.) - 65
Bronchus, left, communication with aorta - - - 71
Bronzed skin, in case of tubercular disease of supra-renal capsules 266
„ extensive, in case of diseased supra-renal capsules - 269
„ with disease of the supra-renal capsules - - - 273
„ supra-renal capsules healthy 264
Bronzed skin, *continued.*
„ absence of, in case of diseased supra-renal capsules - 268
„ — in tuberculous disease of supra-renal capsules - 268
„ — in extensive disease of the supra-renal capsules - 271
„ — in case of epithelial cancer of one supra-renal capsule - 272
BROOKE (Mr. Charles) erectile tumour of the leg - - 243
BRYANT (Mr. T.) strumous disease of the right testicle in a child aged two years and a-half 191
„ necrosis of the inter-maxillary bones - - - 216
„ old disease of the knee-joint repaired - - - 229
„ disease of the hip-joint of fifty years' duration - - 230
„ hydatid developed beneath the fascia and short head of the biceps femoris, removed entire - - - 243
„ malformation of the left lower extremity - - 305
BUCHANAN (Mr. A.), *per Dr. G. Buchanan*, case of invagination of large intestine in an infant 171
BUCKLAND (Mr. Frank), peculiar condition of human skin [in a long-buried corpse] pyramidal-shaped vegetable growths 299
BUDD (Dr. George), cancerous tumour in the groove between the trachea and œsophagus—death from dyspnœa by destruction of the left recurrent - 62
„ hydatid tumour in the apex of right ventricle of the heart 80
„ enormous hydatid tumour of the omentum accompanied by nine small hydatid tumours - 132
„ cancer of œsophagus, causing a large opening into the trachea, just above the bifurcation—food passed from the œsophagus into the trachea and rejected by coughing - - 145
Burn, epithelial cancer in the cicatrix of a - - - 253
Burnet's disinfecting fluid, stricture of the pylorus from the destructive action of - - 164

Cæcum, portion of, discharged by stool, in a case of intus-susception - - - 160
Calculi, numerous and unusually large, in a kidney - 197
Cancer, specimens showing coëxistence of, with tubercle - 284
„ mammary, in a bitch - 337
„ of the œsophagus, causing a large opening into the trachea 145
„ of the uterus - - 284
„ — retention of fœtal bones in 210
„ colloïd, of the sigmoïd flexure of the colon - - 136
„ — from the calf of the leg 256
„ encephaloïd, of the kidney 188
„ — of the testicle - - 205
„ epithelial, in the cicatrix of a burn on the arm - - 253
„ — of the œsophagus opening into the trachea - - 130
„ — of one supra-renal capsule, and of the tongue - 272
„ secondary, of the femur, followed by spontaneous fracture - 235
Cancerous tubercle of the liver and stomach - - - 179
„ tumour in the groove between the trachea and œsophagus 62
„ — of the mediastinum - 240
Canton (Mr.), *per Mr. Price*, portions of bones forming the left knee-joint, removed by excision on account of accident, and false joint which resulted 232
Carcinoma of the œsophagus - 159
Carcinomatous stricture of the œsophagus - - - 142
Cartilaginous tumour of the skull and face - - - 250
Casts, fibrinous, of the bronchial tubes - - - 65
„ membranous, of trachea and bronchi, in case of diphtheria 320
Cavity, large, in the head of the tibia—query, hydatid? - 233
Cells, epithelial, contained in an ovarian cyst - - 201
Cerebellum, small aneurysm in the substance of - - 4
„ atrophy of the left hemisphere of 38
„ of a child, encephaloïd tumour attached to - - 26
Cerebral arteries, obstruction of, by clots - - - 21
„ — analysis of seven cases of obstruction of - - 44
„ hæmorrhage, fatal epilepsy from superficial - - 11
Chalk (Mr. Oliver), colloïd cancer of the sigmoïd flexure of the colon, causing stricture and obstruction, complicated with incarcerated hernia - 136
Cholesteatomatous tumour of the brain - - - 24
Chordæ vocales, case of epithelial or warty growth upon - 311
Circulation, Organs of; diseases, etc., of - - 71-128
Club-foot, non-congenital, of paralytic origin, dissected specimen of - - - 279
Coagula, obstructive, cause of, in cerebral vessels - - 44
Coagulation of the blood in the lower animals, specimens of 337
Colloïd cancer of the sigmoïd flexure of the colon - - 136
„ —from the calf of the leg - 256
„ disease of the liver - 178
„ pseudo, ovarian tumour, successfully removed - 197
„ — ditto, removed during life, by ovariotomy - - 200
Colon, opening of, in case of obstruction of the rectum from scirrhous and colloïd disease 157
„ portion of, discharged by stool, in a case of intus-susception 160
„ meso-, fatal obstruction, from twisting of - - 153
„ sigmoïd flexure of, communication with the bladder - 208
„ — colloïd cancer of - 136
„ — simple stricture of - 161
Concussion, softening of the spinal cord from - - 59
Congestion of the brain, without softening - - - 50
Constipation from stricture of the sigmoïd flexure, relieved by opening the left colon - 161
Constriction of the thoracic aorta 77
Cooper (Dr. C. T.), case of retention of fœtal bones in a uterus affected with cancer - 210

Coots, *continued.*
„ secondary cancer of the femur, followed by spontaneous fracture - - - 235
„ extensive disease of the supra-renal capsules; no discoloration of the skin - - 271
Corpus striatum, effusion of blood into the left - - 54
„ congestion of the right - 53
„ softening of the right 50, 51
Coulson (Mr. T. W.), rupture of an aneurysm of the intra-pericardial portion of the aorta 105
Cranium, obstruction to passage of blood through the veins of, etc. and resulting disease - 28
„ fracture of - - 59
„ syphilitic disease of, and red softening of the brain therefrom 8
„ cartilaginous tumour of - 250
Cricoïd cartilage, ossification of 68
Crisp (Dr.) Plugging of the superior longitudinal sinus and cerebral veins, with paralysis and loss of speech - - - 117
„ the ulceration of the appendix vermiformis - - 151
„ specimens of coagulation of the blood in the lower animals 337
Croup, case of, in which the false membrane extended from the fauces to the minute bronchial tubes - - - 69
Curling (Mr. T. B.) scirrhous and colloïd disease, causing complete obstruction of the rectum, for which the colon was opened in the left loin - - 157
„ encephaloïd cancer of the testicle 205
„ Lobular fibrous tumour of the scrotum - - - 245
Cyanosis, in a case of aneurysm of the right subclavian artery 103
„ in case of malformation of the heart - - - 89
„ case of reöpening of the foramen ovale, as bearing upon the cause of - - - 109
Cysts, etc. - - 237-259
Cyst of the broad ligament - 189
„ ovarian, removed successfully 187
„ — which had contained seventy-two pints of fluid - - 189
Cysts, ovarian, *continued.*
„ — two, ruptured spontaneously 196
„ — containing hair, epithelial cells and fat - - 201
„ — piliferous, liquid fat from 204
Cystic disease, of the liver and kidneys - - - 174
„ — of the spleen - - 263

Death, sudden, in an infant, from disease of the pulmonary valves 112
Deformities, remarkable in a fœtus 304
Deformity of a boy, born without legs, and with each arm only two inches in length - 308
Degeneration, syphilitic fibroïd, of the testis - - - 210
Diathesis, on malformations of teeth, as indicative of - - 287
Digestive Organs, diseases, &c., of - - 128-187
„ — 1. Pharynx, œsophagus, stomach, and intestines - 128
„ — 2. Liver and its appendages 173
Dilatation, extensive, of the œsophagus - - - 140
„ abscess-like, of the calices of the kidney - - - 209
Diphtheria, cases of - 311-34
„ microscopic drawings of deposit in - - - 311
„ false membrane, covering tonsils, epiglottis, larynx, and trachea - - - 313
„ tongue, tonsils, pharynx, etc., of a child who died of - 314
„ membranous cast of trachea and bronchi expectorated in case of 320
„ fauces, larynx, and trachea of an animal inoculated with - 315
„ on the morbid anatomy of 321
„ — specimens illustrating ditto 316
„ appearance of kidney in case of 319
„ condition of lungs, heart, and kidneys in - 324-5
„ case of, with fatty degeneration of the heart, etc. - - 326
„ — with lobular pneumonia, etc. 331

DIPHTHERIA, *continued.*
„ — with extension of disease along the œsophagus - 333
DISEASES, etc. of the nervous system - - 1-60
„ of the organs of respiration 60-70
„ of the organs of circulation 71-128
„ of the digestive organs 128-187
„ — 1. Pharynx, œsophagus, stomach, and intestines - 128
„ — 2. Liver and its appendages 173
„ of the genito-urinary organs 187-211
„ of the osseous system - 211-236
„ of the organs of special sense 236-237
„ tumours, cysts, including hydatids, etc. - - 237-259
„ ductless glands. 1. The spleen 259-264
„ — 2. Supra-renal capsules 264-278
„ miscellaneous specimens 279-334
„ specimens from the lower animals - - 334-348
Dislocation of the astragalus - 224
„ of the os-hyoïdes - - 66
„ of the spine, in the dorsi-lumbar region - - - 219
„ of the head of the right femur, into the obturator fossa - 211
Diverticulum, ulceration of a false, and resulting communication between the sigmoïd flexure and the bladder - - 131
Dura mater, fibrous tumour of the ——— 10
Dysphagia, in a case of disease of sphenoïd bone, etc. - 224
Dyspnœa, death from, occasioned by destruction of the left recurrent nerve (in case of cancerous tumour of trachea, etc.) - 62

Ear, malleus of the, fracture of the handle of - - 236
Elbow, recurrent fibroïd tumour at the bend of - - 258
Elbow-joint, excision of, in case of extensive disease of the articulation - - - 223
Emphysema of the lungs - 4
Encephaloïd cancer of the kidney 188
Encephaloïd cancer, *continued.*
„ — of the testicle - - 205
„ disease of the liver, primary 173
„ tumour attached to the cerebellum of a child - - 26
Enteritis, case of - - 148
Epilepsy, fatal, from superficial cerebral hæmorrhagic effusions 11
„ with hemiplegia, atrophy of the brain, etc. - - 38
Epithelial cancer in the cicatrix of a burn on the arm - 253
„ — of the œsophagus opening into the trachea - - 130
„ of one supra-renal capsule, and of the tongue - - 272
Epithelial cells, contained in an ovarian cyst - - 201
Epithelial growth upon the chordæ vocales - - - 311
Epithelioma of the larynx - 63
„ ulceration from, followed by fracture of the bones of the leg 234
Erectile tumour of the leg - 243
Excision of the elbow-joint, in case of extensive disease of the articulation - - - 223
„ of the knee-joint, amputation of the right leg, two years after 220
„ of the right knee-joint, on account of deformity from old-standing disease - - 231
„ of the left knee-joint, on account of accident, and resulting false joint - - - 232
Expectoration of rings, cicatrization and contraction of trachea and bronchi after - - 60
Eyelid, ptosis of the upper - 224

Face, fatal phagdæna of, produced by arterial obstruction - 101
„ cartilaginous tumour of - 250
Fat, contained in an ovarian cyst 201
„ liquid, from a piliferous ovarian cyst - - - 204
Fatty and atrophied kidney - 199
Femur, secondary cancer of, followed by spontaneous fracture 235
„ dislocation of the head of the right into the obturator fossa, in a man deformed from rickets 211

Femur, *continued.*
„ fibro-plastic and myeloïd tumour of the - - - 246
Fever, typhoïd, case of, with copious eruption of rose-coloured papules - - - 283
Fibrinous casts of the bronchial tubes - - - 65
„ concretion, detachment and impaction of, in the pulmonary artery - - - 114
Fibro-plastic tumour of the femur 246
Fibroïd disease of the stomach, malignant - - - 146
„ tumour, melanotic recurrent 255
„ — recurrent, at the bend of the elbow - - - 258
Fibrous tumour of the dura mater 10
„ — of the ovary - - 199
„ — of the uterus - 194-202
„ — lobular, of the scrotum- 245
Fibula, myeloïd tumour of the 244
Fingers, club-shaped condition of, in a case of aneurysm of the right sub-clavian artery - 103
Fistula, vesico-vaginal - 202
Flat-foot, dissection of a specimen of - - - 307
Flower (Mr. W. H.), acute periostitis of the tibia, with necrosis of the entire shaft of the bone, following strumous disease of the ankle-joint - - 214
„ epithelial cancer occurring in the cicatrix of a burn on the arm - - - 253
„ colloïd cancer from the calf of the leg - - - 256
Fœtal bones, retention of, in a uterus affected with cancer 210
Fœtus, with remarkable deformities and malformation - 304
Food passed from œsophagus into trachea, and rejected by coughing (in case of cancer of œsophagus) - - 145
Foramen ovale, reöpening of the 108
Fracture of the cranium and of the sixth cervical vertebra - 59
„ of the handle of the malleus of the ear - - - 236
„ spontaneous, following secondary cancer of femur - 235
Fracture, *continued.*
„ of both bones of the leg, following ulceration from epithelioma 234

Gall-bladder, total atrophy of the 177
„ rupture of the, and death from hæmorrhage - - 177
„ filled with pus and a calculus, in a case of cancerous tubercle of the liver, etc. - - 179
Gall-ducts, dilatation of, in connection with tubercles in the liver - - - 182
Gall-stone impacted in the common duct of the liver - - 177
„ case of fatal destruction of the small intestines by - 184
Gastric juice, destruction of the posterior wall of the stomach of an infant by the - 172
Gay (Mr. John), abscess in the pons Varolii - - 14
„ fatal obstruction, from twisting of the meso-colon - 153
Generation, Organs of, diseases, etc., of - 187-211
Gibb (Dr.), hydrarthrosis of the left thyro-hyoïd articulation and dislocation of the os-hyoïdes - - 66
„ complete ossification of the thyroïd and cricoïd cartilages 68
„ cancerous tubercle of the liver and stomach, gall-bladder filled with pus and a calculus; ascites; enlarged liver - - 179
Glands, ductless, diseases of 259-278
Glands, lymphatic, enlargement of 259
„ — hypertrophied, removed from the axillary space - 248
Gout, in case of aneurysm of the cerebellum, etc. - 4
Greenhow (Dr. E. H.), *per Mr. Simon*, diseased supra-renal capsules—extensive discoloration of the skin - 269

Hæmorrhage, death from, in a case of aneurysm of the right subclavian artery - - 103
„ — in case of rupture of the gall-bladder - - 177

Hæmorrhage, *continued.*
„ internal, in case of diphtheria 326
„ cerebral, fatal epilepsy from 11
Hair, contained in an ovarian cyst 201
Hand, right, malformed, of a woman - - - 306
HARE (Dr.), tubercles in the liver, in connection with the question of so-called "dilatation of the gall-ducts," occurring in some cases of general tuberculosis 182
„ case of a boy, aged five years and a-half, born without legs, and with each arm only about two inches in length - 308
Hare-lip, two puppies with - 338
HARLEY (Dr.), bronzed skin; supra-renal capsules healthy - 264
„ fauces, larynx, and trachea of an animal inoculated with diphtheritic exudation - 315
HAVILAND (Mr. ALFRED), *per Dr. Quain*, obliteration of a ureter; abscess-like dilatation of the calices of the kidney - 209
HAWKINS (Mr. CHARLES), communication between the bladder and the sigmoid flexure of the colon - - 208
HEARNE (Mr. E.), *per Mr. H. Thompson*, large cavity in the head of the tibia—not that of an abscess—query, hydatid? 233
Heart, ruptured aneurysm of the 111
„ fatty degeneration of - 326
„ malformation of - 90
„ — congenital - - 110
„ — with cyanosis - 89
„ right ventricle of, hydatid tumour in apex of - - 80
HEATH (Mr. CHRISTOPHER), fibrous tumour of the dura mater 10
„ aneurysm of the innominate artery - - 106
„ epithelial cancer of the œsophagus opening into the trachea 130
„ sac of a strangulated umbilical hernia, with adherent omentum, successfully removed - 131
„ fatty and atrophied kidney 199
„ fœtus presenting several remarkable deformities and malformations - - 304
HEATH, *continued.*
„ two puppies with hare-lip 338
Hemiplegia on the left side, with spasmodic action, and chilliness of paralyzed limbs - 38
Hernia, right inguinal, developed in childhood, and its reduction 128
„ — the sac containing the appendix vermiformis - 170
„ incarcerated, complicated with stricture, in case of colloid cancer of the sigmoid flexure 136
„ strangulated umbilical, sac of, with adherent omentum, successfully removed - 131
HEWITT (Dr. GRAILY), disease of the pulmonary valves in an infant—sudden death - 112
„ *report* on Mr. Obré's case of stricture of the œsophagus 144
Hill (Dr.), description of a large fibrous tumour of the uterus 194
HILLIER (Dr.) encephaloid tumour attached to the cerebellum of a child - - 26
„ congenital malformation of the heart—perforation of the septum ventriculorum, establishing a communication between the left ventricle and the right auricle - - 110
HILLMAN (Mr.), mass of hypertrophied lymphatic glands, removed from the axillary space 248
Hip-joint, disease of, of fifty years' duration - - 230
HOLMES (Mr. T.), kidney containing numerous and unusually large calculi - 197
„ vesico-vaginal fistula - 202
„ disease of the knee-joint supposed to be strumous - 217
„ dislocation of the spine in the dorsi-lumbar region - 219
„ malignant tumour of the humerus - - - 249
„ cartilaginous tumour of the skull and face - - 250
Humerus, malignant tumour of 249
„ myeloid disease of - 247

HUTCHINSON (Mr. Jonathan) report on malformations of the teeth, as indicative of diathesis 287
HYDATIDS, etc. - 237-259
Hydatid, case of, in the brain - 6
„ beneath the fascia of the biceps femoris removed entire - 243
Hydatid cavity, supposed, in the head of the tibia - - 233
Hydatid tumour in the apex of the right ventricle of the heart 80
„ — of the omentum, accompanied by nine small hydatid tumours 132
Hydrarthrosis of the left thyro-hyoïd articulation - 66
Hyoïd-bone, dislocation of - 66
Hypertrophy of the nails, in a case of aneurysm of the right subclavian artery - - 103

Idiotcy, with hemiplegia, atrophy of the brain, etc. - - 38
Idiotic boy, brain of, its weight, dimensions, etc. - - 15
Ileum, portion of, discharged by stool in a case of intus-susception - - - 160
„ stricture of the, with accumulation of plum-stones above the stricture - - - 154
Inter-maxillary bones, necrosis of 216
Intestine, perforation by ulceration of the walls of, in case of inguinal hernia - - 128
„ large, invagination of, in an infant - - - 171
„ small, case of fatal obstruction of, by a gall-stone - 184
„ — perforating ulcer of, in typhoïd fever - - 134
Intus-susception—portions of ileum, cæcum, and colon discharged by stool in a case of—recovery 160
Invagination of the large intestine in an infant - - 171

Jejunum, wound of, from a pistol-shot - - - 168
JOHNSON (Dr. George), Aneurysm of the aorta, with a peculiar condition of the liver - 99
JOHNSON, *continued.*
„ *report* on the appearance of the kidney in Mr. Simon's case of diphtheria - - 319
JOINTS, see *ankle, elbow, hip, knee.*
JONES (Dr. Sydney), cicatrization and contraction of the trachea and bronchi after expectoration of rings - - - 60
„ specimen of wound of the lung extending to its roots - 61
„ communication between the sigmoïd flexure and the bladder, the result of ulceration of a false diverticulum - 131
„ Fibro-plastic and myeloïd tumour of the femur - 246
„ Sequel to a case of myeloïd disease of the humerus (in vol. 7, p. 351) - - 247

KENNION (Dr.), *per Dr. John W. Ogle*, mass of substance, of uncertain character, passed by the vagina - - - 192
„ — *report* on, by Dr. Priestley and Dr. J. W. Ogle - 192
„ — Sequel - - - 193
Kidney, case of single unsymmetrical - - - 190
Kidneys, disease of - - 4
„ abscess in the right lumbar region, attached to - 190
„ containing numerous and large calculi - - - 197
„ encephaloïd cancer of the - 188
„ fatty and atrophied - 199
„ appearance of, in a case of diphtheria - - - 319
„ calices of the, abscess-like dilatation of - - - 209
„ and liver, association of cystic disease of - - 174
„ of a parrot, calcareous infiltration of - - - 338
Knee-joint, old disease of, repaired 229
„ supposed strumous disease of 217
„ excision of, and amputation of the right leg two years after 220
„ right, excision of - - 231
„ left, excision of, on account of accident, and resulting false joint - - - 232

Laryngeal nerves, modifications of voice, from paralysis of by pressure - - - 339
Larynx, epithelioma of - 63
„ of a "roarer" (horse), atrophy of the muscles of - - 339
LEARED (Dr.), gall-stone impacted in the common duct of the liver; rupture of the gall-bladder and death from hæmorrhage - - 177
LEE (Mr. Henry), case of red softening of the central portions of the brain, produced by syphilitic disease of the bones of the cranium - - 8
Leg, erectile tumour of the - 243
„ right, removed by amputation, two years after excision of the knee-joint - - 220
Legs, case of a boy born without 308
LIVER and its appendages, diseases of - - - 173
Liver, peculiar condition of, in case of aneurysm of the aorta - 99
„ cancerous tubercle of - 179
„ enlarged, in a case of cancerous tubercle of ditto - 179
„ colloïd disease of - - 178
„ primary encephaloïd disease of 173
„ gall-stone impacted in the common duct of - - 177
„ syphilitic disease of - 21
„ tubercles in, in connection with "dilatation of the gall-ducts," in cases of tuberculosis - 182
„ and kidneys, association of cystic disease of - - 174
Lungs—atelektasis pulmonum 61
„ emphysema of the - - 4
„ tubercle of the - - 284
„ wound of the, extending to its roots - - - - 61
„ valves of, malformation of 79
Lymphatic glands, enlargement of 259
„ hypertrophied, removed from the axillary space - - 248

Malformation of the right hand of a woman - - - 306
„ of the heart, the pulmonary artery impervious at its origin 90
Malformation of the heart, *continued.*
„ — congenital - - 110
„ — with cyanosis - - 89
„ of the pulmonary valves - 79
„ of the left lower extremity 305
„ of a boy born without legs, and with arms only two inches in length 308
Malformations, remarkable, in a fœtus - - - 304
Malleus of the ear, fracture of the handle of - - 236
MARKHAM (Dr.), stricture of the pylorus, resulting from the destructive action of Burnet's disinfecting fluid - - 164
„ *report* on Dr. Baly's case of ulceration of the œsophagus 167
„ diseased supra-renal capsules—pericarditis — no discoloration of the skin - - 268
Mass of uncertain substance, passed by the vagina - - 192
Mediastinum, cancerous tumour of 240
Melanotic tumour recurrent fibroïd 255
„ — subcutaneous malignant 257
Membrane, false, from the fauces to the minute bronchial tubes (in case of croup) - - 69
„ — in case of diphtheria - 313
Mercury, exhibition of in infancy, as a cause of dental malformations - - 290
Mitral valve, vegetations on the 51-53
MURCHISON (Dr.), *report* on Mr. Spencer Wells's case of communication between the aorta and the left bronchus - 71
„ two specimens of perforating ulcer of the small intestine in typhoïd fever - - 134
„ case of single unsymmetrical kidney - - 190
„ cancerous tumour of the mediastinum, involving and obstructing the superior vena cava 240
„ case of typhoïd fever, with copious eruption of rose-coloured papules - - 283
„ membranous cast of trachea and bronchi expectorated by a patient labouring under diphtheria - - 320

MURCHISON, *continued.*
„ intestines of a pig, for six weeks before death fed with "typhoïd dejections" - - 334
„ see SCURRAH.
Myeloïd disease of the humerus 247
Myeloïd tumour of the femur 246
„ — of the fibula, with secondary growths in the lungs - 244
„ of the tibia - - 237

Necrosis of the inter-maxillary bones 216
„ in case of acute periostitis of the tibia - - 214
NERVOUS SYSTEM, diseases, etc., of 1-60
Neuroma, case of - - 1
NUNN (Mr. T. W.), uterus unicornis 200
„ two specimens of ovarian disease 207
Nutrition, mal-, in infancy as a cause of dental malformation 289

Obliteration of the thoracic aorta 97
„ of an ureter - - 209
OBBE (Mr. HENRY), atelektasis pulmonum - - 61
„ stricture of the œsophagus 144
„ — *report* on, by Dr. Grailly Hewitt, Mr. Sibley, and Mr. J. Wood - - 144
„ abscess in the right lumbar region, attached to the kidney—ulceration of the bladder 190
Obstruction of cerebral arteries 21
„ — seven cases of - 44
„ of the right middle cerebral 51, 53
„ of the internal carotid arteries 50
„ of the left internal carotid 56
„ fatal, from twisting of the mesocolon - - 153
Obturator fossa, dislocation of the head of the right femur into 211
Œsophagus, cancer of the, causing a large opening into the trachea 145
„ cancerous tumour of - 62
„ carcinomatous stricture of the 142
„ carcinoma of - - 159

Œsophagus, *continued.*
„ epithelial cancer of, opening into the trachea - - 130
„ extensive dilatation of - 140
„ stricture of the - - 144
„ softening of the lower part of, in a parrot - - 338
„ ulceration of, near its lower extremity, preventing the passage of food - - 165
„ death from accumulation of blood round, in case of aneurysm of abdominal aorta - 84
OGLE (Dr. JOHN W.), cases illustrating disease of the central and other parts of the brain, as a result of obstruction to the passage of blood through the veins and sinuses of the cranium 28
„ epilepsy, idiotcy, hemiplegia on the left side, atrophy of the right and left hemispheres of the brain, etc. - - 38
„ enormous aneurysm of the right subclavian artery — peculiar cyanosis and club-shaped condition of the fingers, etc. - 103
„ disease of the upper surface of the sphenoïd bone—ptosis of the upper eyelid—dysphagia—loss of muscular power in the arms—death by apnœa - 224
„ *tables* showing cases of disease of the supra-renal capsules, accompanied or unaccompanied by bronzed skin - 275
„ drawing showing atrophy of the muscles on one side of the larynx of a "roarer" (horse), etc. - - - 339
„ see KENNION.
Omentum, adherent to sac of umbilical hernia, successfully removed - - - 131
„ hydatid tumour of - - 132
ORD (Mr. W. M.), see BRISTOWE (Dr.)
ORGANS OF SPECIAL SENSE, diseases, etc., of - 236-237
OSSEOUS SYSTEM, diseases, etc., of 211-236
Ossification of the thyroïd and cricoïd cartilages - - 68
Ovarian disease, two specimens of 207

Ovarian cyst removed successfully 187
„ — which had contained seventy-two pints of fluid - - 189
„ — two, ruptured spontaneously 196
„ — containing hair, epithelial cells and fat - - 201
„ — liquid fat from a piliferous 204
„ tumour, pseudo-colloïd successfully removed - - 197
„ — pseudo - colloïd, removed during life, by ovariotomy 200
„ — fibrous - - - 199
Ovariotomy, in a case of pseudo-colloïd ovarian tumour - 200

Paralysis in case of plugging of the cerebral veins - - 117
Parrot, calcareous infiltration of the kidneys of a - - 338
Peacock (Dr.), brain of an idiot boy nearly eleven years of age 15
„ note in reference to the specimen of casts of the bronchial tubes figured in Plate III., Figs. 3 and 4 of the IXth volume of the "Transactions," (p. 53) - - - 65
„ rupture of the aortic valves by violence - - - 92
„ contraction of the pulmonary artery from fusion of the valves 107
„ reöpening of the foramen ovale 108
„ carcinomatous stricture of the œsophagus - - 142
„ ulcer of the stomach - 143
„ microscopic drawings of the deposit in a case of aphthous exudation and in one of diphtheria - - - 311
„ and Dr. Bristowe, stricture of the ileum, with accumulation of plum-stones above the seat of stricture — malarious symptoms - - - 154
Perforation of the septum ventriculorum - - - 110
Pericarditis, in case of diseased supra-renal capsules - 268
Periostitis, acute, of the tibia, with necrosis, following strumous disease of the ankle-joint 214
Peritonitis, acute, death from, in case of inguinal hernia - 128
Phagedæna of the face, fatal, produced by arterial obstruction 101
Pharynx of a child affected with scarlatinous membranous angina - - - 139
Pig, fed with typhoïd dejections, intestines of - - 334
Plugging of the superior longitudinal sinus and cerebral veins, with paralysis and loss of speech 117
Plum-stones, accumulation of, in case of stricture of the ileum 154
Poisoning, suicidal, by aconite 285
Pollock (Dr.), aneurysm of the arch of the aorta 73, 76
Pons Varolii, abscess in the - 14
Price (Mr.), right lower limb removed by amputation through the thigh, two years and three months after excision of the knee-joint - - 220
„ portions of bones, forming the right elbow-joint, removed by the operation of excision, on account of extensive disease of the articulation - - 223
„ right knee-joint removed by excision on account of deformity from old-standing disease 231
„ see Canton.
Priestley (Dr. W. O.), *report* on Dr. Kennion's case of a mass passed by the vagina - 192
Ptosis of the upper eyelid - 224
Pulmonary artery, impervious at its origin - - - 90
Pulmonary valves, malformation of 79
„ — disease of in an infant — sudden death - - 112
Puppies, two, with hare-lip - 338
Pylorus, stricture of the, from the destructive action of Burnet's disinfecting fluid - - 164

Quain (Dr.), portions of the ileum, cæcum, and colon discharged by stool in a case of intussusception—recovery - 160
„ large fibrous tumour of the uterus 194

QUAIN, *continued.*
„ see HAVILAND.

Rectum, obstruction of, from scirrhous and colloïd disease - 157
RESPIRATION, ORGANS OF, diseases, etc., of - 60-70
Rupture of the aortic valves by violence - - 92
„ of the gall-bladder, and death from hæmorrhage - 177

SANDERSON (Dr. J. B.), malformation of the heart, with cyanosis 89
„ pharynx of a child, aged two years and a-half, affected with scarlatinous membranous angina . - - 139
„ suicidal poisoning by aconite 285
Scarlatinous membranous angina, pharynx of a child affected with 139
Scirrhous and colloïd disease causing complete obstruction of the the rectum, for which the colon was opened in the left loin 157
Scrotum, lobular fibrous tumour of 245
SCURRAH (Dr.), *per Dr. Murchison*, ulceration of the internal jugular vein - - 99
„ *per Dr. Murchison*, extensive deposit of tubercle in the supra-renal bodies; no discoloration of the skin - - 268
SEMPLE (Dr.), false membrane, covering the tonsils and the epiglottis, and lining the larynx and trachea in a case of diphtheria - - 313
„ part of the tongue, the tonsils, pharynx, œsophagus, epiglottis, larynx, and trachea of a child who died of diphtheria 314
SENSE, ORGANS OF SPECIAL, diseases, etc., of - 236-237
SHAW (Mr. A.), wounds of the stomach, jejunum, and abdominal aorta, from a pistol-shot 168
„ dislocation of the head of the right femur into the obturator fossa, in a man deformed from rickets - - 211
SHILLITOE (Mr. B.), recurrent fibroïd tumour at the bend of the elbow, for which the arm was removed - - 258
SIBLEY (Mr. S. W.), tubercular disease of the supra-renal bodies; bronzed skin - 266
„ epithelial cancer of one of the supra-renal capsules, with similar disease of the tongue; no discoloration of the skin - 272
„ *report* on Mr. Obre's case of stricture of the œsophagus 144
SIBSON (Dr.), *report* on Mr. Spencer Wells's case of communication between the aorta and the left bronchus - - 71
Sigmoïd flexure of the colon, colloïd cancer of - - 136
„ stricture of the - - 161
„ communication of, with the bladder - - 208
„ communication of, with the bladder, the result of ulceration of a false diverticulum - 131
SIMON (Mr. John), arterial obstruction, producing fatal phagedæna of the face - 101
„ specimens illustrating the morbid anatomy of diphtheria 316
„ — *report* on, by Dr. George Johnson and Dr. Wilks - 319
„ see GREENHOW.
Skin, discoloration of, see *Bronzed Skin.*
„ human, from a long-buried corpse, pyramidal-shaped vegetable growths on - 299
Softening of the brain, round left corpus striatum - 54
„ of the anterior cerebral lobes and right corpus striatum 50
„ of left cerebral hemisphere 49
„ of the brain, red, from syphilitic disease of the bones of the cranium - - 8
„ congestion of the brain without 50
SPECIMENS (MISCELLANEOUS), including malformations, effects of poisons, morbid states, diphtheria, etc. - 279-334
„ FROM THE LOWER ANIMALS 334-347
Sphenoïd bone—disease of the upper surface of - - 224

Spine, dislocation of, in the dorsi-lumbar region - - 219
Spinal cord, softening of, from concussion - - 59
SPLEEN (The), diseases of 259-264
Spleen, enlargement of the - 259
„ cystic disease of - 263
Stomach, cancerous tubercle of 179
„ malignant fibroïd disease of 146
„ ulcers of the - - 143
„ wound of, from a pistol-shot 168
„ of an infant, its posterior wall destroyed by the gastric juice 172
Stomatitis, idiopathic, as a cause of dental malformations - 291
„ of hereditary syphilis, as ditto 291
Stricture of the œsophagus - 144
„ carcinomatous, of the œsophagus - - - 142
„ of the pylorus, resulting from the destructive action of Burnet's disinfecting fluid - 164
„ of the ileum, with accumulation of plum-stones above the stricture - - - 154
„ of the sigmoïd-flexure - 161
„ — from colloïd cancer - 136
Strumous disease of the ankle-joint 214
„ of the knee-joint (supposed) 217
„ of the right testicle, in a child 191
SUPRA-RENAL CAPSULES, diseases of - - - 264-278
Supra-renal capsules, *tables* showing cases of disease of, with and without bronzing of the skin - - - 275-278
„ diseased, with extensive discoloration of the skin - 269
„ disease of, with bronzed skin 273
„ tubercular disease of, with bronzed skin - - 266
„ diseased, no discoloration of the skin - - - 268
„ extensive disease of, with no discoloration of the skin - 271
„ epithelial cancer of one of; no discoloration of the skin - 272
„ deposit of tubercle in, no discoloration of the skin - 268
Supra-renal capsules, *continued.*
„ healthy, in case of bronzed skin 264
Syphilis, hereditary, the stomatitis of, as a cause of dental malformations - 291
Syphilitic disease of the brain 56
„ of the brain and liver - 21
„ of the bones of the cranium and red softening of the brain therefrom - - - 8
Syphilitic fibroïd degeneration of the testis - - - 210

Talipes valgus, dissection of a specimen of - - 307
Teeth, report on malformations of, as indicative of diathesis 287
„ inherited peculiarities of form, etc., in - - - 288
„ malformation of, caused by malnutrition in infancy - 289
„ — caused by the exhibition of mercurials in infancy - 290
„ — caused by stomatitis of hereditary syphilis - - 291
„ — caused by thrush, idiopathic stomatitis, etc. - - 291
Testicle over the external abdominal ring - - - 128
„ encephaloïd cancer of the - 205
„ right, strumous disease of, in a child - - - 191
„ syphilitic fibroïd degeneration of - - - 210
THOMPSON (Mr. Henry), simple stricture of the sigmoïd flexure; constipation relieved by opening the left colon—death from ulceration and perforation above the stricture - 161
„ primary encephaloïd disease of the liver - - . - 173
„ fibrous tumours of the uterus 202
„ spontaneous fracture of both bones of the leg, following extensive ulceration from epithelioma - - - 234
„ tumour of the upper end of the tibia, containing numerous myeloïd bodies - - 237
„ subcutaneous malignant tumours containing melanotic matter 25[illegible]
„ see HEARNE.

Thrush, as a cause of dental malformations - - 291
Thyroïd cartilage, ossification of 68
Thyro-hyoïd articulation, hydrarthrosis of the left - 66
Tibia, acute periostitis of, with necrosis, following strumous disease of the ankle-joint 214
„ large cavity in the head of, query hydatid? - - 233
„ myeloïd tumour of the upper end of - - - 237
Tongue, epithelial cancer of the 272
TOYNBEE (Mr. Joseph), Fracture of the handle of the malleus of the ear - - - 236
Trachea, cancerous tumour in 62
„ epithelial cancer of the œsophagus opening into - 130
„ cicatrization and contraction of, after expectoration of rings 60
Tubercle of the lungs - 284
„ in the liver, in connection with "dilatation of the gall-ducts" in cases of tuberculosis - 182
„ specimens showing coëxistence of with cancer - - 284
„ cancerous, of the liver and stomach - - 179
Tuberculosis, tubercles in the liver, etc., in cases of - 182
TUMOURS, cysts, hydatids, etc. 237-259
Tumour, cancerous, in the groove between the trachea and œsophagus - - 62
„ — of the mediastinum, involving the superior vena cava - 240
„ cartilaginous, of the skull and face - - - 250
„ cholesteatomatous, of the brain 24
„ pseudo-colloïd ovarian, successfully removed - - 197
„ — removed during life, by ovariotomy - - 200
„ encephaloïd, attached to the cerebellum of a child - 26
„ erectile, of the leg - 243
„ fibroïd, melanotic recurrent 255
„ — recurrent, at the bend of the elbow - - 258
„ fibro-plastic, and myeloïd, of the femur - - 246
Tumours, *continued.*
„ fibrous, of the dura mater 10
„ — of the ovary - - 199
„ — of the uterus 194, 202
„ — lobular, of the scrotum 245
„ follicular, of the uterus - 206
„ hydatid, in the apex of the right ventricle of the heart - 80
„ — of the omentum, with nine small hydatid tumours - 132
„ subcutaneous malignant, containing melanotic matter 257
„ malignant, of the humerus 249
„ myeloïd, of the fibula - 244
„ — of the upper end of the tibia 237
Typhoïd fever, case of, with copious eruption of rose-coloured papules - - 283
„ — perforating ulcer of the small intestine in - - 134
„ dejections, intestines of a pig fed with - - 334

Ulceration of the internal jugular vein - - - 99
„ of the œsophagus near its lower extremity, completely preventing the passage of food - 165
„ of the bladder - - 190
„ of the appendix vermiformis 151
„ adhesion and perforation by, of the walls of the intestine at seat of stricture - 128
„ of a false diverticulum, and resulting communication between the sigmoïd flexure and the bladder - - 131
„ and perforation, death from, in case of stricture of the sigmoïd flexure - - 161
„ from epithelioma, and subsequent fracture of the bones of the leg - - 234
Ulcers of the stomach - 143
„ perforating, of the small intestine in typhoïd fever - 134
Ureter, obliteration of an - 209
Urethra, case of double, from a man the subject of obliteration of the aorta - - 201
URINARY ORGANS, diseases, etc., of 187-211
Uterus unicornis - - 200
Uterus, cancer of - - 284

Uterus, *continued.*
„ cancer of, retention of fœtal bones in - - - 210
„ fibrous tumour of 194, 202
„ follicular tumour of - 206

Vagina, mass of uncertain substance passed by - 192
Valve, aortic, rupture of, by violence - - 92
„ — vegetations on the - 53
„ mitral, vegetations on the 51, 53
„ pulmonary, disease of, in an infant—sudden death - 112
„ — fusion of - - 107
„ — malformation of - 79
„ tricuspid, disease of - 114
Veins, cerebral, plugging of, with paralysis and loss of speech 117
„ internal, jugular, ulceration of 99
Vena cava, superior, cancerous tumour of the mediastinum involving - - - 240
Ventricle, right, of the heart, hydatid tumour in apex of - 80
„ left, communication with the right auricle from perforation of the septum - - 110
Ventricles, septum of, perforation of - - - 110
Vertebra, sixth cervical, fracture of 59
Vesico-vaginal fistula - 202
Voice, modifications of, from paralysis of the laryngeal nerves by pressure - - 339

Ward (Mr. N.), epithelioma of the larynx - - - 63
„ dislocation of the astragalus 224
Ward (Dr. Ogier), mammary cancer in a bitch - - 337
„ calcareous infiltration of the kidneys of a parrot, with softening of the lower part of the œsophagus - - 338
Warty growth upon the chordæ vocales - - - 311
Welford (Mr.), *per Dr. Wilks*, case of bronzed skin, with disease of the supra-renal capsules - 273
Wells (Mr. Spencer), communication between the aorta and the left bronchus - 71

Wells, *continued.*
„ — *report* on, by Dr. Sibson, Dr. Murchison, and Mr. Spencer Wells - - 71
„ ovarian cyst removed successfully - - - 187
„ cyst of the broad ligament 189
„ ovarian cyst which had contained seventy-two pints of fluid - - - 189
„ two ovarian cysts, ruptured spontaneously - - 196
„ pseudo-colloïd ovarian tumour, successfully removed - 197
„ fibrous tumour of the ovary 199
„ pseudo-colloïd ovarian tumour removed during life by ovariotomy - - - 200
Wilks (Dr.), case of neuroma 1
„ two cases of cholesteatomatous tumour of the brain - 24
„ constriction of the thoracic aorta - - - 77
„ malformation of the pulmonary valves - - - 79
„ ruptured aneurysm of the heart 111
„ malignant fibroïd disease of the stomach - - 146
„ carcinoma of the œsophagus 159
„ colloïd disease of the liver 178
„ liquid fat from a piliferous ovarian cyst - - - 204
„ syphilitic fibroïd degeneration of the testis - - 210
„ myeloïd tumour of the fibula, with secondary growths in the lungs - - - 244
„ melanotic recurrent fibroïd tumour - - - 255
„ enlargement of the spleen and lymphatic glands - 259
„ cystic disease of the spleen 263
„ see Welford.
„ *report* on the kidney in Mr. Simon's case of diphtheria 319
Wood (Mr. John), injected preparation of a specimen of obliteration of the thoracic aorta 97
„ two specimens of abnormal origin of the right subclavian artery - - - 119
„ specimen of inguinal hernia of the right side—the sac containing the appendix vermiformis - - - 170

WOOD, *continued.*
„ case of total atrophy of the gall-bladder - - - 176
„ case of an ovarian cyst containing hair, epithelial cells, and fat in abundance - - 201
„ case of double urethra, from a full-grown man the subject of obliteration of the aorta - 201
„ case of follicular tumour of the uterus - - - 206
„ wax model and a dissection of the malformed right hand of a woman - - - 306

WOOD, *continued.*
„ case of epithelial or warty growth upon the chordæ vocales - - - 311
„ dissection of a specimen of flat-foot (talipes valgus) in a man of advanced years - 307
„ *report* on Mr. Obré's case of stricture of the œsophagus 144
Wound of the lung extending to its roots - - - 61
„ of the stomach, jejunum and abdominal aorta, from a pistol-shot - - - 168

THE END.

Printed by J. W. ROGERS, 5, Kirby Street, Hatton Garden.

41B
127 +

HOLT
BOSTON